Management of the Facial Hypoplasia

Prof. Dr. Dr. Srinivas Gosla Reddy
MBBS, MDS, FRCS (Edin.), FDSRCS (Edin), FDSRCS (Eng.), FDSRCPS (Glasg.), Phd

Dr. Rajgopal R. Reddy
MBBS, BDS, FDSRCPS (Glasg.)

Prof. Dr. S. B. V. Ramana Reddy
MDS M.OrthoRCS (Lond.) (Glas.)
Dr. Mallikarjun Reddy MDS (Ortho)

Dr. Ashish Fanan M.D.S
Dr. Avni Pandey M.D.S.

GSR Institute of Craniofacial Surgery,
Hyderabad India

www.craniofacialinstitute.org

What is Facial Hypoplasia?

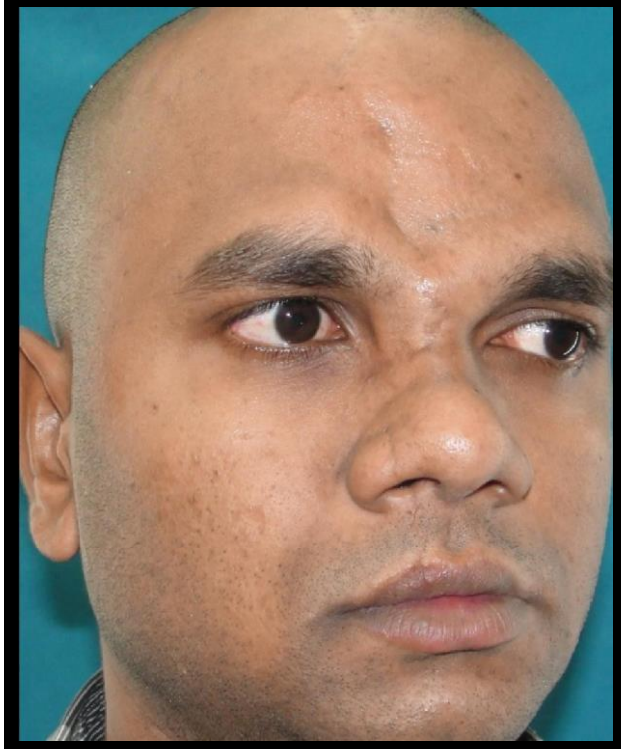

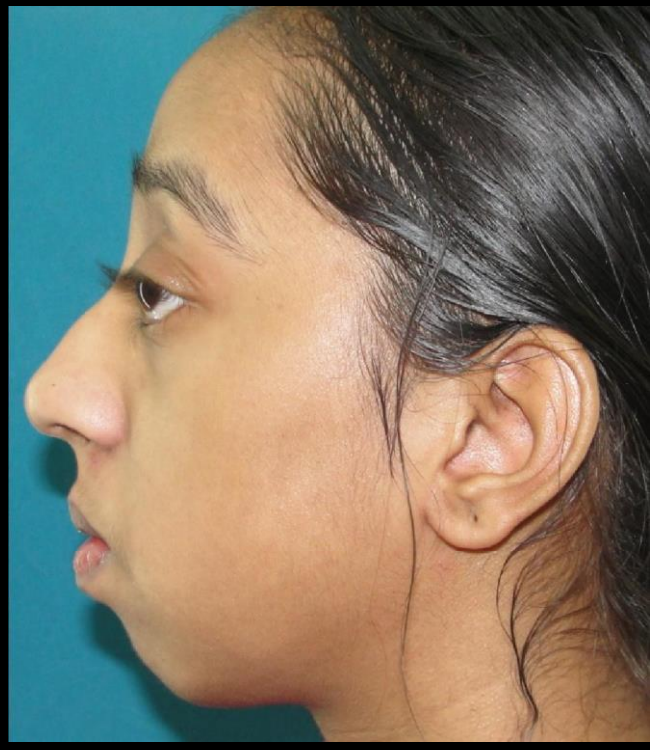

- Any disproportionate growth of a part of the face when compared to the rest of the face
- Usually occurs due to hypoplasia of the facial skeleton

Which part of the facial skeleton is affected?

- Frontal Complex
- Maxillary Complex
- Mandibular Complex
- Naso-orbital Complex
- Ear

How do we manage Facial Hypoplasia?

- By repositioning the affected facial skeleton
- By adding grafts on the affected facial skeleton

Repositioning of Facial Skeleton

- Maxillary Complex
- Mandibular Complex
- Naso-orbital Complex
- Frontal Complex
- Ear

OSTEOTOMY OF THE

MAXILLARY/NASAL COMPLEX

ZYGOMATIC/MALAR COMPLEX

Osteotomy of the Maxillary Complex

LeFort I Osteotomy

LeFort II Osteotomy

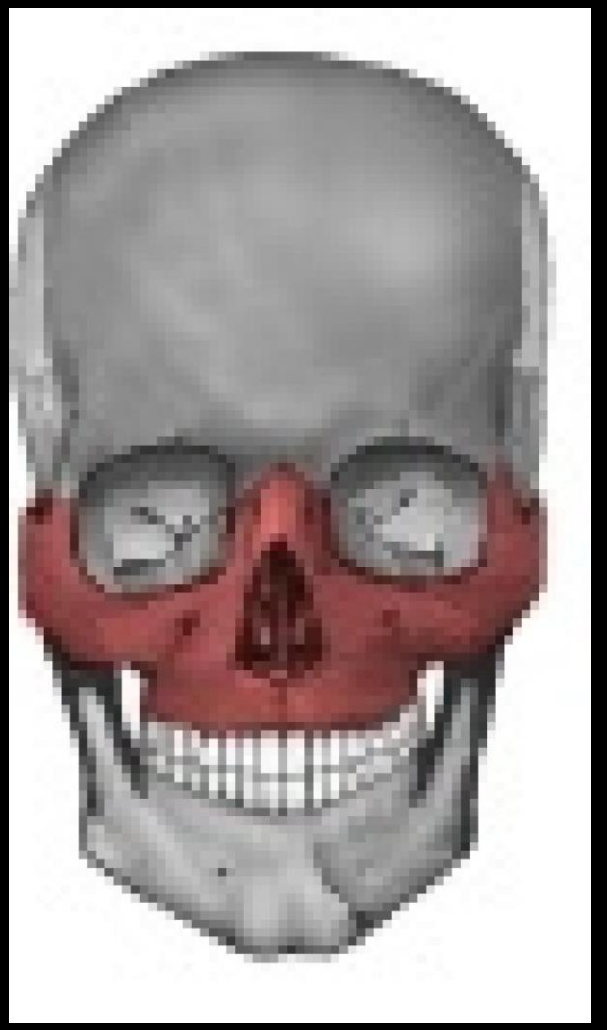

LeFort III Osteotomy

LeFort I osteotomy
Indications

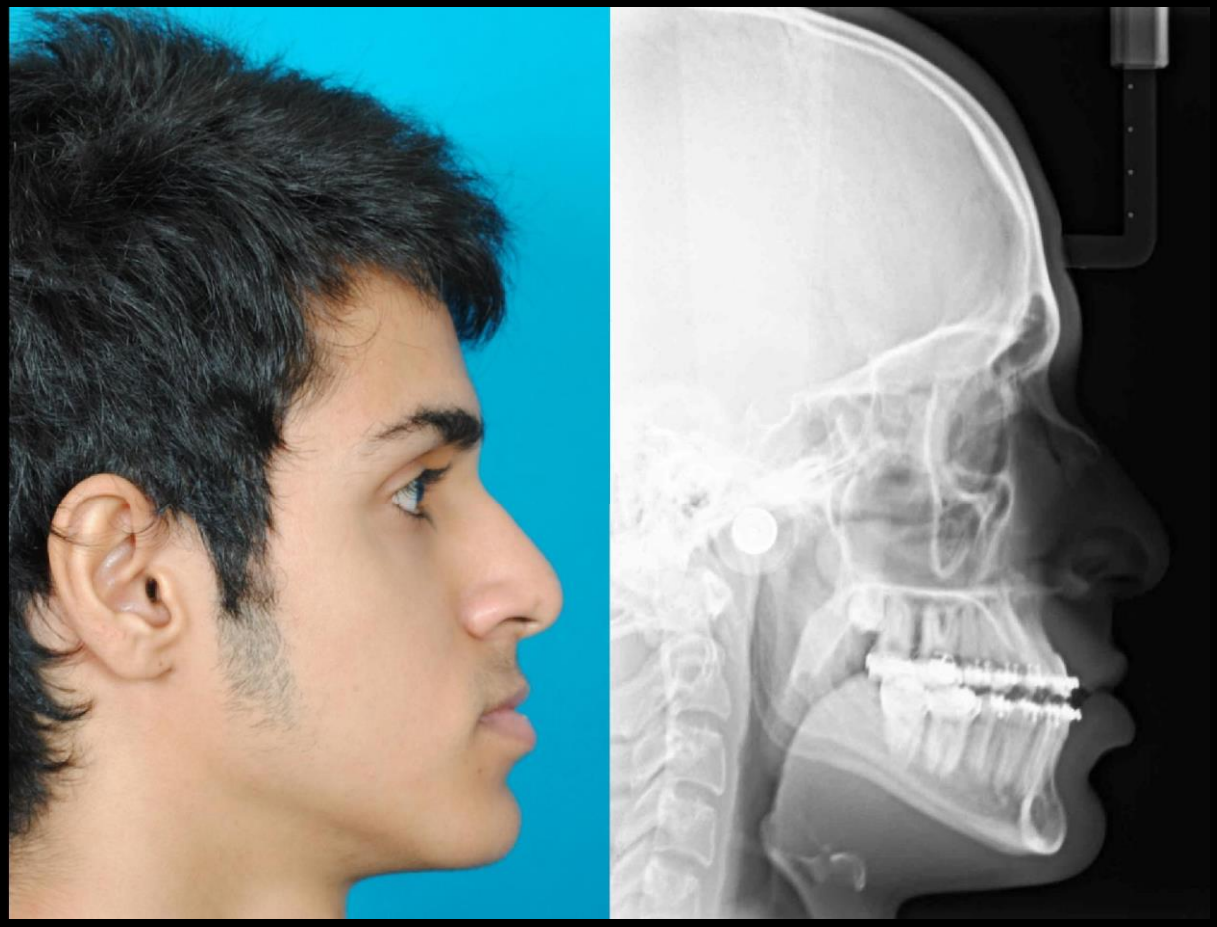

Deficiency of only the Maxillary/Malar Complex

Performing a LeFort I Osteotomy

Incision Design

- In the buccal sulcus about 6mm above the gingival margin.

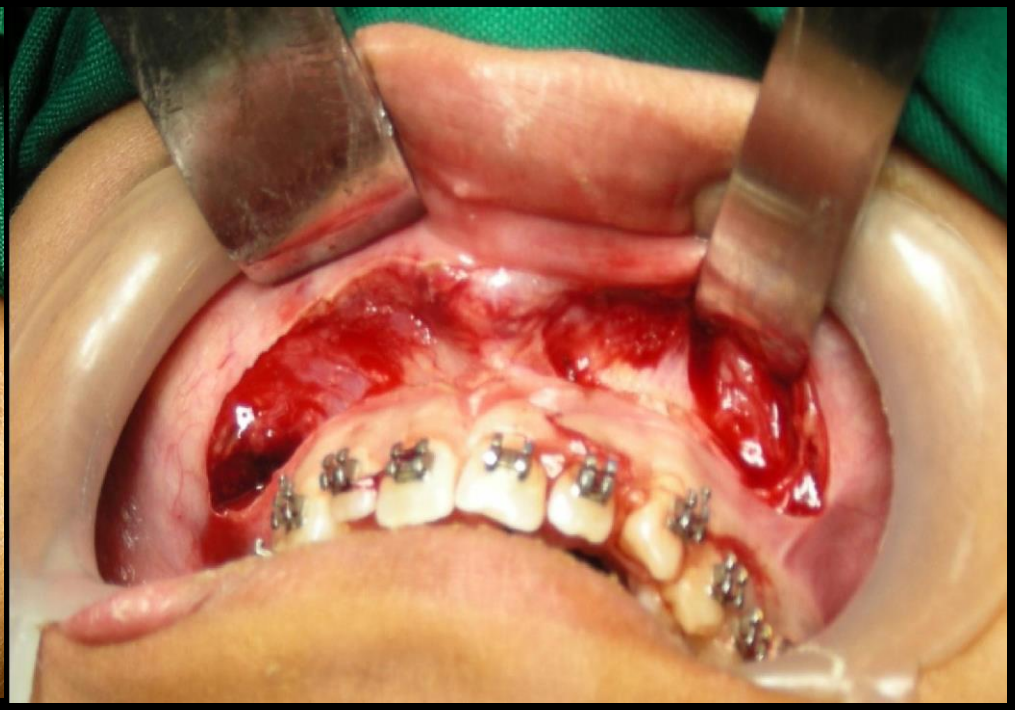

Performing a LeFort I Osteotomy

Subperiosteal dissection

- Expose the lateral aspect of nasal cavity and carefully elevate the nasal mucosa without perforating it.
- Posteriorly, dissect around the tuberosity and tunnel up to the pterygoid.
- Superiorly, expose the anterior maxillary wall, identifying the inferior orbital foramen

Performing a LeFort I Osteotomy

Anterior buccal osteotomy

- Lateral wall of the maxilla is cut with the help of a Reciprocating Saw with copious irrigation.
- The Lateral wall osteotomy can have variations in the design

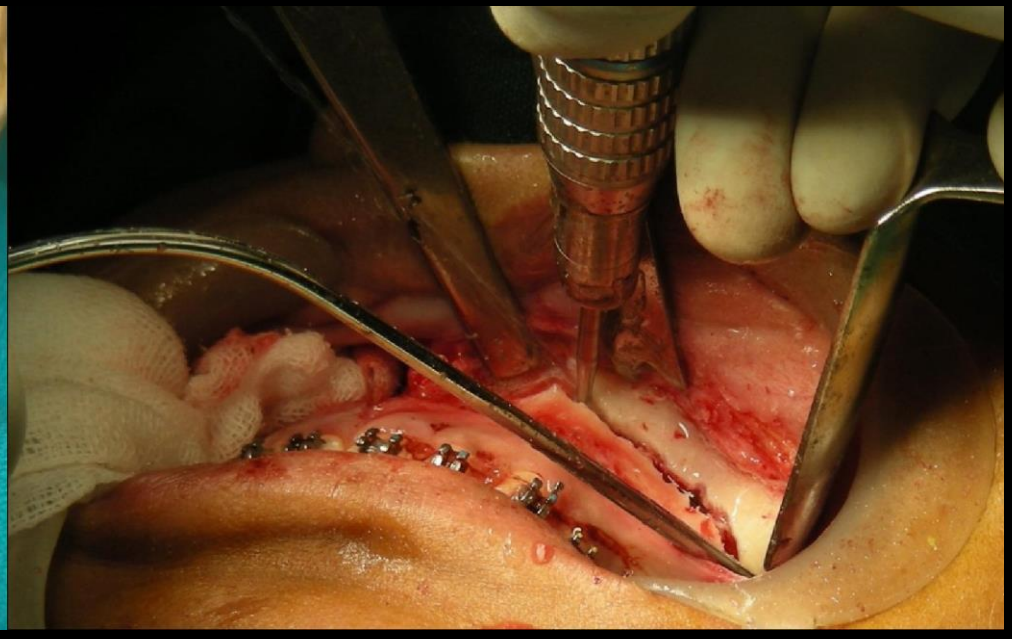

Performing a LeFort I Osteotomy

Medial and posterior wall osteotomy

- A thin guarded osteotome is used to and tap gently and carefully to fracture the medial (lateral nasal wall) and posterior wall of maxilla.

- The nasal mucosa is protected from injury with a periosteal elevator while completing the osteotomy.

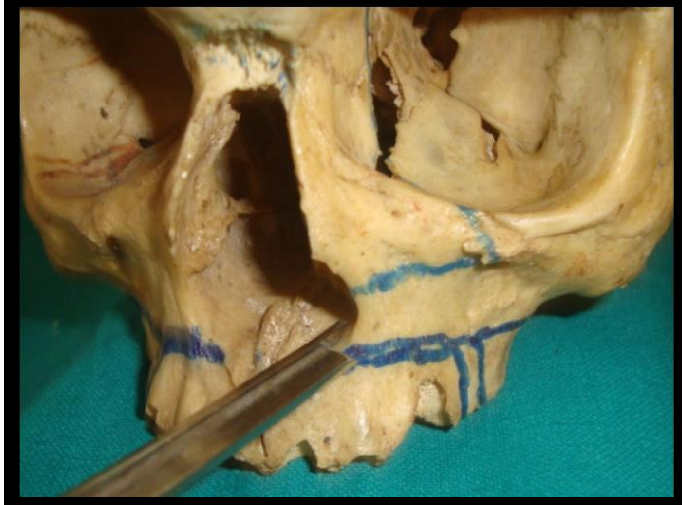

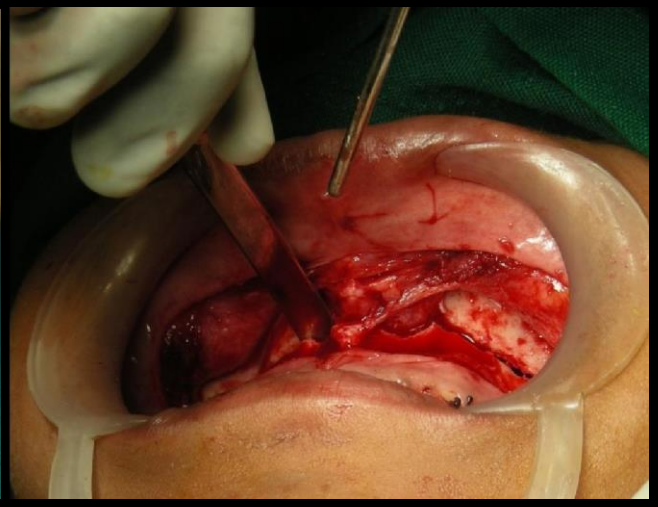

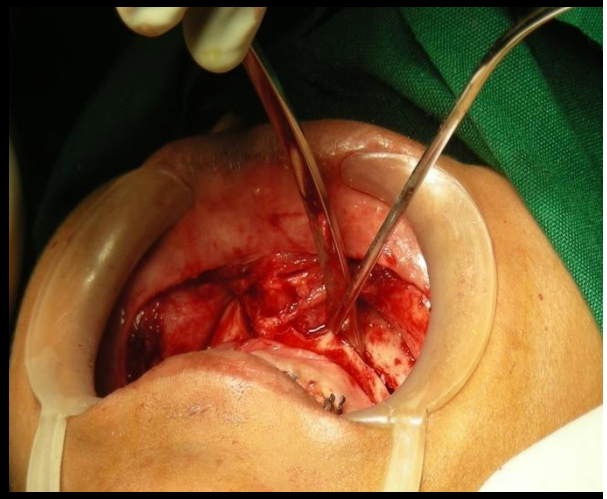

Performing a LeFort I Osteotomy

Pterygomaxillary osteotomy

- The pterygoid plate is separated from the maxilla using a pterygoid osteotome.

•The pterygoid hamulus is felt and palpated with the ball of the index finger to prevent excess in chiseling and damage to the soft tissues.

- Failure to separate the tuberosity from the pterygoid plates will cause difficulty in downfracture or an unfavorable fracture.

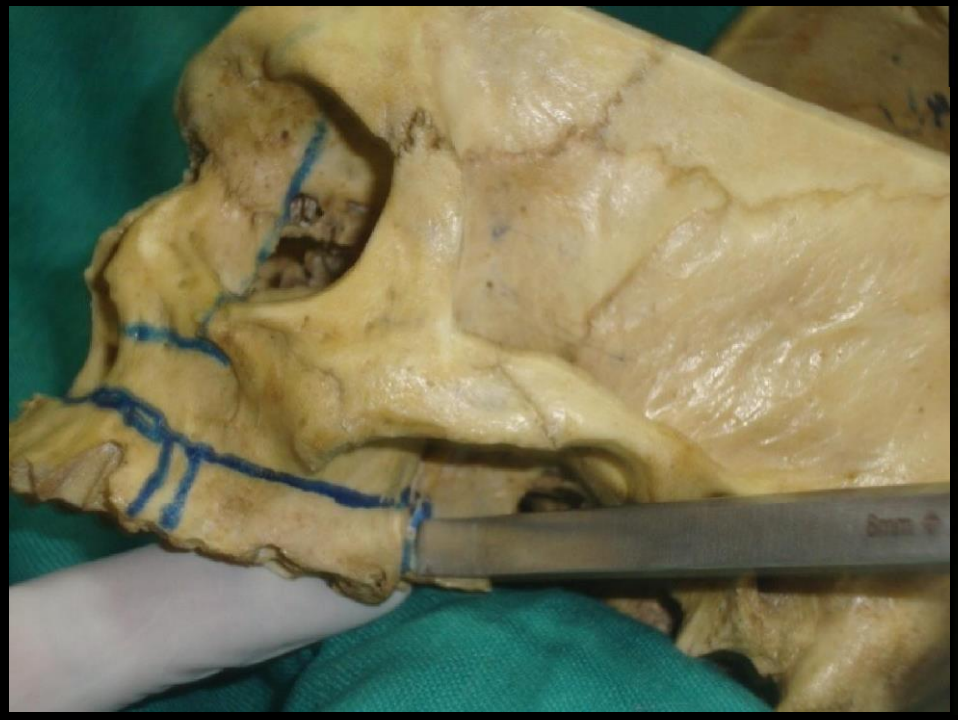

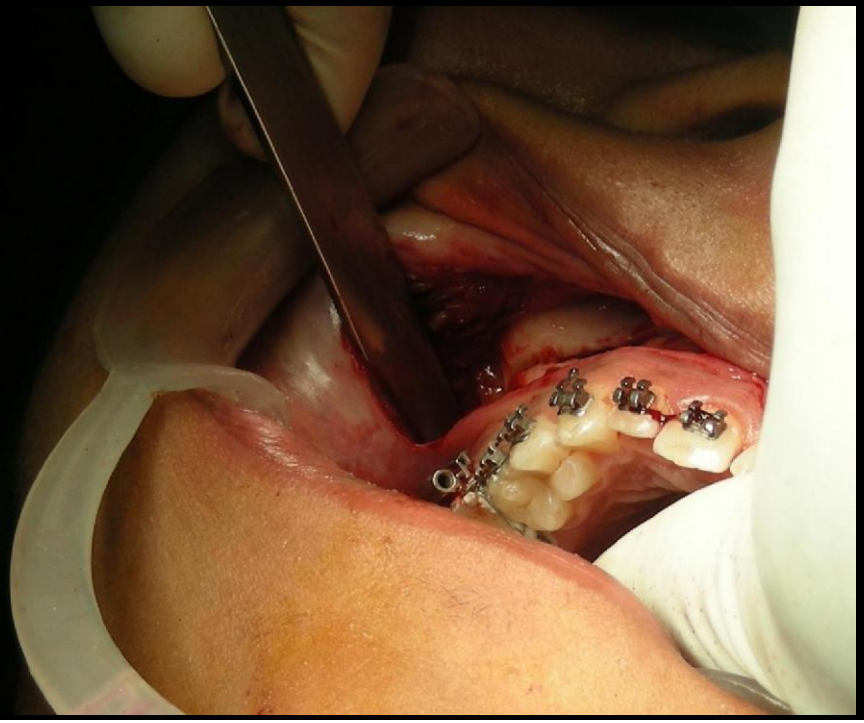

Performing a LeFort I Osteotomy

Nasal septum and vomer osteotomy

- The nasal septum cartilage and vomer is separated from the maxilla using a septal gouge or osteotome.

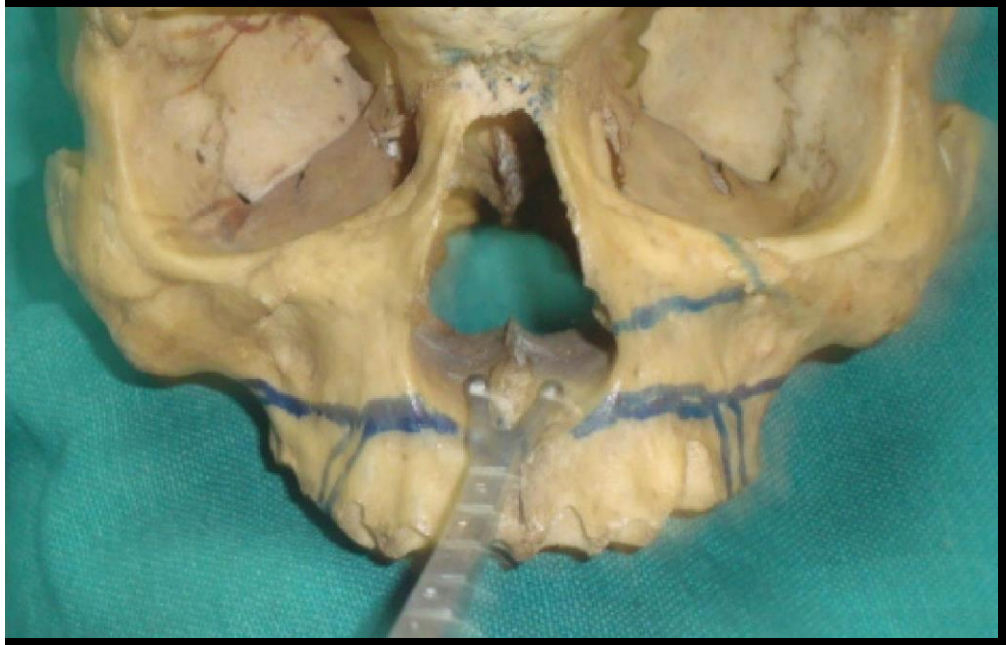

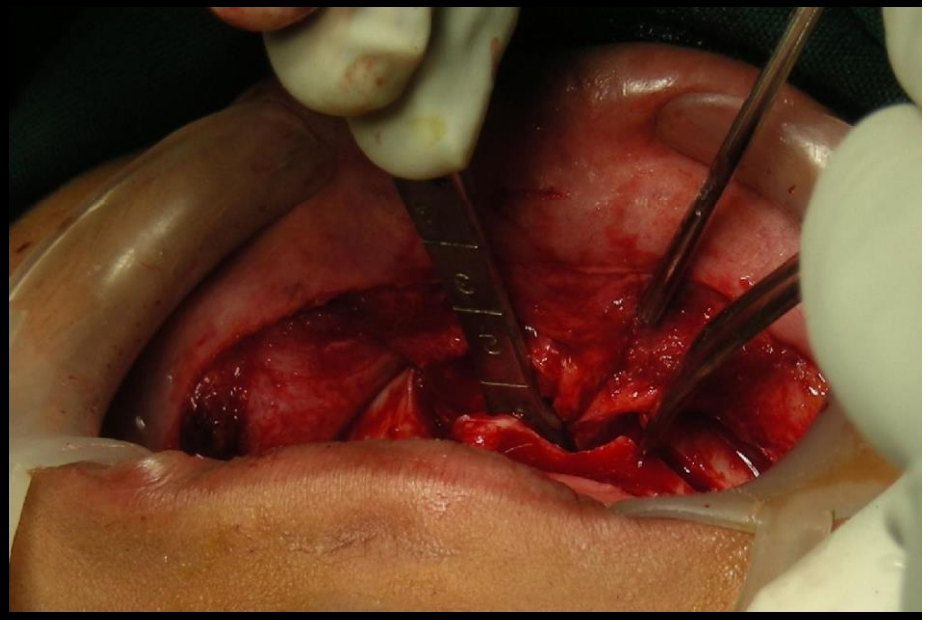

Performing a LeFort I Osteotomy

Maxillary downfracture and mobilization

- By using thumb pressure on the anterior aspect, the maxilla is downfractured.
- Revise the osteotomies if there is difficulty in down fracturing.
- Mobilze the maxilla with the help of the Rowes dis-impaction forceps if required.
- Make sure the maxilla is completely detached and mobile.
- Now any movement is possible with the maxilla.

  e.g. forward, downward, impaction etc

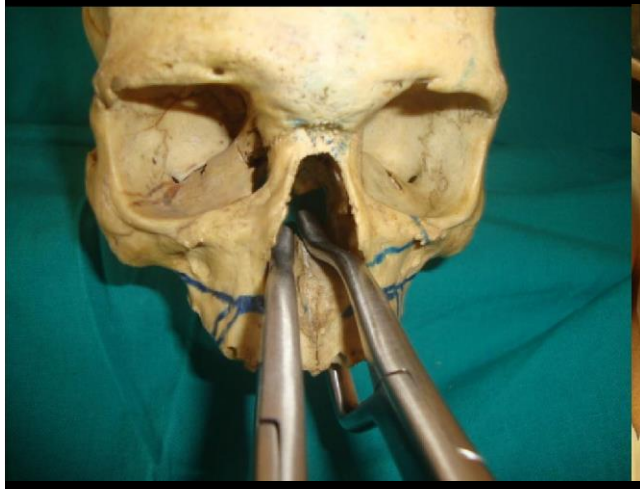

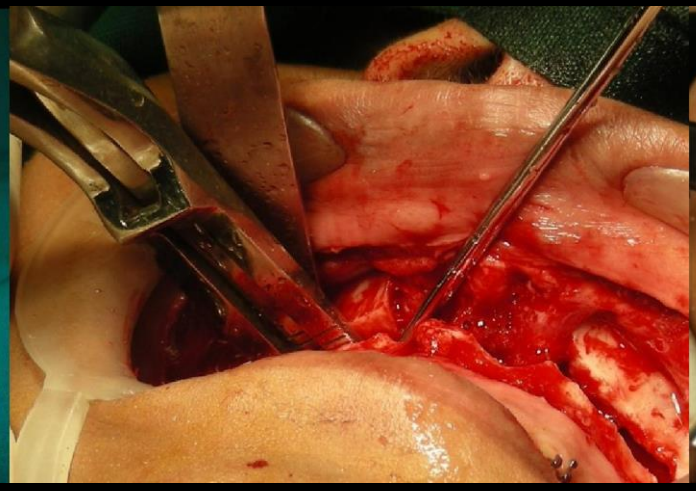

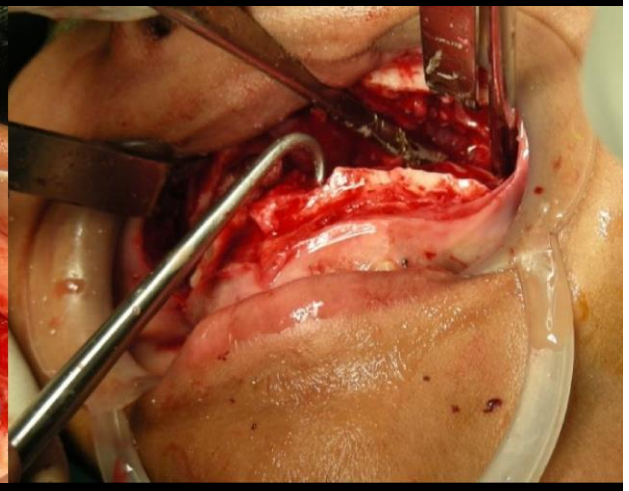

Fixation after performing a LeFort I Osteotomy

Fixation should be done after the occlusal splint is in place and inter maxillary fixation is done

Forward and/or downward movement

- 2mm "L" or straight bone plates at the zygomatic butress and piriform area

Forward and/or downward movement in high Lefort I osteotomy

- Same as previous in the zygomatic butress area with 2mm low profile bone plates at the piriform area

Impaction of maxilla

- Wire fixation at the zygomatic butress area because of telescoping of the maxilla and 2 mm bone plates at the piriform area

Fixation after performing a LeFort I Osteotomy

LeFort I Osteotomy

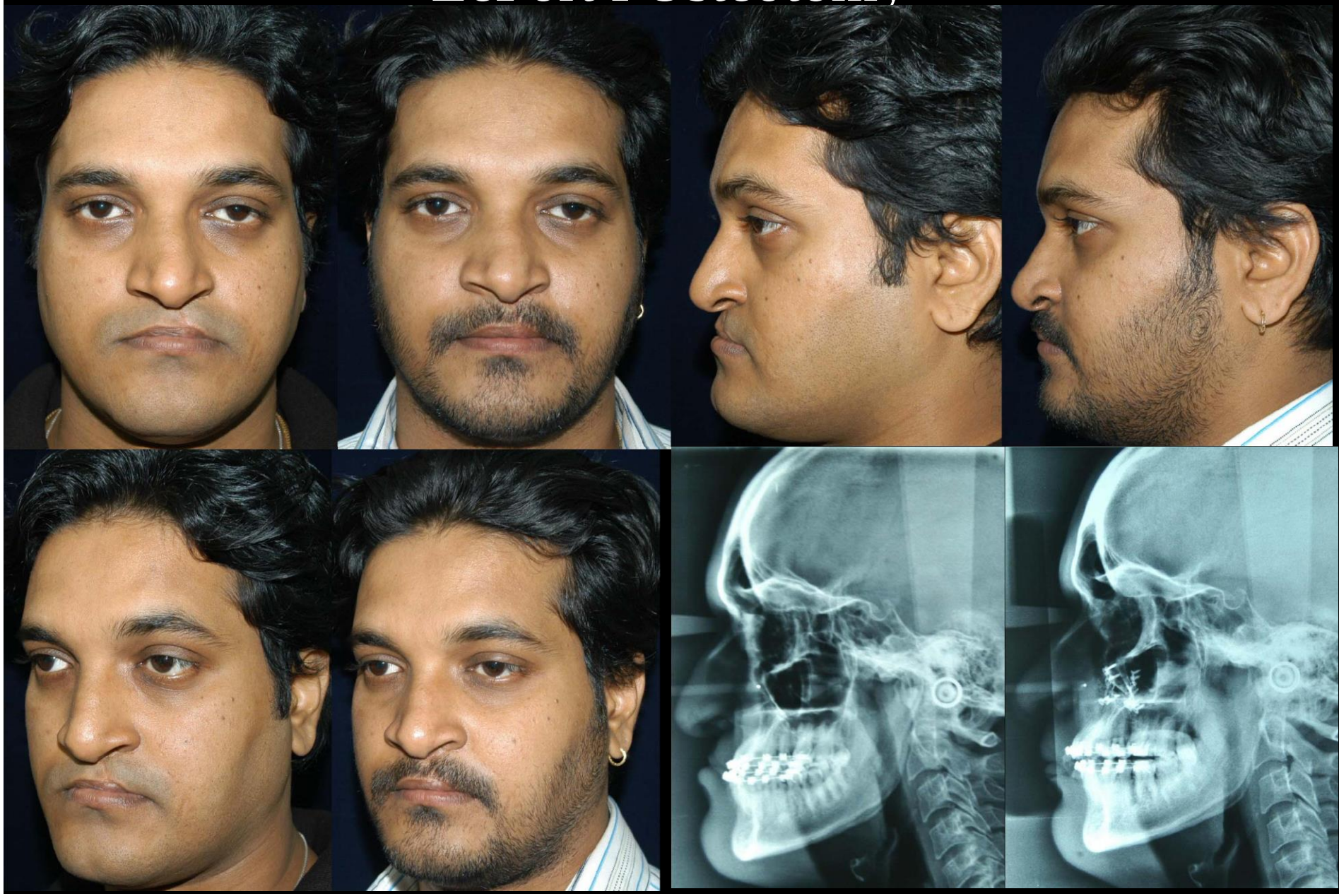

www.craniofacialinstitute.org

High LeFort I Osteotomy

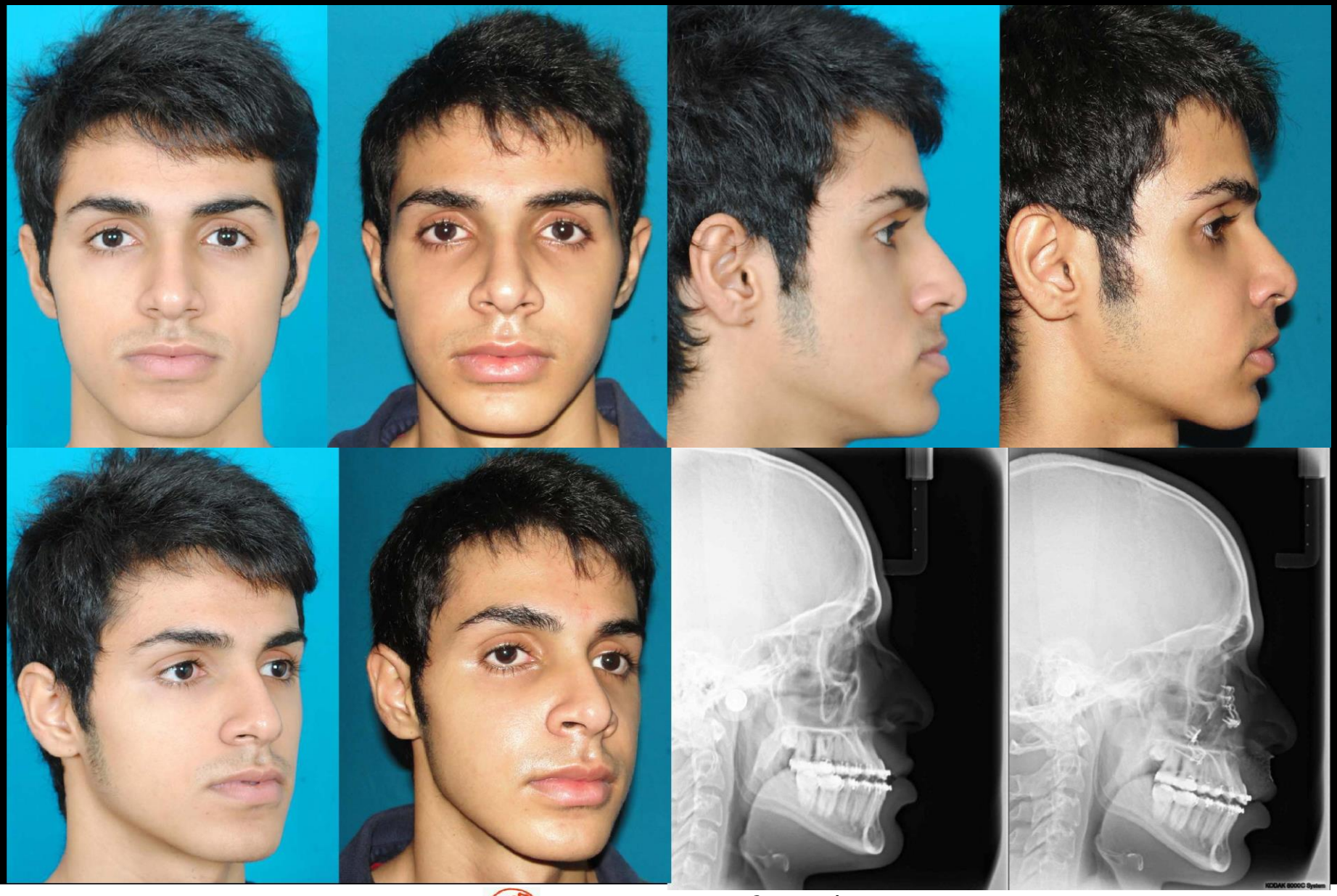

www.craniofacialinstitute.org

High LeFort I Osteotomy with Rhinoplasty

www.craniofacialinstitute.org

LeFort II osteotomy

- A pyramidal maxillary osteotomy.
- The osteotomy line extends from
  - ptyerigoid region on one side,
  - underneath the zygomaticomaxillary buttress
  - up over the medial portion of the infraorbital rim,
  - behind the lacrimal bone
  - along the medial wall of the orbit
  - to the dorsum of the nose

Performing a LeFort II Osteotomy

Skin Incision

The skin incision consists of bicoronal incision with the dissection as far forward and anterior as possible and a labial sulcus incision

Courtesy

Emil W. STE1NHAUSER Variations of Le Fort II Osteotomies for Correction of Midfacial Deformities J. max.-fac. Surg. 8 (1980) 258-265

Performing a LeFort II Osteotomy

The osteotomy starts at pterygoid region and continues under the butress and over the infra orbital rim, medial wall of orbit and dorsum of nose

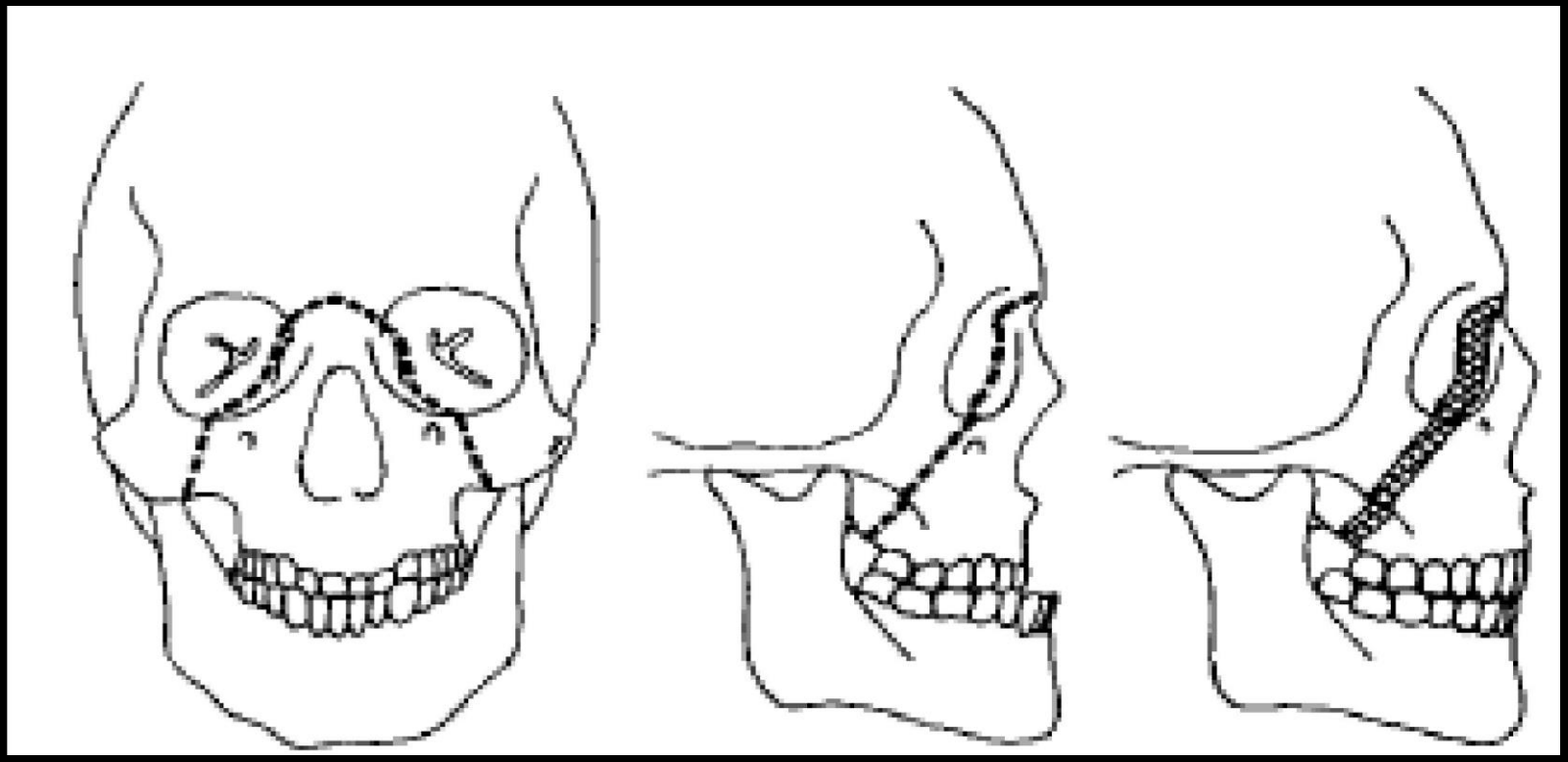

Courtesy
Emil W. STE1NHAUSER Variations of Le Fort II Osteotomies for Correction of Midfacial Deformities J. max.-fac. Surg. 8 (1980) 258-265

Fixation after performing a LeFort II Osteotomy

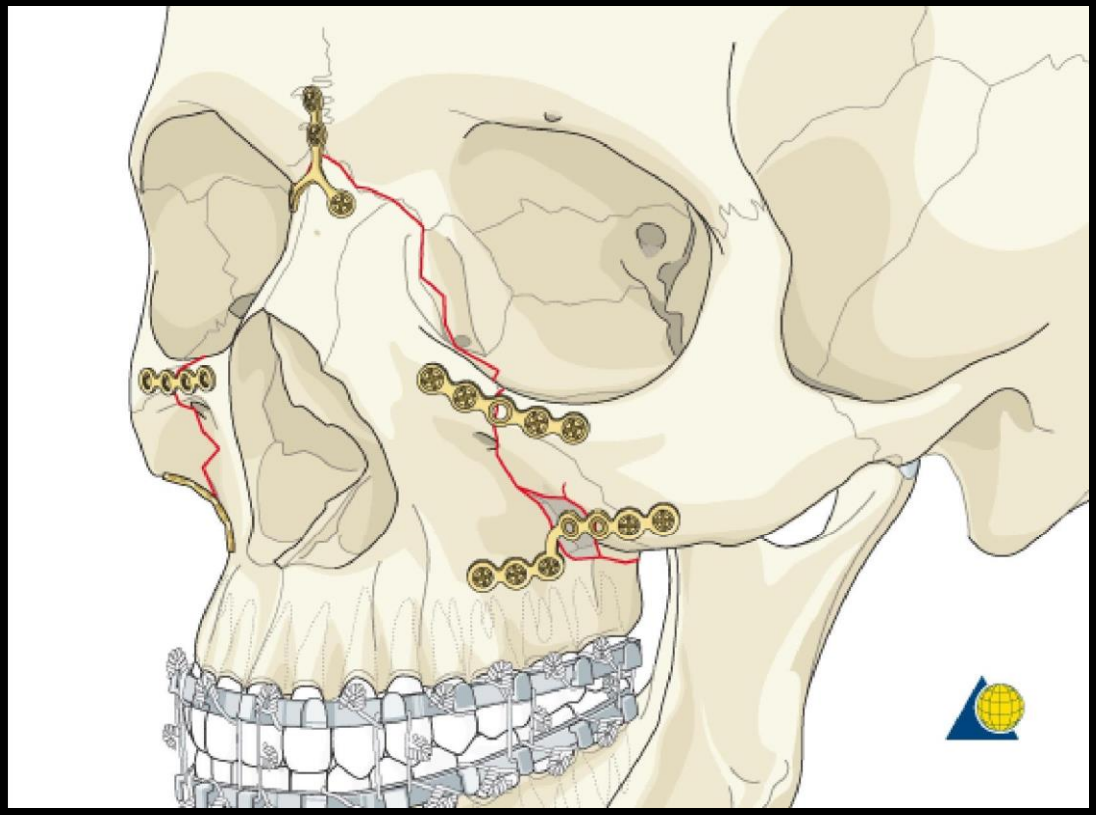

LeFort II osteotomy

Courtesy
Emil W. STE1NHAUSER Variations of Le Fort II Osteotomies for Correction of Midfacial Deformities J. max.-fac. Surg. 8 (1980) 258-265

LeFort III osteotomy

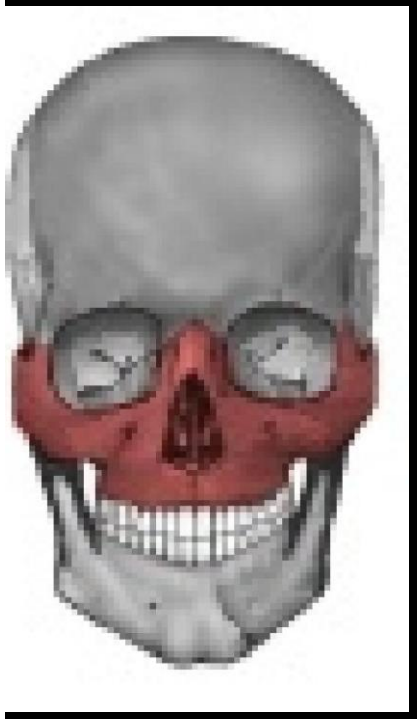

- The osteotomy line extends from
  - frontozygomatic suture along the lateral aspect of the internal orbit
  - continues along the sphenozygomatic suture line to the inferior orbital fissure,
  - extends medially across the floor of the orbit up the medial wall of the orbit
  - to the dorsum of the nose

LeFort III osteotomy
Indications

Deficiency of only the Maxillary, Malar, Zygomatic and Nasal Complex

Performing a LeFort III Osteotomy

Skin Incision

The skin incision consists of bicoronal incision with the dissection as far forward and anterior as possible.

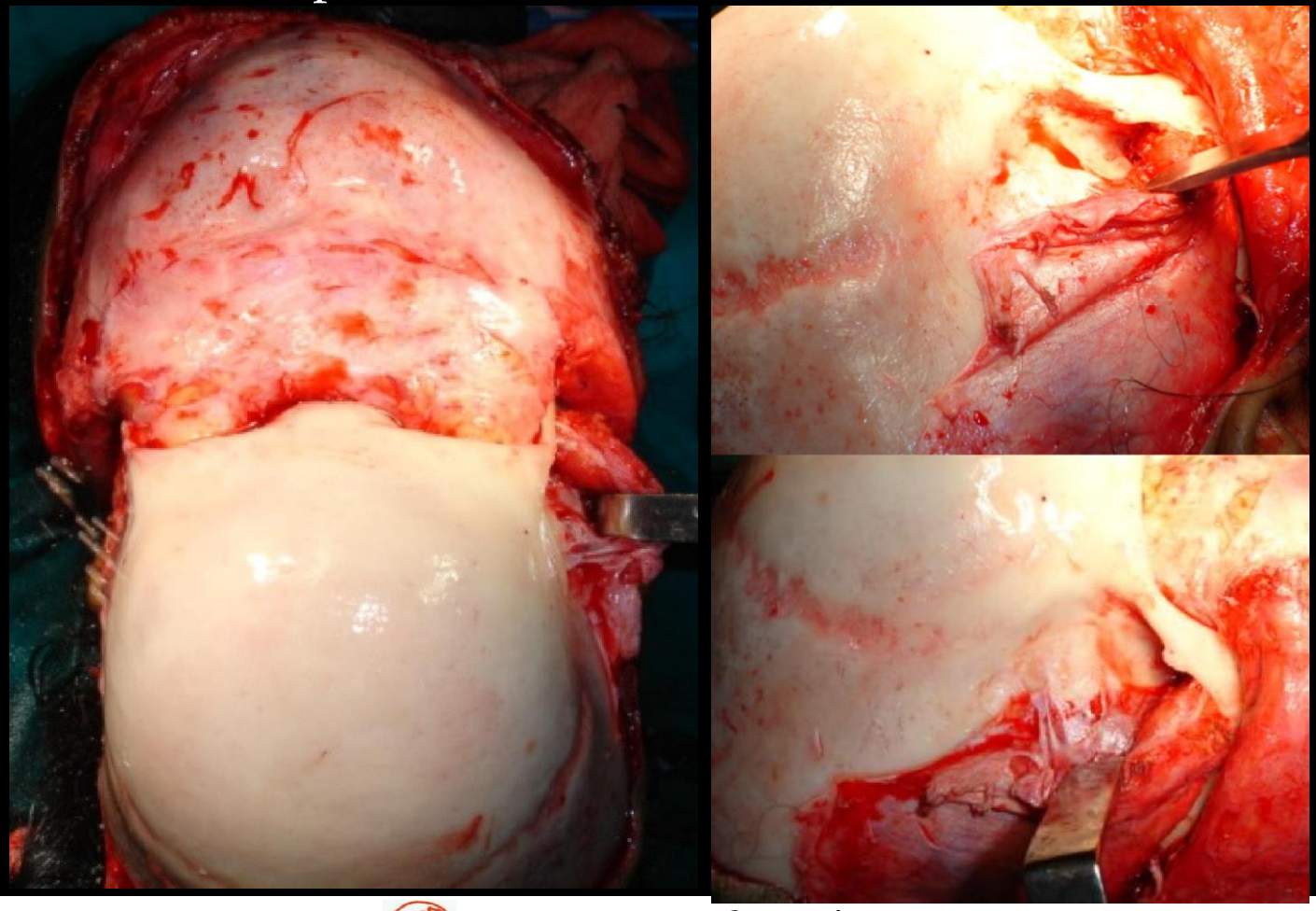

Performing a LeFort III Osteotomy

Frontozygomatic suture osteotomy and dysjunction of zygomatic arch is done

Orbital osteotomy along the lateral aspect of the internal orbit is done

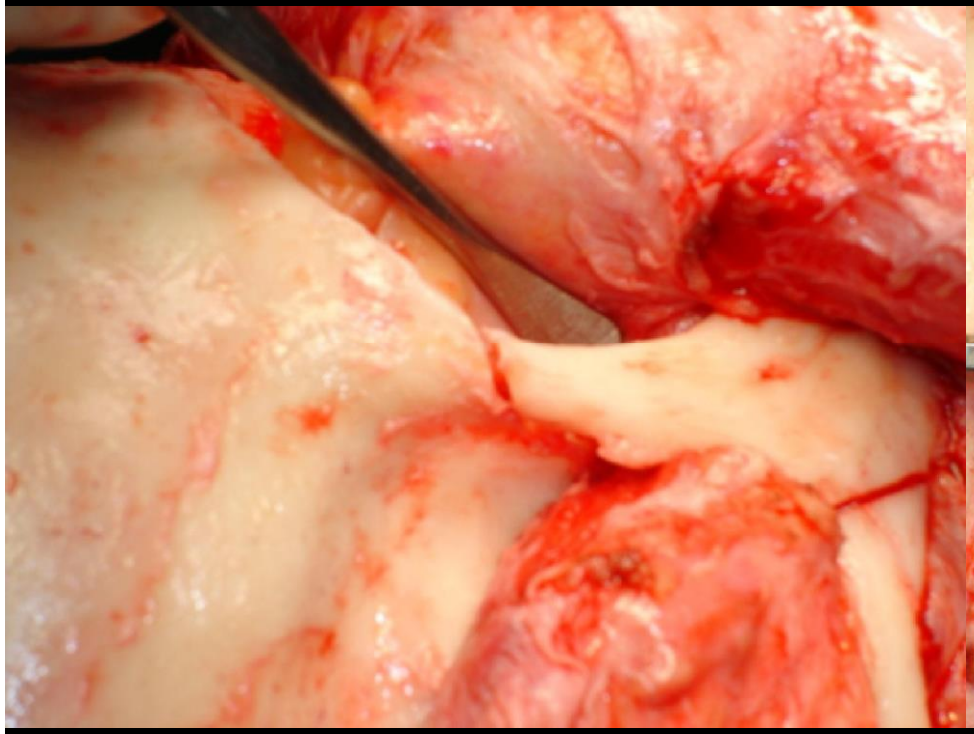

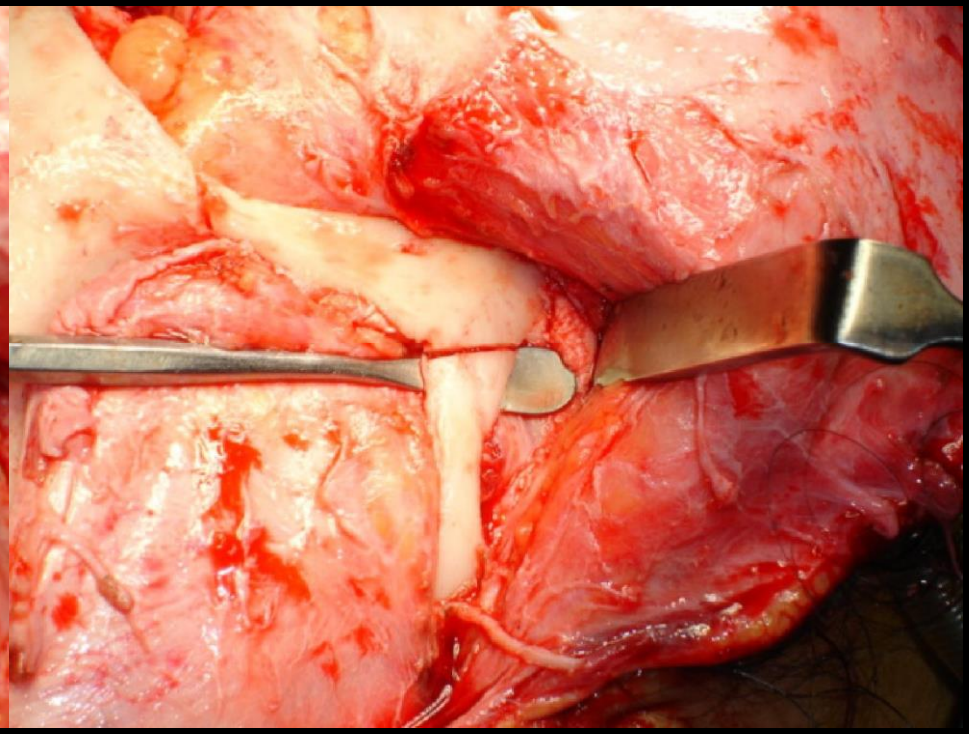

Performing a LeFort III Osteotomy

The osteotomy is continued along the sphenozygomatic suture line to the inferior orbital fissure.

The osteotomy then extends medially across the floor of the orbit up the medial wall of the orbit

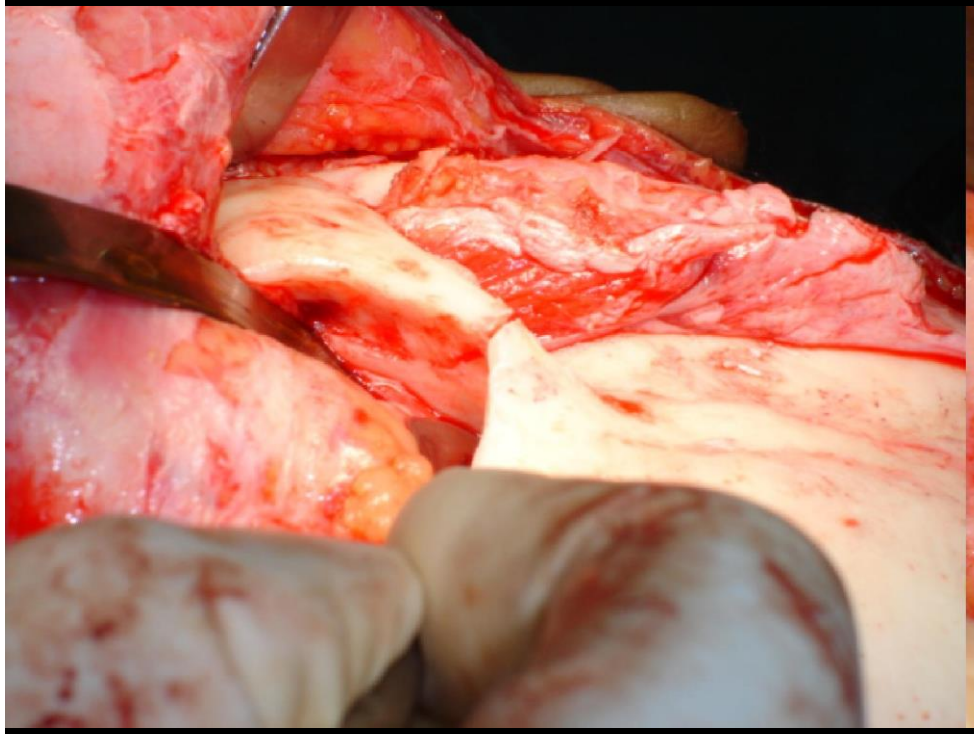

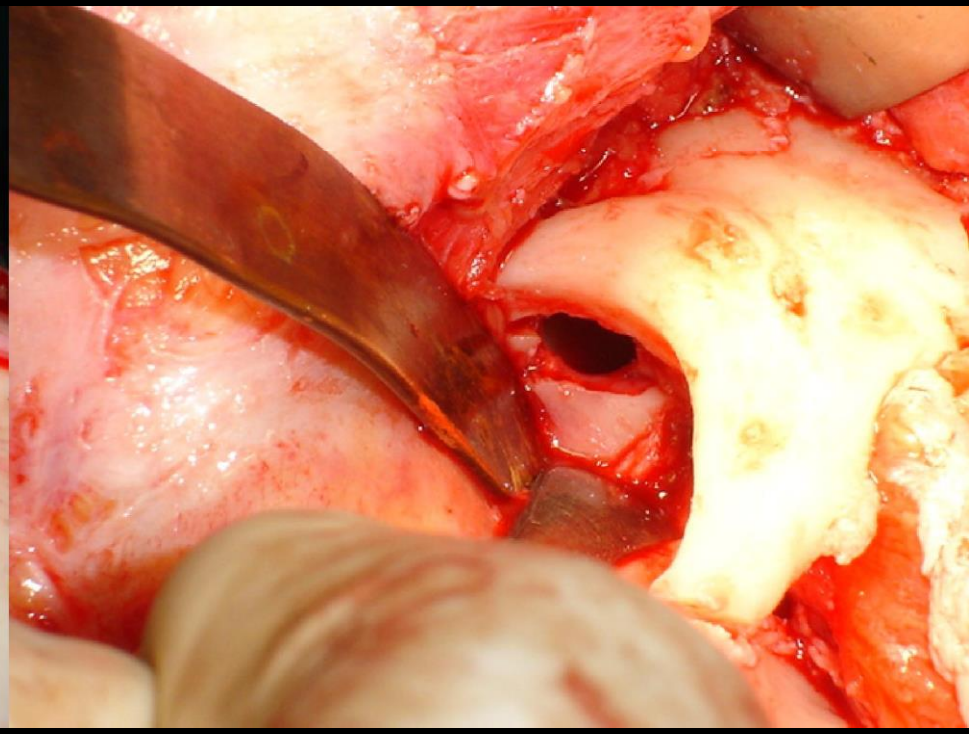

Performing a LeFort III Osteotomy

The osteotomy ends on the dorsum of the nose

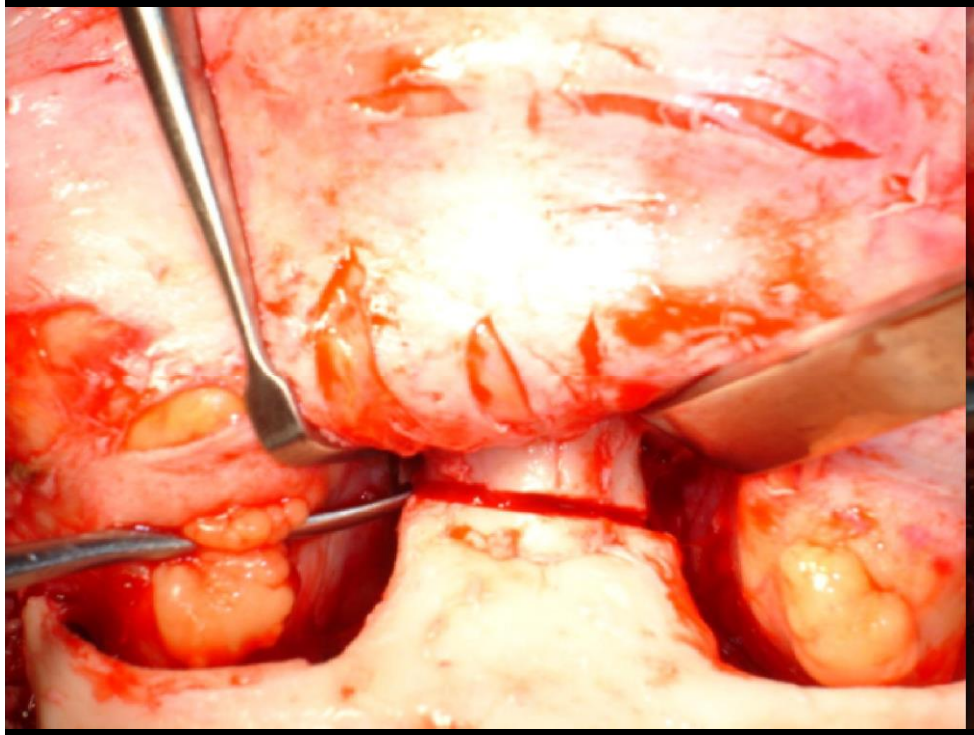

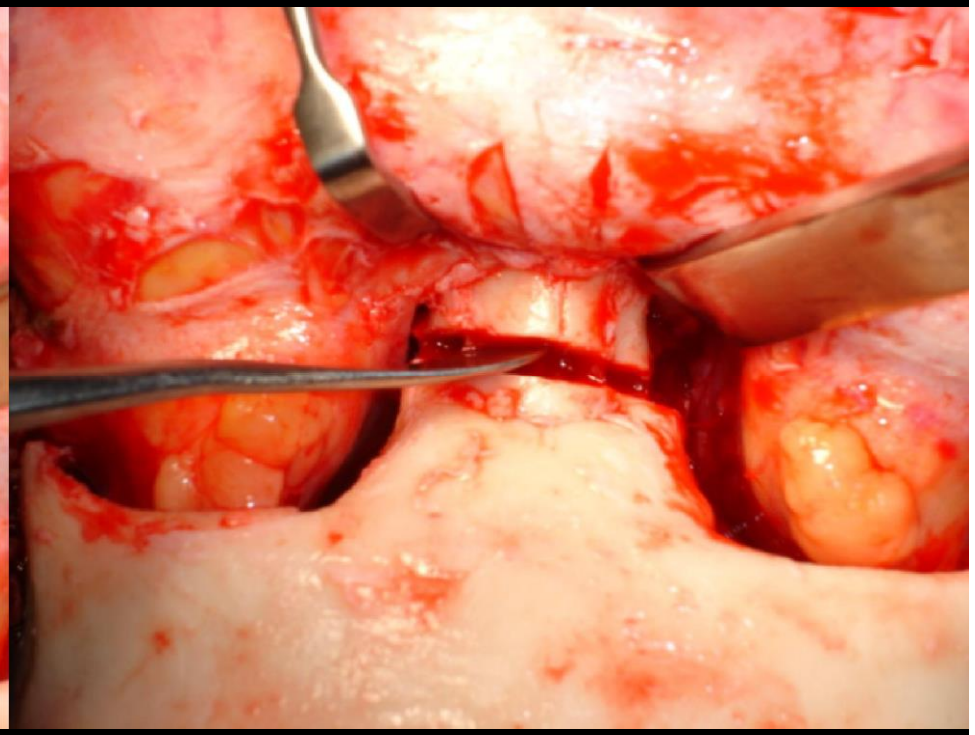

Performing a LeFort III Osteotomy

Calvarial bone graft is harveted

Fixation after performing a LeFort III Osteotomy

Fixation is done with 1.5 mm low profile plates at the nasal and frontozygomatic areas with interposition of bone grafts

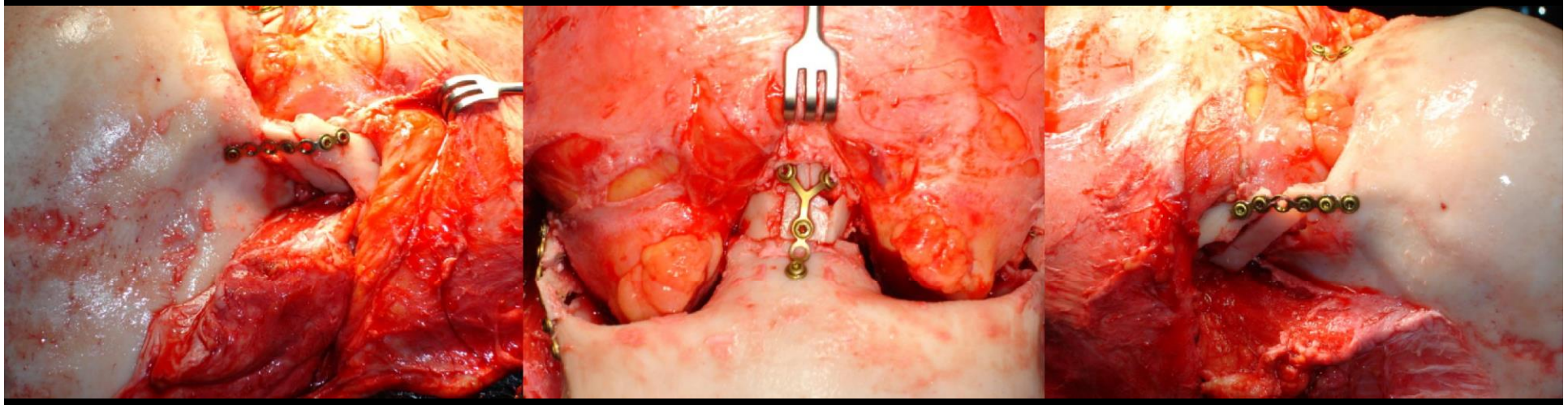

LeFort III Osteotomy

www.craniofacialinstitute.org

LeFort Osteotomy Complications

- Infraorbital nerve traction injury
- Unanticipated fractures (pterygoid plate, sphenoid bone, middle cranial fossa)
- Injury to the internal maxillary artery and its branches
- Ophthalmic and lacrimal duct injury
- Avascular necrosis
- Maxillary sinusitis
- Velopharyngeal insufficiency
- Nasal septal deviation and buckling
- Arteriovenous fistulas (carotid-cavernous sinus)

LeFort Osteotomy
Complications
Intra cerebral hemorrhage

DISTRACTION OF THE

MAXILLARY/NASAL COMPLEX

ZYGOMATIC/MALAR COMPLEX

LeFort I Distraction

LeFort I Distraction

Secondary Cleft Maxilla

SCM Discrepancy:

- Transverse dimension
- Anterio-posterior dimension

SCM Pathophysiology:

- Loss of the bony support anteriorly in the cleft alveolus and medially in the cleft maxilla.
- Scar in the midline of the palate and the maxillary tuberosity area.

Orthodontic Procedure:
Banding, Brackets and Archwire

Orthodontic Procedure: Arch form

Surgical Protocol

Surgery:

Traditional LeFort I osteotomy without complete disimpaction of maxilla

Latency period:

5 days following osteotomy and application of the device

Active distraction:

1 mm per day with over distraction of 15 to 20 percent

Rigid retention:

8 weeks from the date of stoppage of distraction

Elastic retention:

4 weeks from removal of rigid retention

Surgical Procedure Distraction

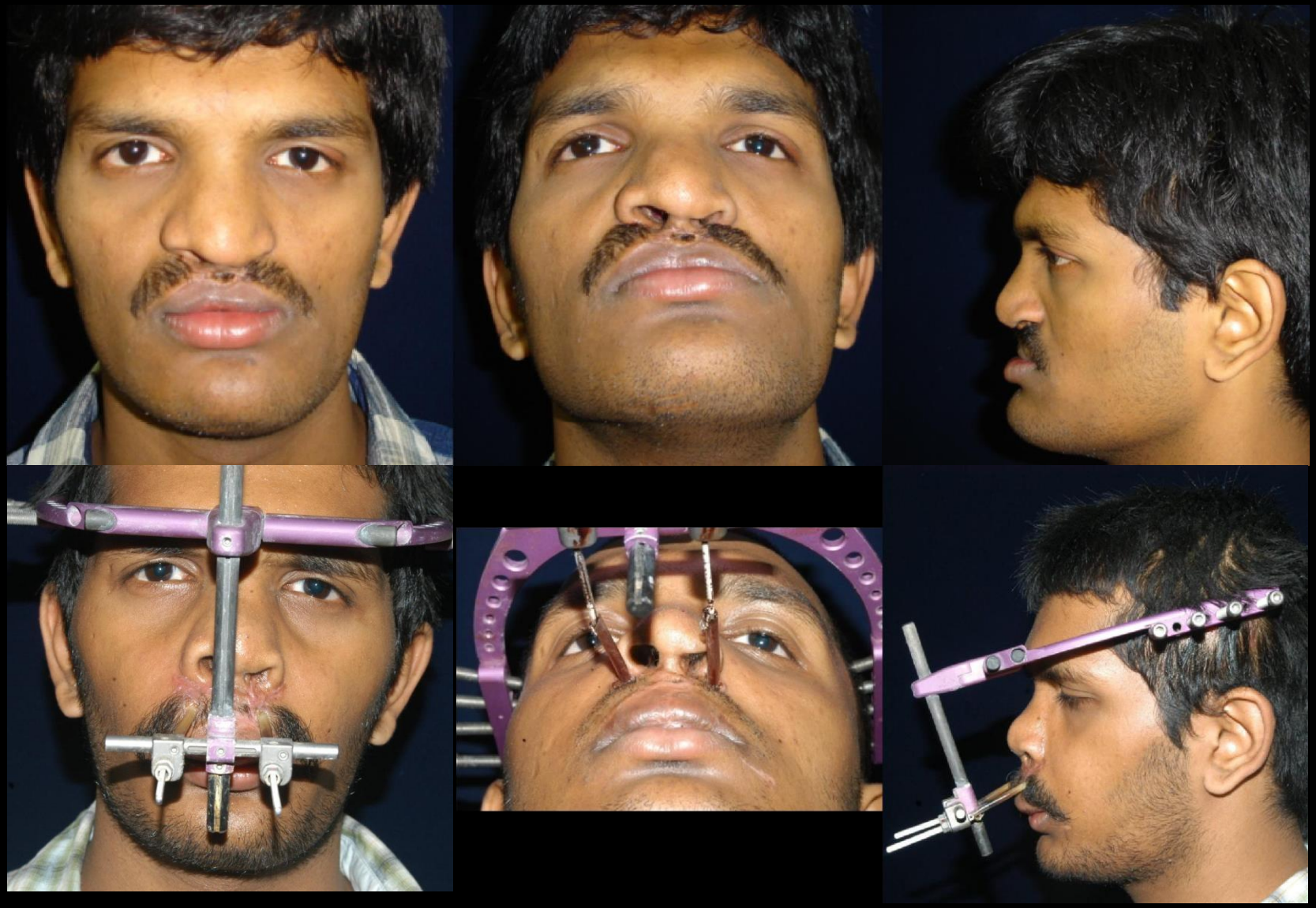

Surgical Procedure Distraction

Pre op **3 months post op** **2 year post op**

www.craniofacialinstitute.org

Surgical Procedure Distraction

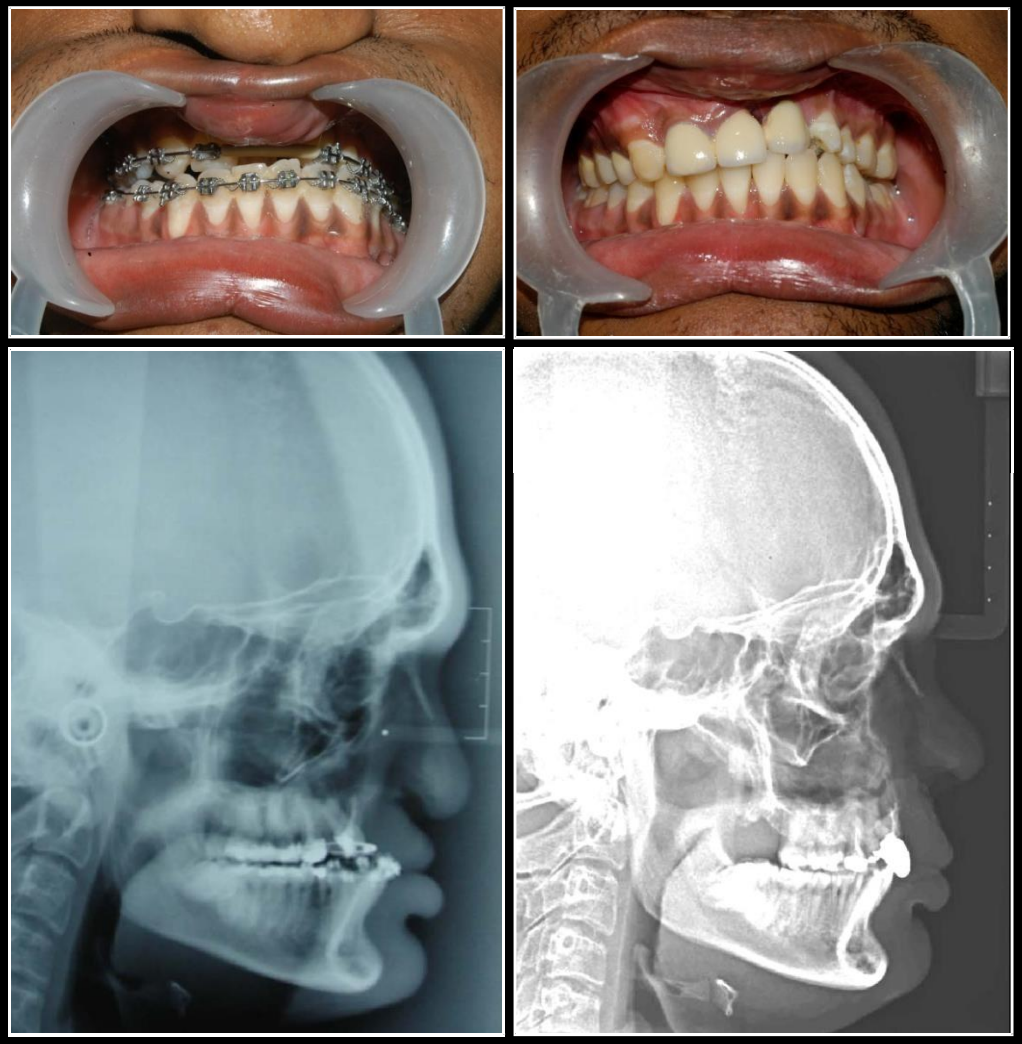

Pre op **Post op**

LeFort II Distraction

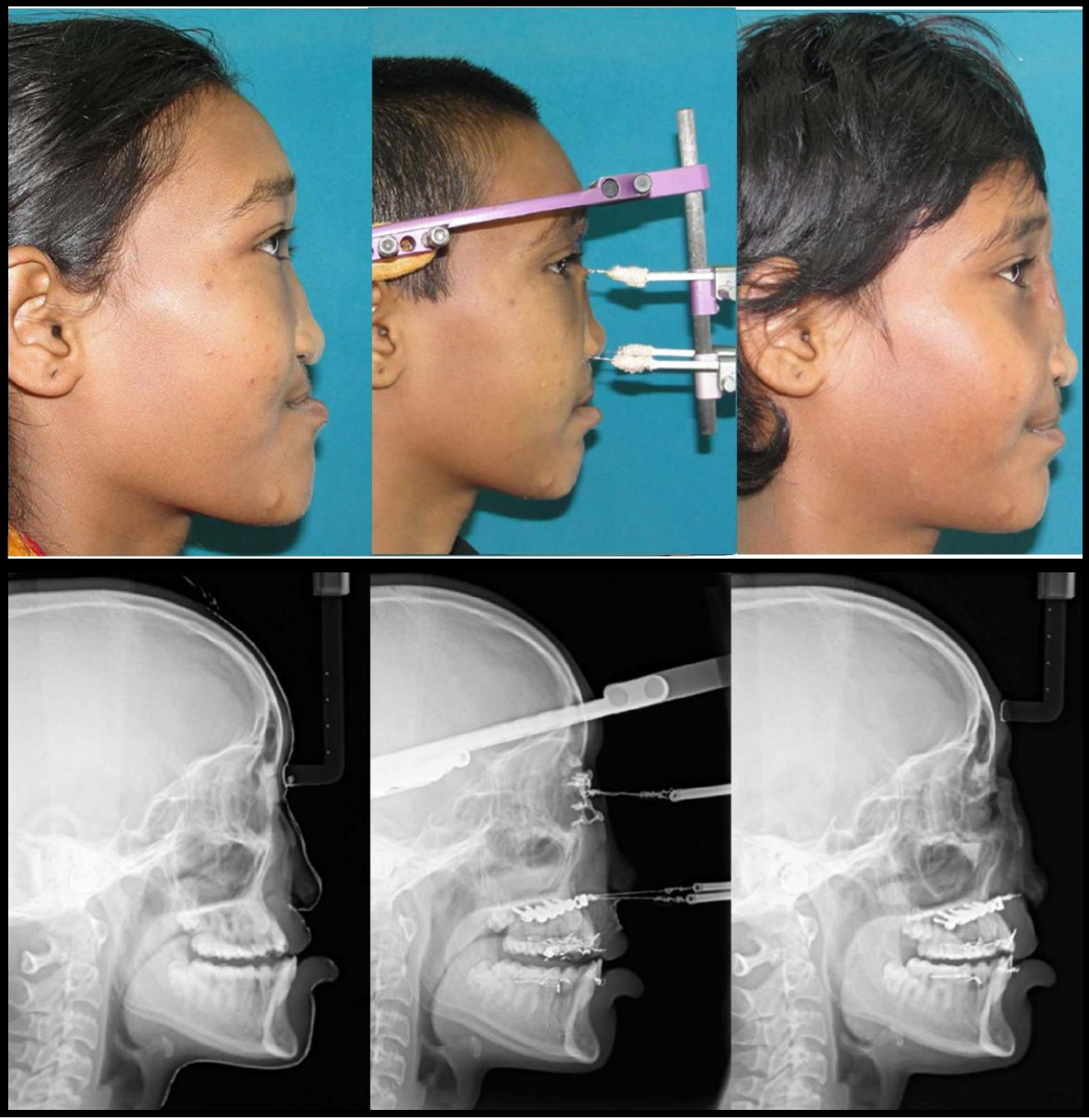

www.craniofacialinstitute.org

LeFort III Distraction

www.craniofacialinstitute.org

Repositioning of Facial Skeleton

- Maxillary Complex
- Mandibular Complex
- Naso-orbital Complex
- Frontal Complex

LeFort I + Bilateral Saggital Split Osteotomy

www.craniofacialinstitute.org

LeFort I Osteotomy + Genioplasty + Rhinoplasty

www.craniofacialinstitute.org

Repositioning of Facial Skeleton

- Maxillary Complex
- Mandibular Complex
- Naso-orbital Complex
- Frontal Complex
- Ear

Genioplasty

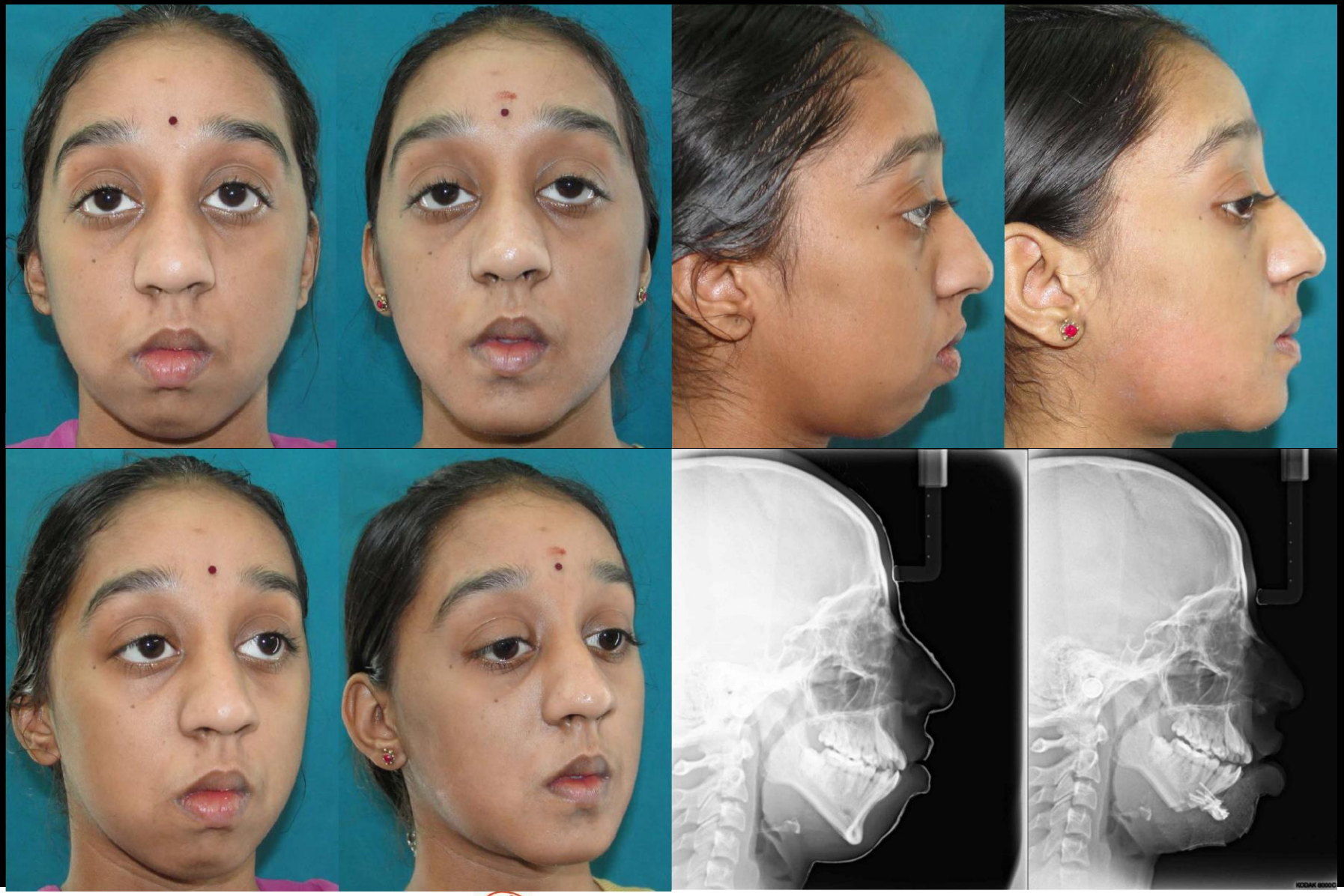

www.craniofacialinstitute.org

Propellar Genioplasty

Distraction in Correction of Hemifacial Microsomia

Pruzansky Type III Hemifacial Microsomia

www.craniofacialinstitute.org

Distraction in Correction of Hemifacial Microsomia

www.craniofacialinstitute.org

Distraction in Post TMJ Ankylosis Release

Distraction in Post TMJ Ankylosis Release

Distraction in Post TMJ Ankylosis Release

Repositioning of Facial Skeleton

- Maxillary Complex
- Mandibular Complex
- Naso-orbital Complex
- Frontal Complex
- Ear

Naso-orbital Complex

Severe Hypertelorism

- Caused by encephalocele, facial clefting or in Apert's and Cruzon's syndrome.

Indications for intracranial approach

- The absolute indication for the intra cranial approach are an encephalocele and a cribiform plate lower that the level of the nasofrontal suture.

Naso-orbital Complex

Tessier #14 Craniofacial Cleft

www.craniofacialinstitute.org

Naso-orbital Complex
CT Scan

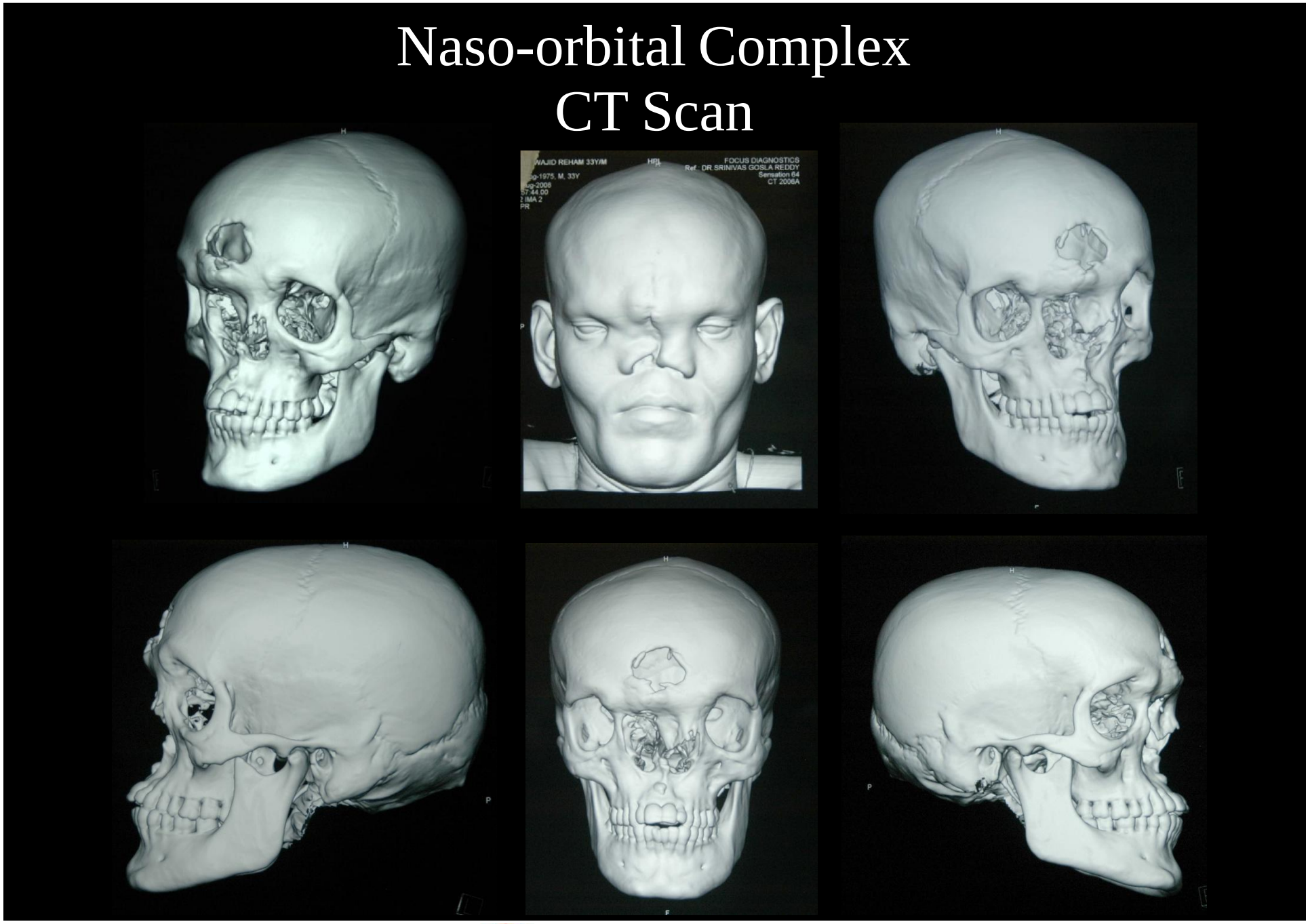

www.craniofacialinstitute.org

Naso-orbital Complex

Stereo Lithographic Models

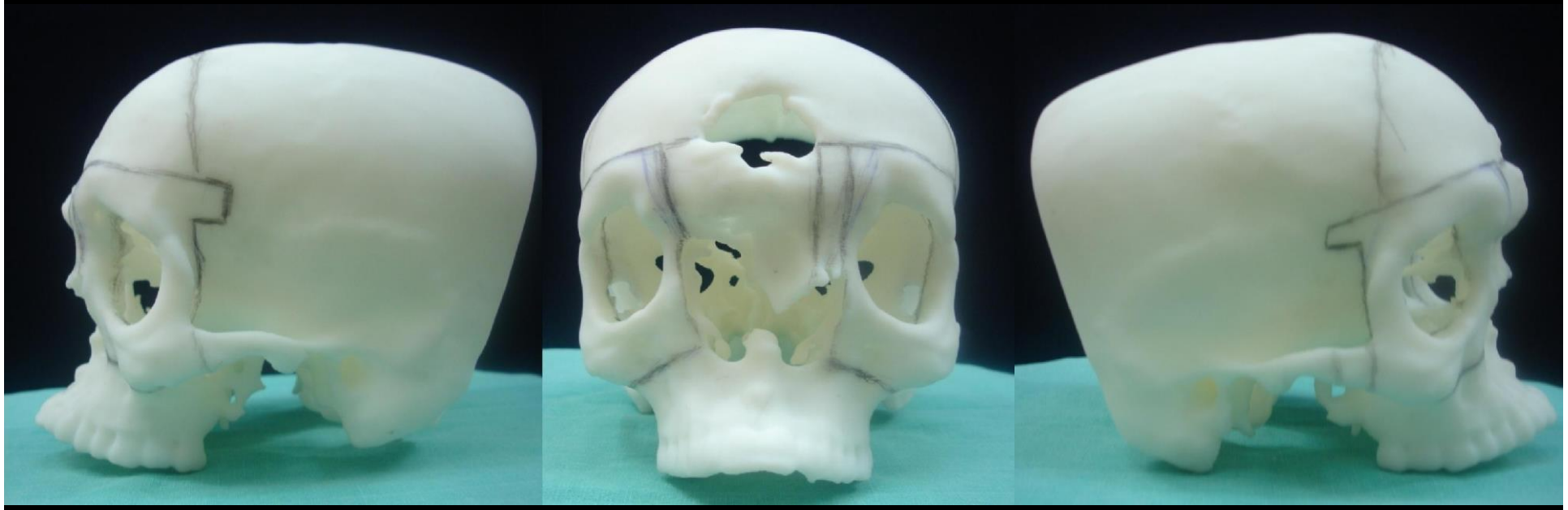

Naso-orbital Complex

Hypertelorism

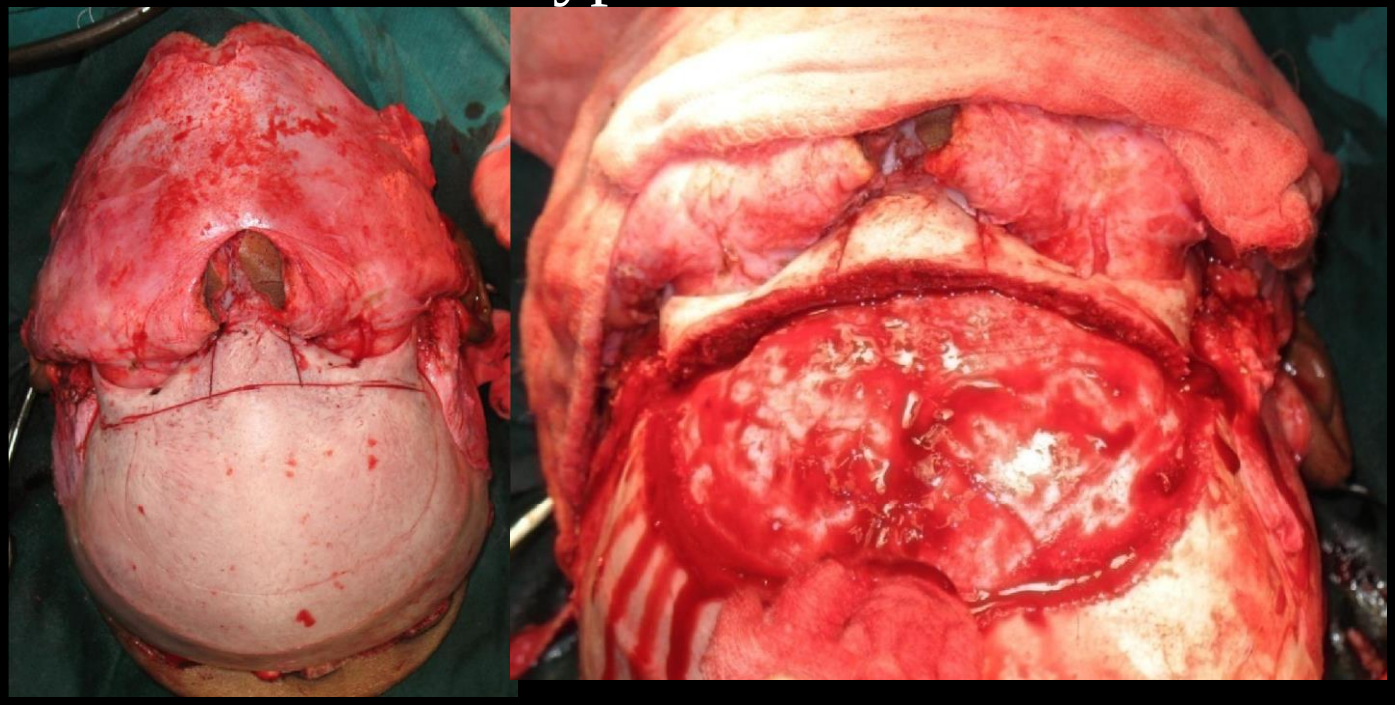

Transfrontal Craniotomy

This includes a transfrontal craniotomy with an intervening frontal bar, which is left intact.

The frontal bar results from parallel osteotomies that are atleast 1 cm from the supraorbital rims and permits orientation of the orbits once they have been mobilized

Naso-orbital Complex

Hypertelorism

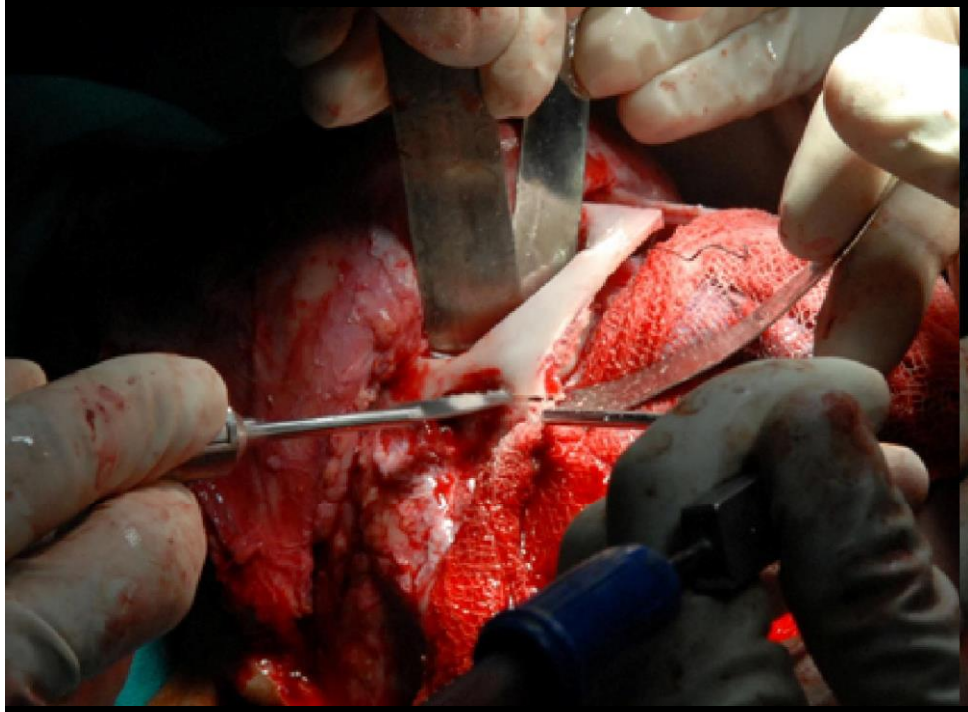

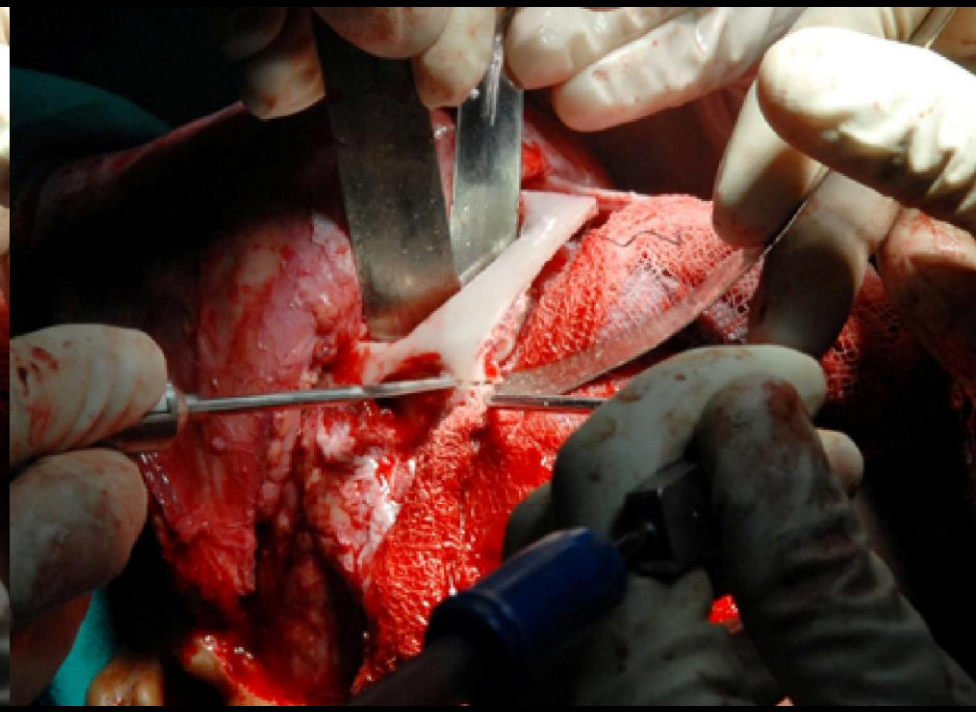

Periorbital Osteotomy

A periorbital osteotomy is completed initially extracranially, going parasagitally through the frontozygomatic region, the finally intracranially.

Lateral Orbital Wall Osteotomy

Naso-orbital Complex

Hypertelorism

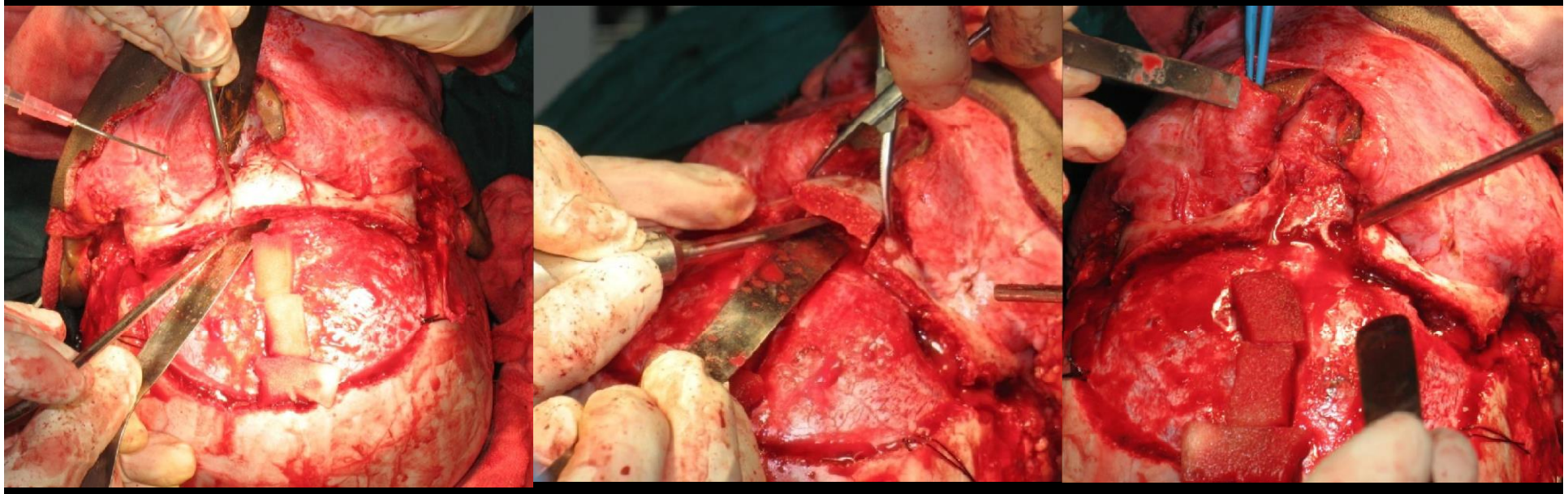

Orbital roof osteotomy

The bony cuts of the orbital roofs are performed with intracranial visualization

Orbital approximation

A central block of bone is removed between the orbits to allow their approximation in a medical direction.

Naso-orbital Complex
Hypertelorism

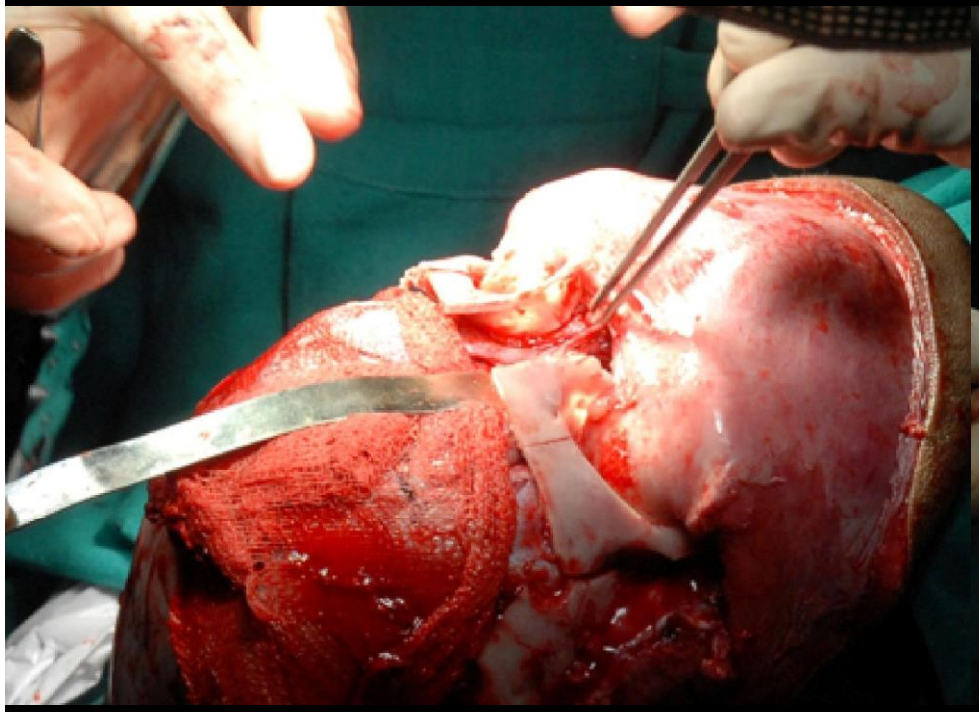

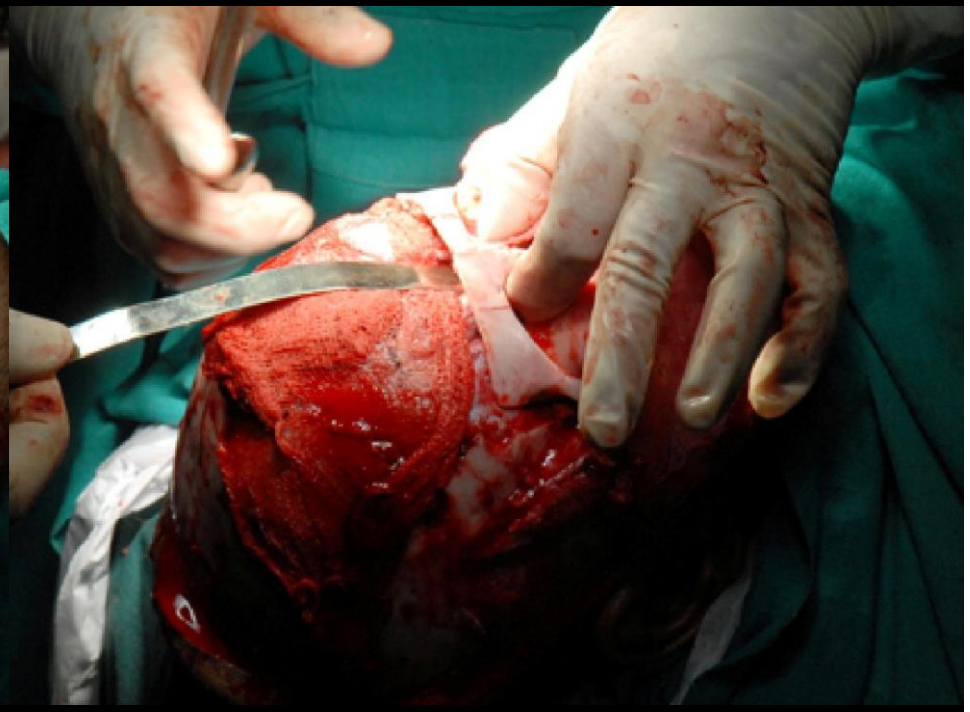

Finishing osteotomy

Finally, a wedge of bone is removed from either side of piriform fossa so that the nasal airways are not constricted when the orbits are moved medially.

If the osteotomies have been performed to their full depth, the orbits can be approximated by finger pressure alone

Naso-orbital Complex

Hypertelorism

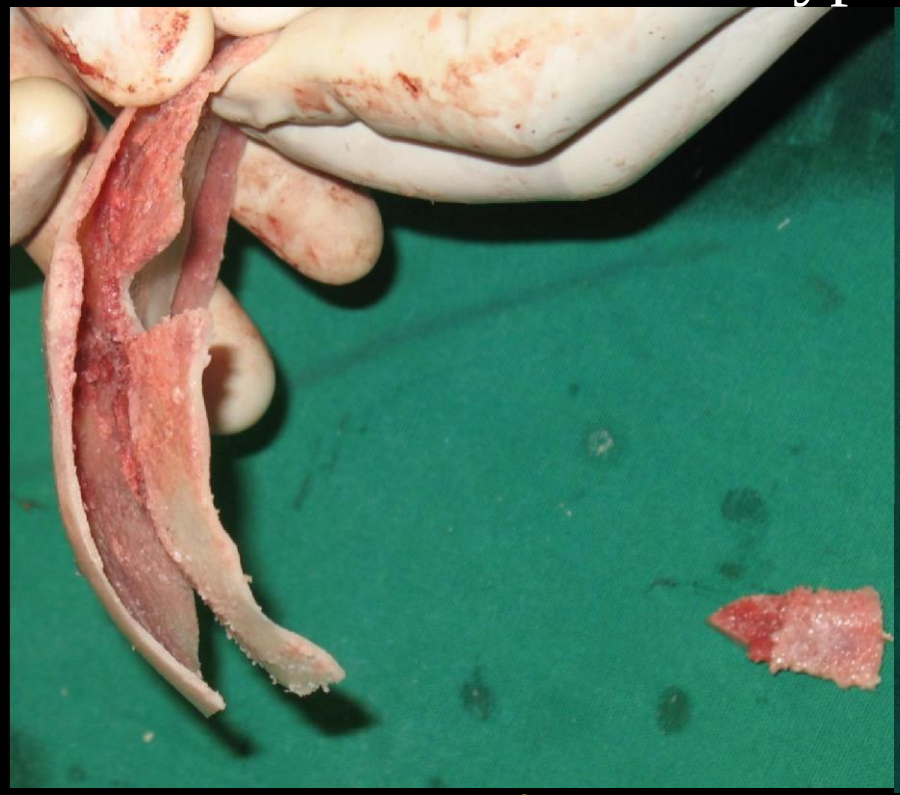

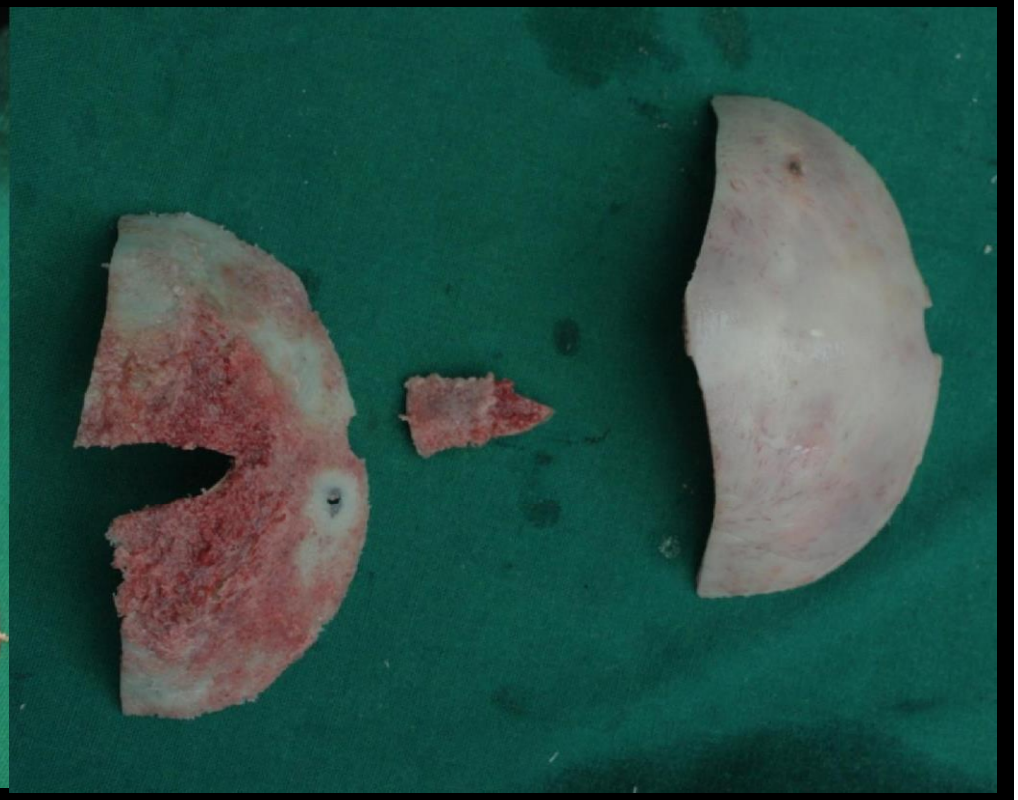

Fixation and bone grafting

Bone graft material harvested from the calvarium can be split into into the two cortices and one cortex can be used to graft bone in the defects and the other can be used to close the original defect

Naso-orbital Complex

Hypertelorism

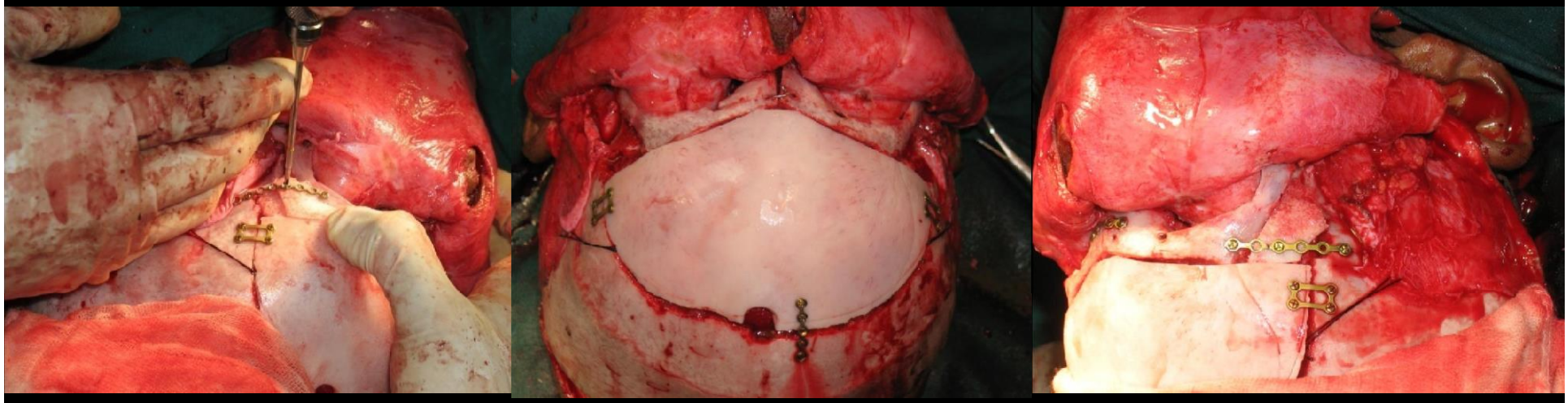

Fixation and bone grafting

The orbits are positioned and held in place with wires or micro-or miniplates.

Bone graft material harvested from the clavarium, iliac crest, or rib is then used to fill in the resulting gap defects at the lateral orbital walls and zygomatic areas

Naso-orbital Complex

Tessier #14 Craniofacial Cleft

www.craniofacialinstitute.org

Grafting of Facial Skeleton

- Maxillary Complex
- Mandibular Complex
- Naso-orbital Complex
- Frontal Complex
- Ear

Grafting of Maxillary and Nasal Complex

Grafting of Maxillary and Nasal Complex

Grafting of Maxillary and Nasal Complex

Grafting of Facial Skeleton

- Maxillary Complex
- Mandibular Complex
- Naso-orbital Complex
- Frontal Complex
- Ear

Grafting of Mandibular Complex

Type II a HFM

Grafting of Mandibular Complex

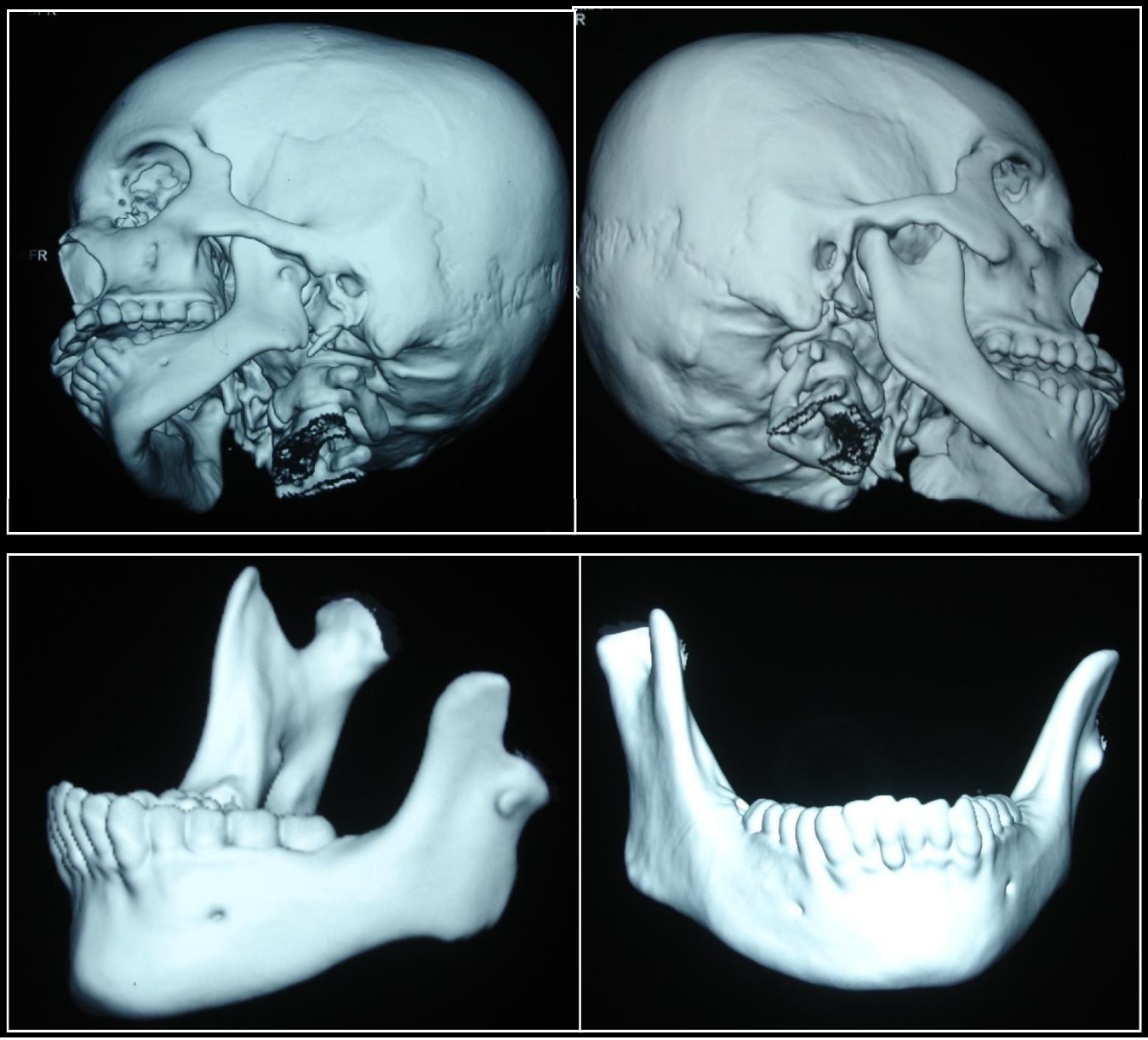

Grafting of Mandibular Complex

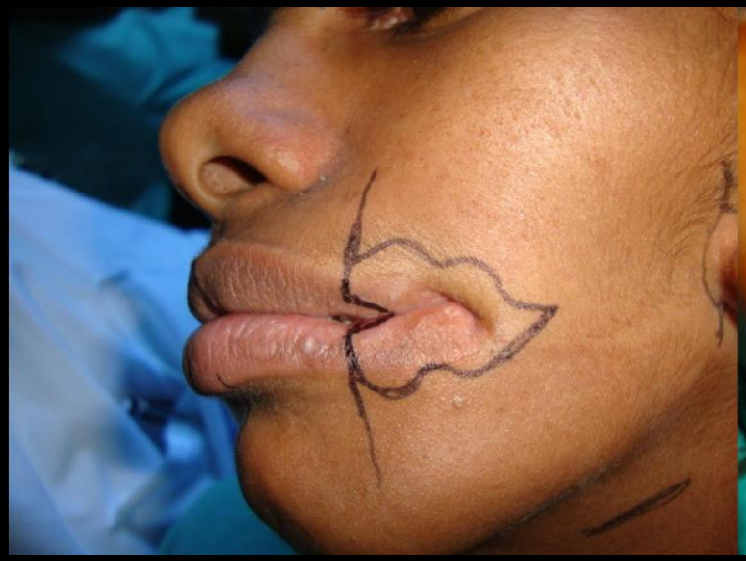

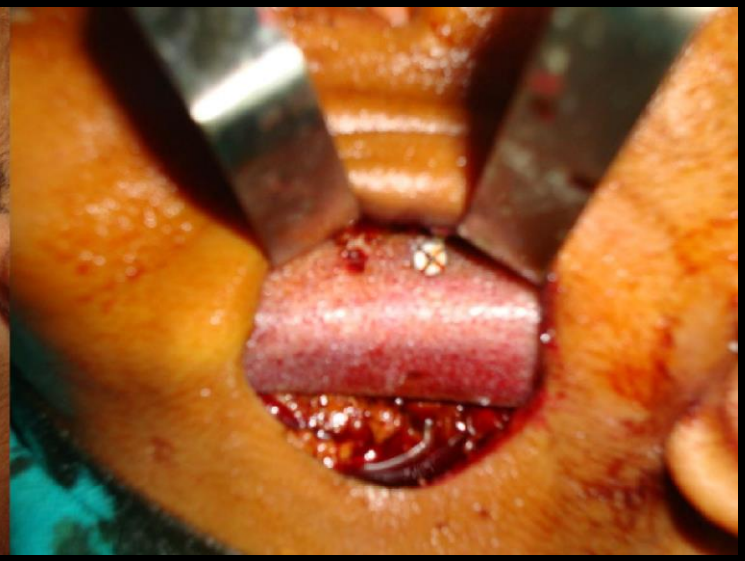

Grafting of Mandibular Complex

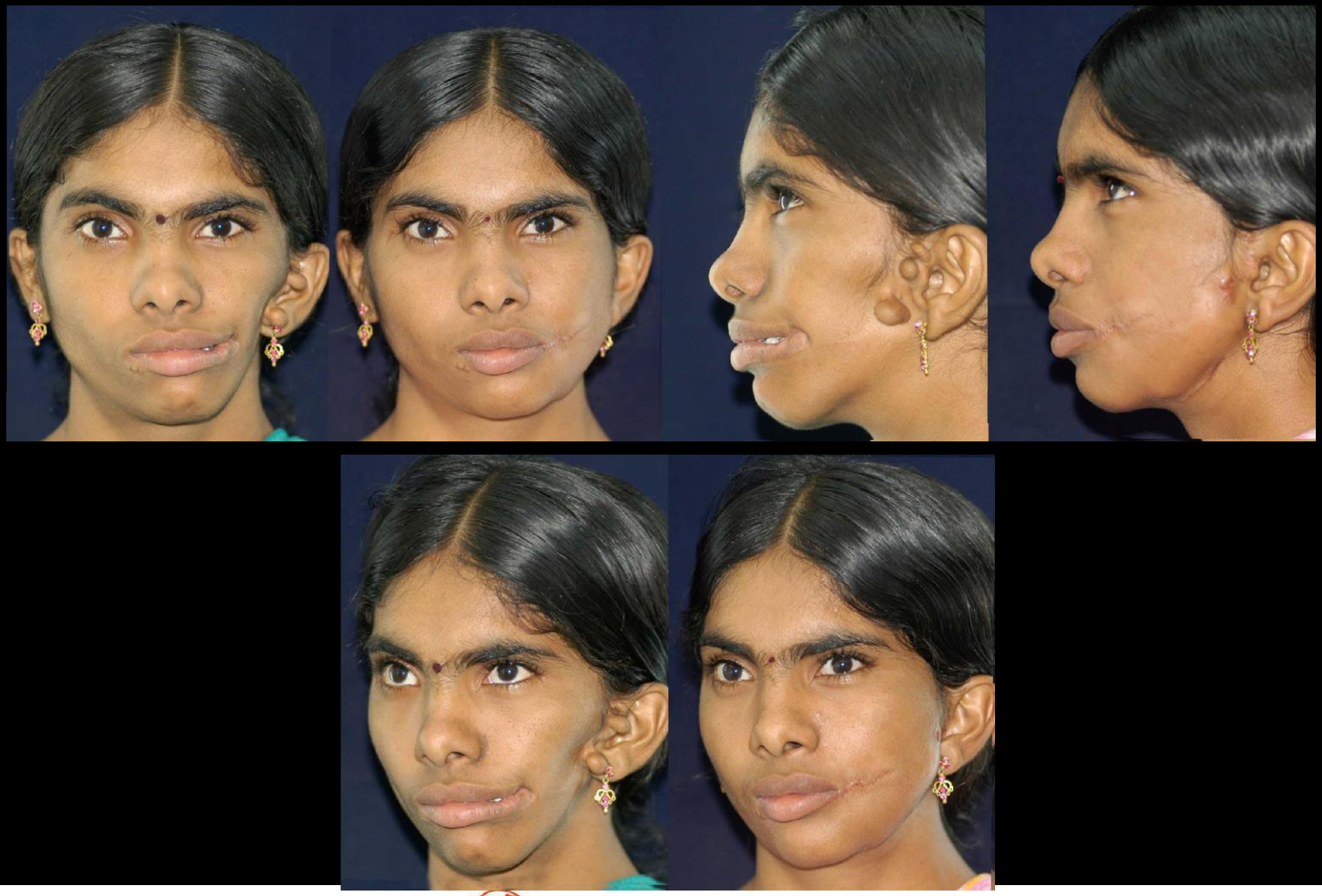

Grafting of Facial Skeleton

- Maxillary Complex
- Mandibular Complex
- Naso-orbital Complex
- Frontal Complex
- Ear

Heminasal Aplasia

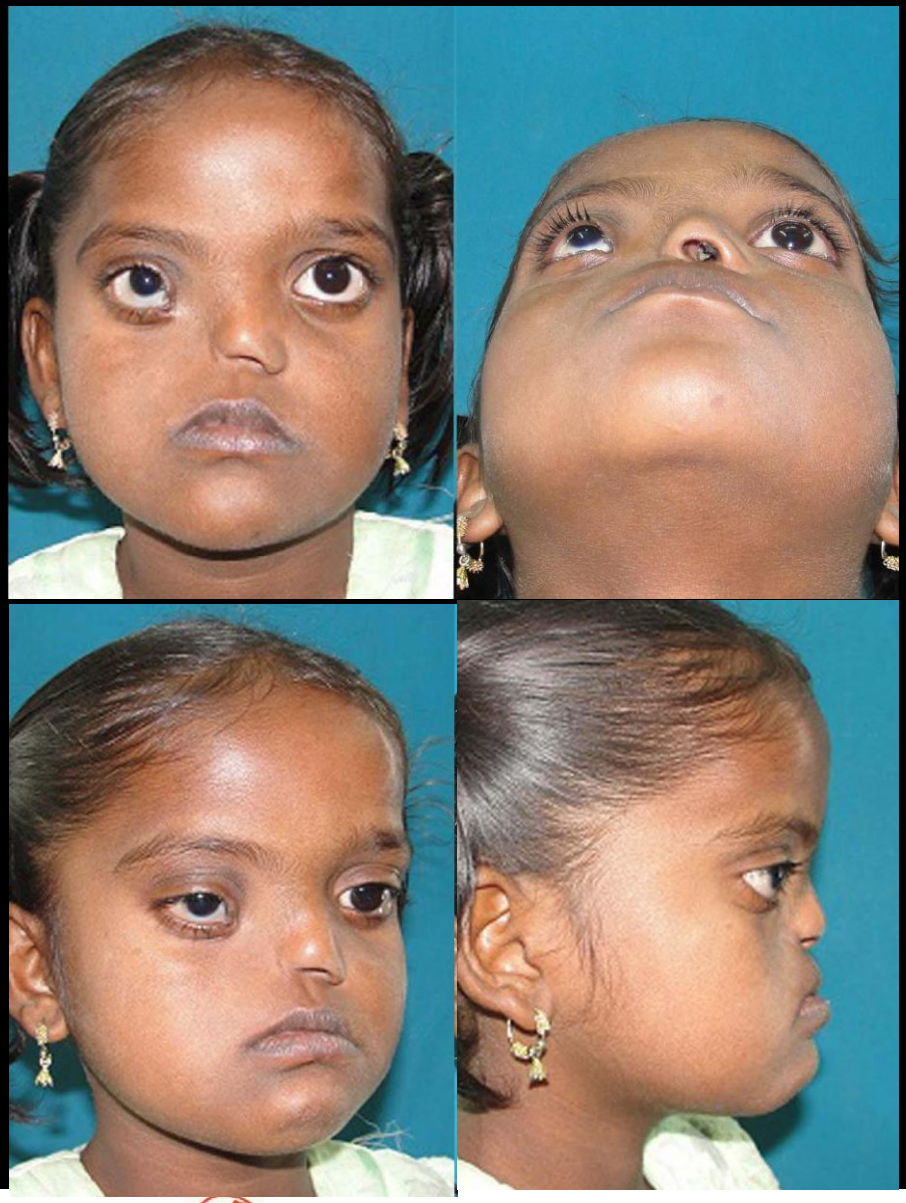

Heminasal Aplasia

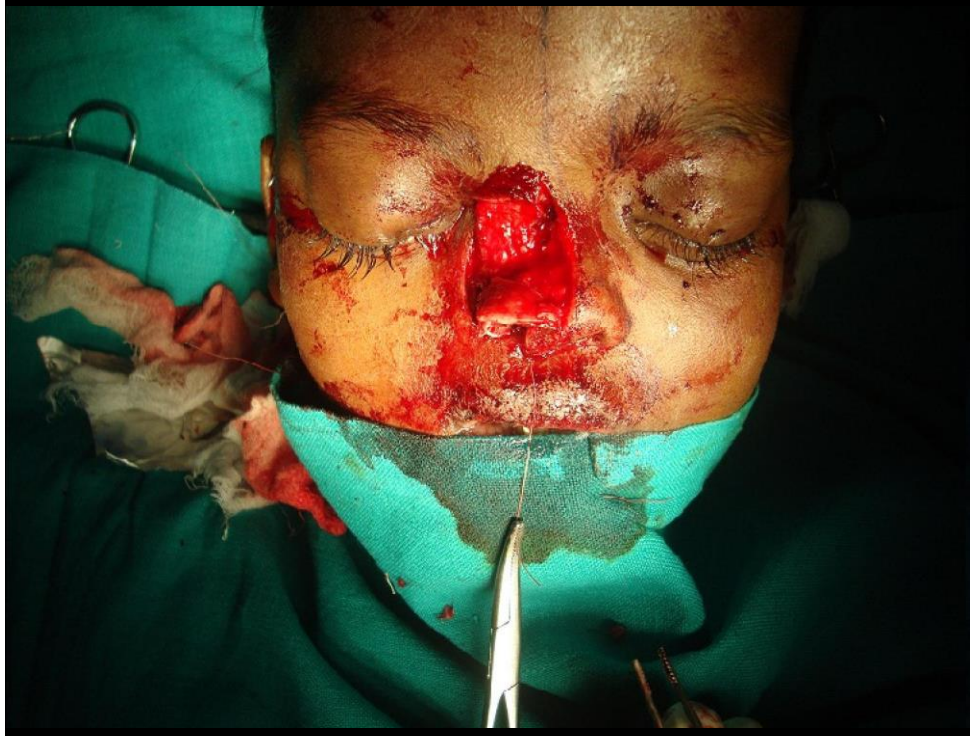

Heminasal Aplasia

www.craniofacialinstitute.org

Noma

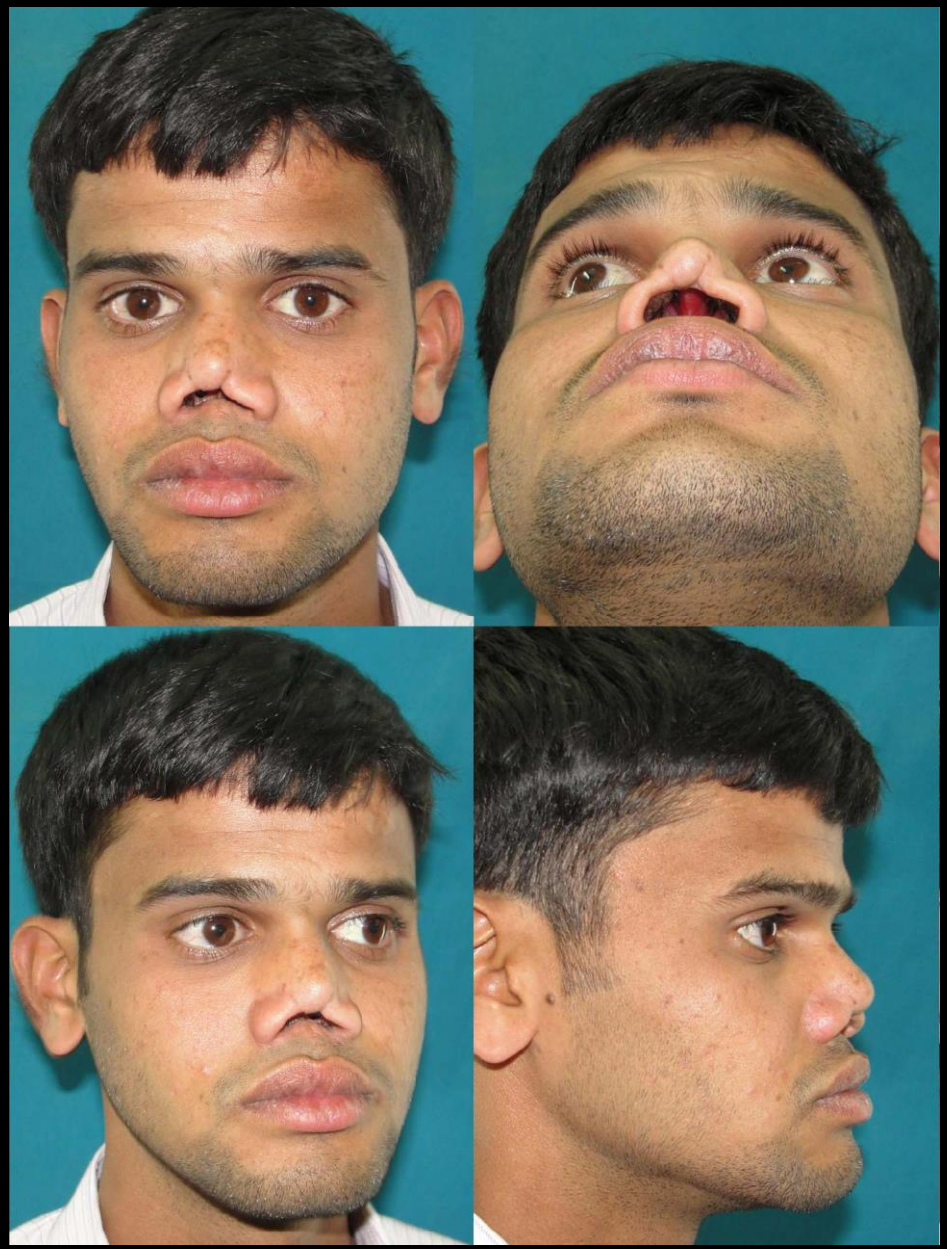

www.craniofacialinstitute.org

Noma

Noma

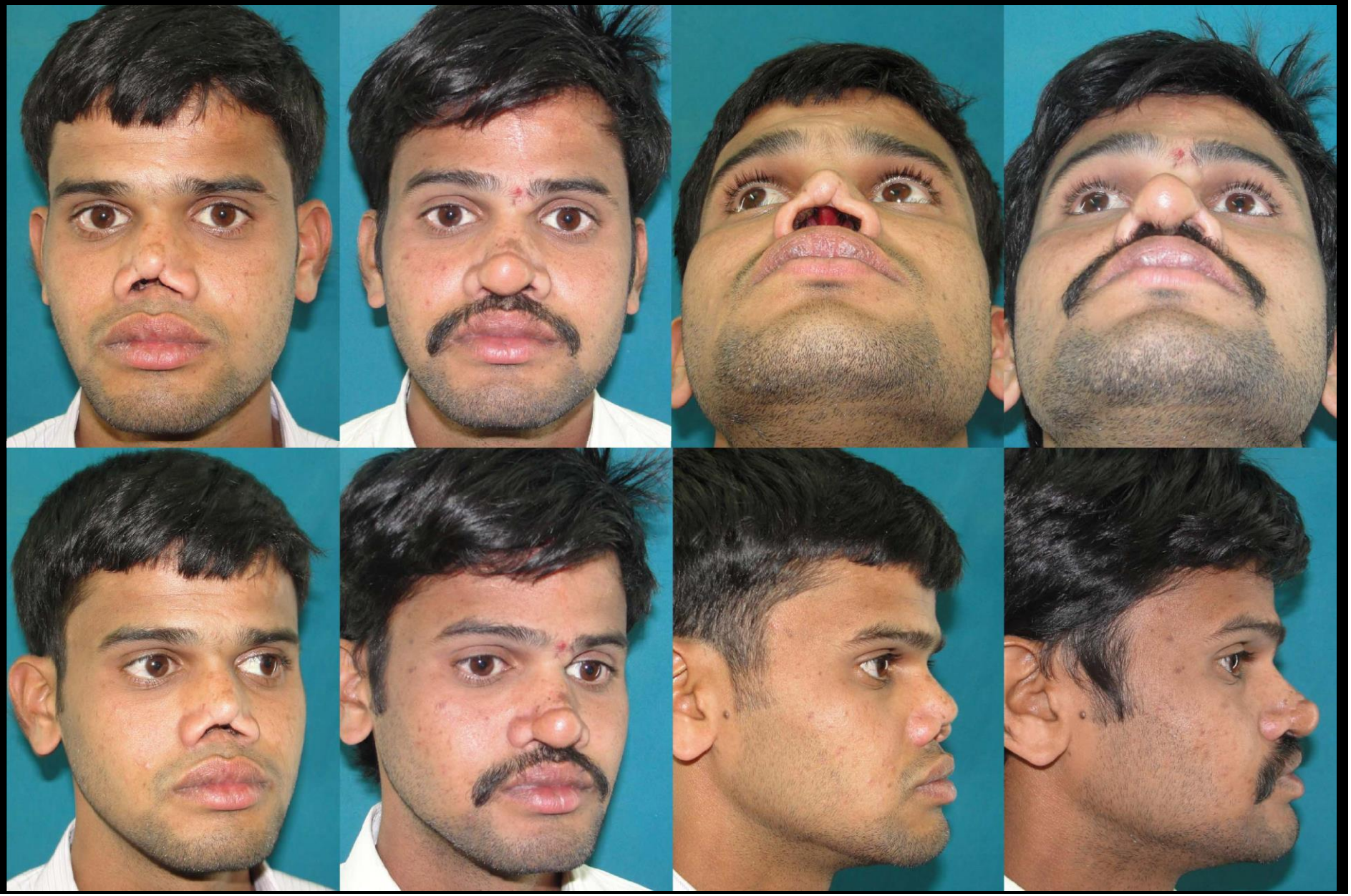

www.craniofacialinstitute.org

Grafting of Facial Skeleton

- Maxillary Complex
- Mandibular Complex
- Naso-orbital Complex
- Frontal Complex
- Ear

Grafting of Fronto-Nasal Complex

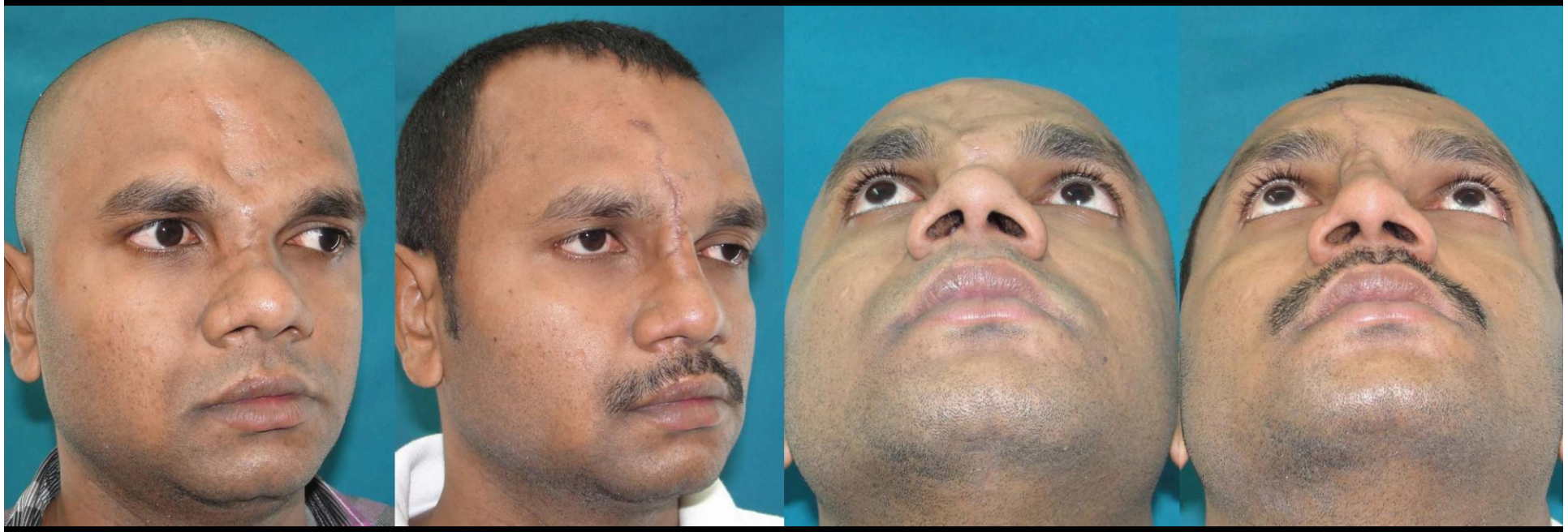

And the most challenging surgery of them all!!!

Ear Reconstruction

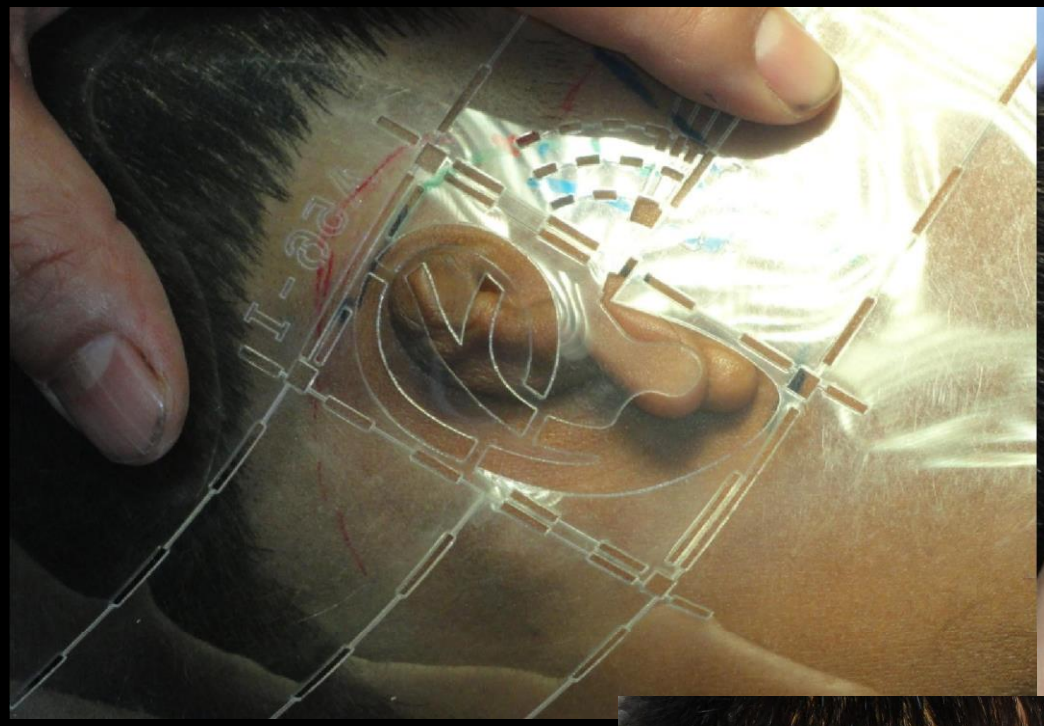

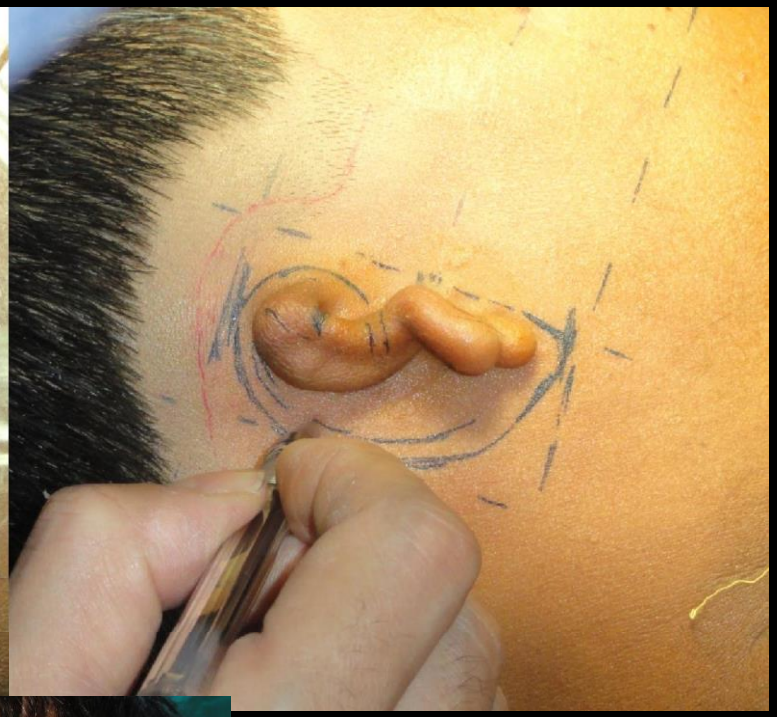

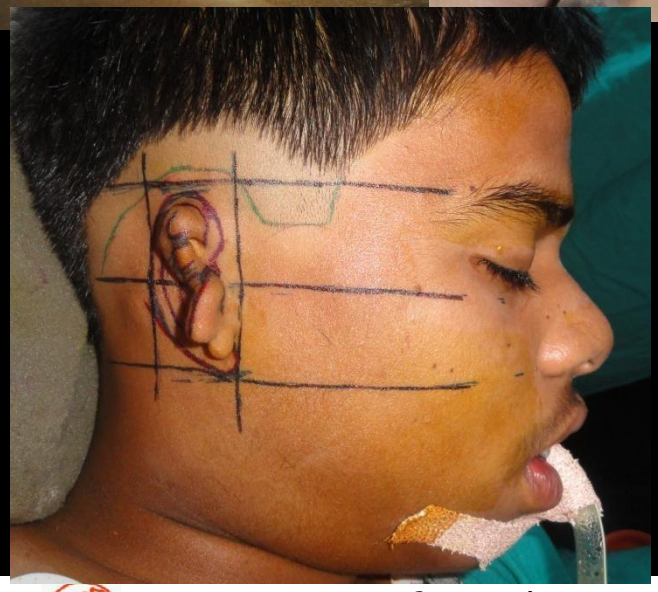

Bring the Smile Back

Thank You

www.craniofacialinstitute.org