

# MORPHO-FUNCTIONAL REPAIR OF CLEFT PALATE -EVIDENCE BASED

Prof. Dr. Dr. Srinivas Gosla Reddy

MBBS, MDS, FRCS (Edin.), FDSRCS (Edin), FDSRCS (Eng.), FDSRCPS (Glasg.), PhD

Dr. Rajgopal R. Reddy

MBBS, BDS, FDSRCPS (Glasg.), PhD

Dr. Ashish Fanan M.D.S.

Dr. Avni Pandey M.D.S.

GSR Institute of Craniofacial Surgery,  
Hyderabad India



[www.craniofacialinstitute.org](http://www.craniofacialinstitute.org)

# GSR Institute of Facial Plastic Surgery

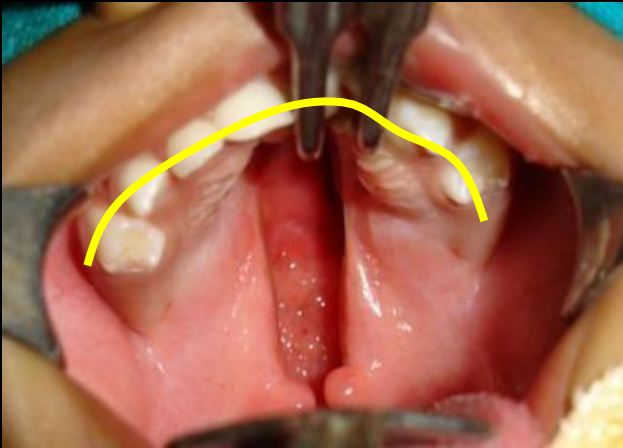


- Non-profit hospital established in 1996
- Dedicated Cleft & Craniofacial Centre of Excellence
- Presently 1,600 cleft and craniofacial surgeries are done every year
- 4 surgeons and 4 fellows with full support team
- More than 30,000 documented cleft & craniofacial surgeries have been performed since 1996
- 600 primary new born cleft children are registered every year

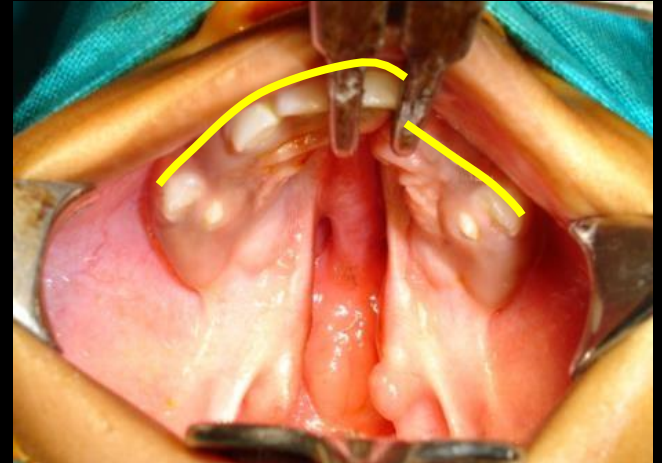


# Cleft palate variations

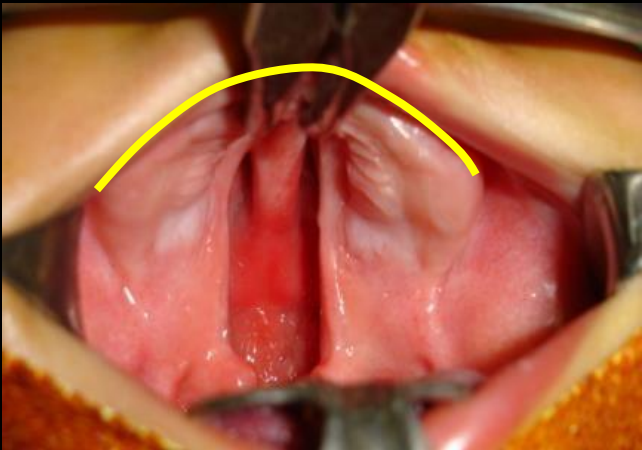
Cleft of hard and soft palate associated with cleft lip



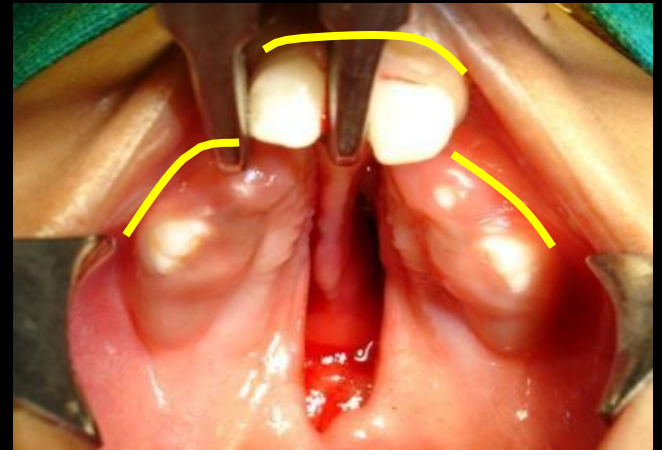
**Unilateral** complete cleft palate with palatal shelves at the same level anteriorly



**Unilateral** complete cleft palate with palatal shelves at the different levels anteriorly



**Bilateral** complete cleft palate with palatal shelves at the same level of the premaxilla anteriorly



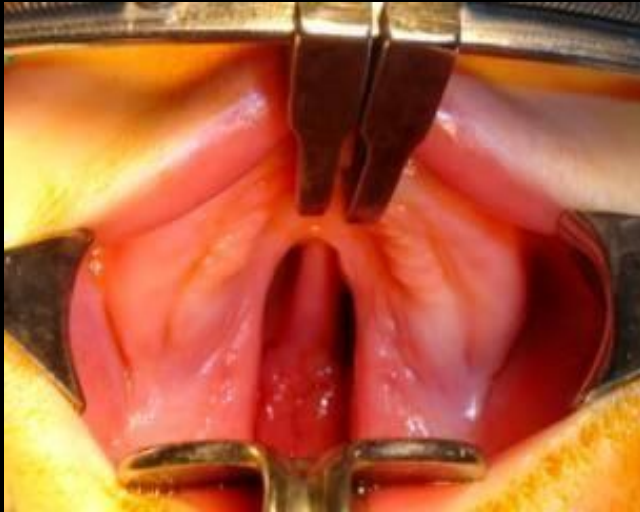**Bilateral** complete cleft with palatal shelves at different levels of the premaxilla anteriorly



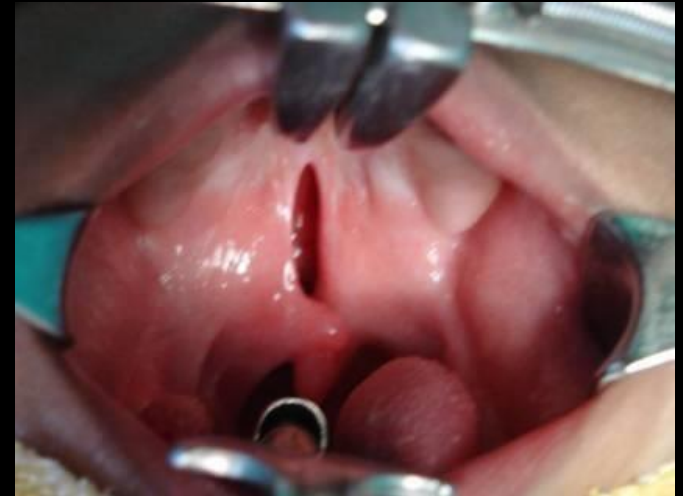

# Cleft palate variations

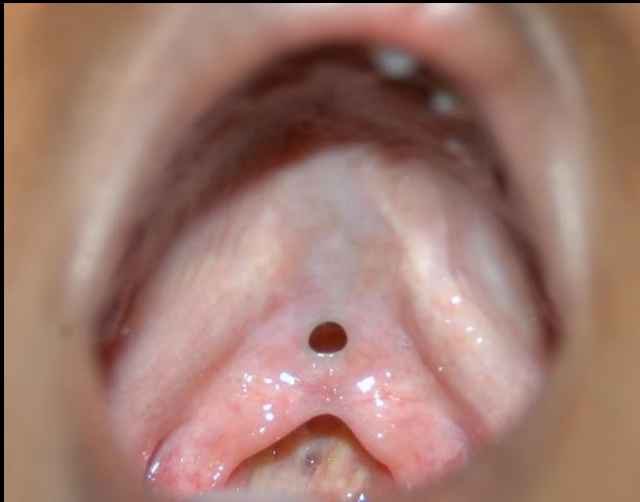## Isolated Cleft Palate



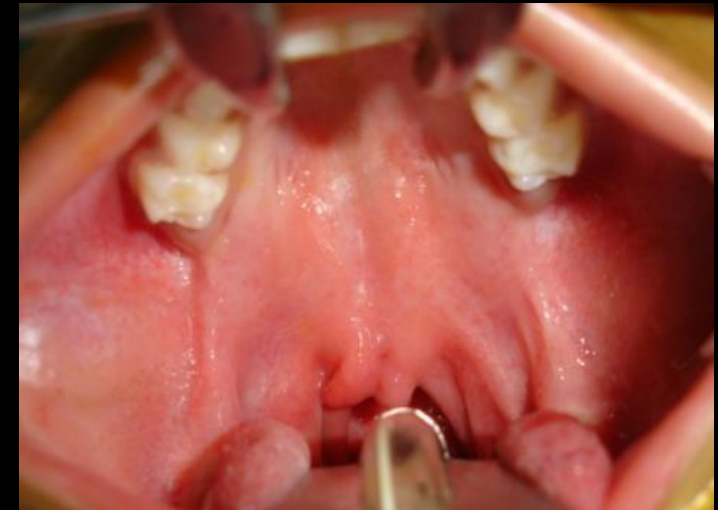Cleft of hard and soft palate



Cleft of soft palate



Submucous cleft palate



Bifid uvula



# Protocols Primary Cleft Palate Repair

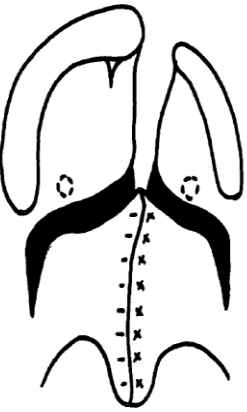
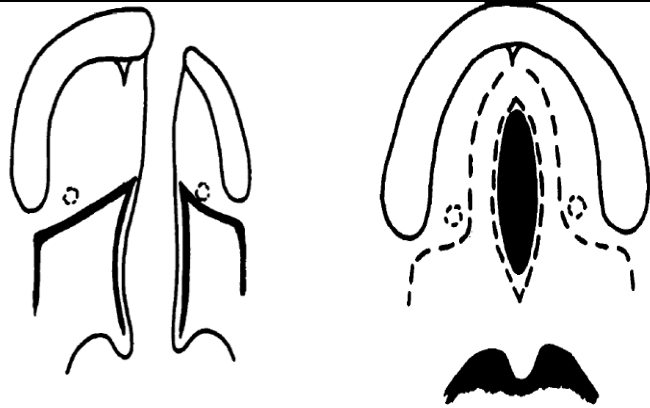
- 0- 6 months:-
  - a. Lip & Soft palate
  - b. Lip with Hard palate using Vomer flap
- 6 months-2 years:
  - Primary palate repair
  - One stage
    - Complete palate (9-14 months)
  - Two stage
    - Soft palate ( 6 - 12 months )
    - Hard Palate (13 -24 months )
- **Technique :-**
  - Bardach two flap technique
  - Von Langenback
  - Furlow
  - Delaires
  - Sommerlads
  - Morphofunctional




How do you decide  
which is the best way to repair the  
palate



# Cleft Palate Repair: Delaire



Stage I



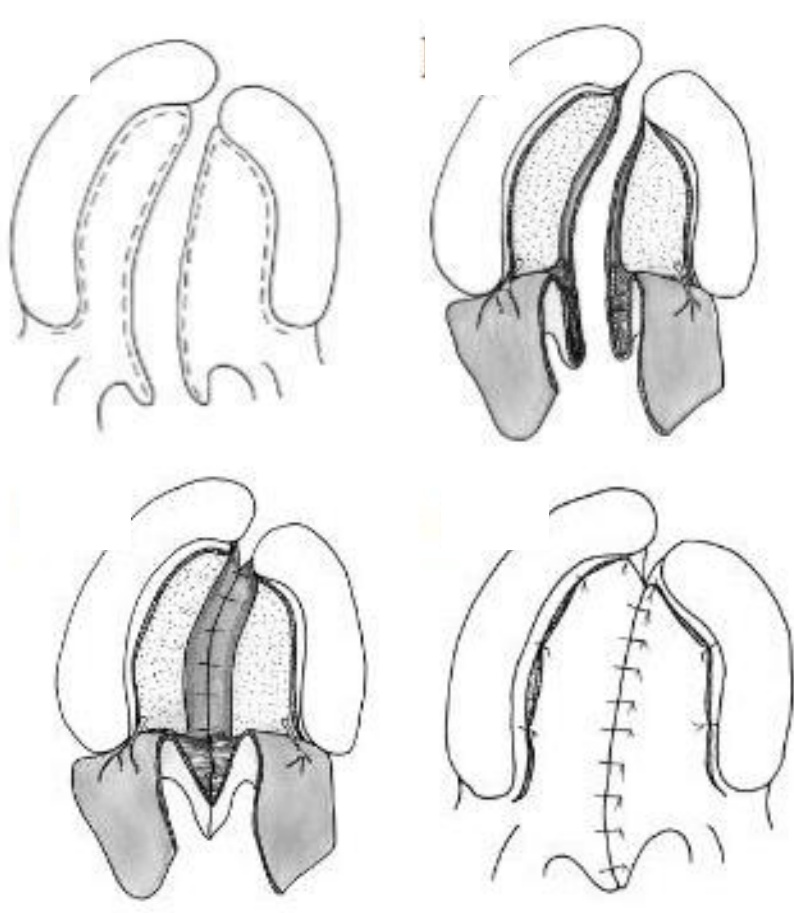
Stage II

- **Two stage Palatoplasty – Lip + Soft Palate [6 months]**
- Horizontal incision posterior to greater palatine vessels.
- **Advantages**
  - Encourages normal function of the soft palate and the tongue.
  - Facilitates **closure of the hard palate**.
  - Prevents arch collapse.
  - Good palatal lengthening, fewer hearing problems.
- **Disadvantages**
  - Two stage procedure.

Markus AF, Smith WP, Delaire J. Primary Closure of cleft palate: a functional approach. British Journal of Oral and Maxillofacial Surgery. 31:71-774.1993



# Cleft Palate Repair: Bardach



- The design of this flap is entirely dependent on the **greater palatine neurovascular pedicle** and it provides greater versatility to cover the cleft.
- **Advantages:-**
  - Complete closure of the entire palate in one stage.
  - Creation of more physiologic soft palate muscle sling and a layered closure technique.
- **Disadvantages:-**
  - Does not provide additional length to the repaired palate to allow normal speech production.

Bardach J. Two flap palatoplasty Bardach Technique. Operative Techniques in Plastic and Reconstructive Surgery. 2(4):211-214.1995





# Cleft Palate Repair: Sommerlad

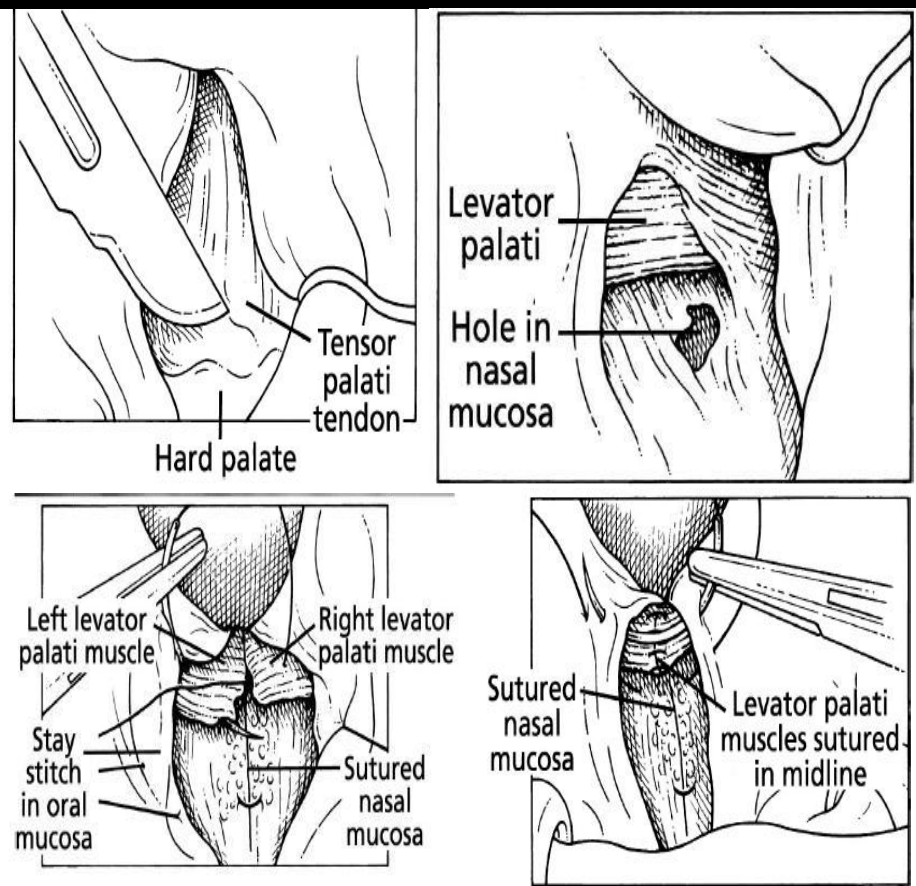
Radical retro positioning of the velar musculature and tensor tenotomy using an operating microscope to allow accurate levator muscle reconstruction.

## ➤ **Advantages:-**

- Non tension closure even in wider palates.
- Good speech outcomes.

## ➤ **Disadvantages:-**

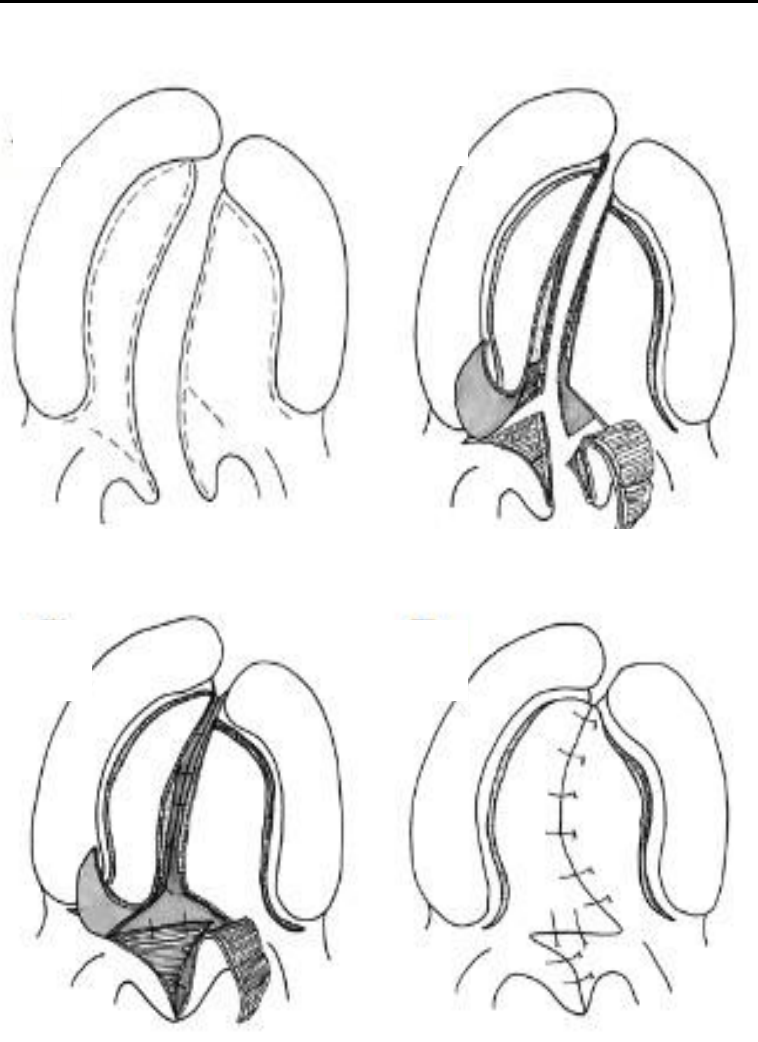
- Recurrent ear infections due to tensor tenotomy.
- High fistula rates due to radical muscle relieving from the nasal area.
- Loss of tautness of soft palate.



Sommerlad BC. A technique for cleft palate repair. *Plastic and Reconstructive Surgery*. 112(6):1542-1548.2003



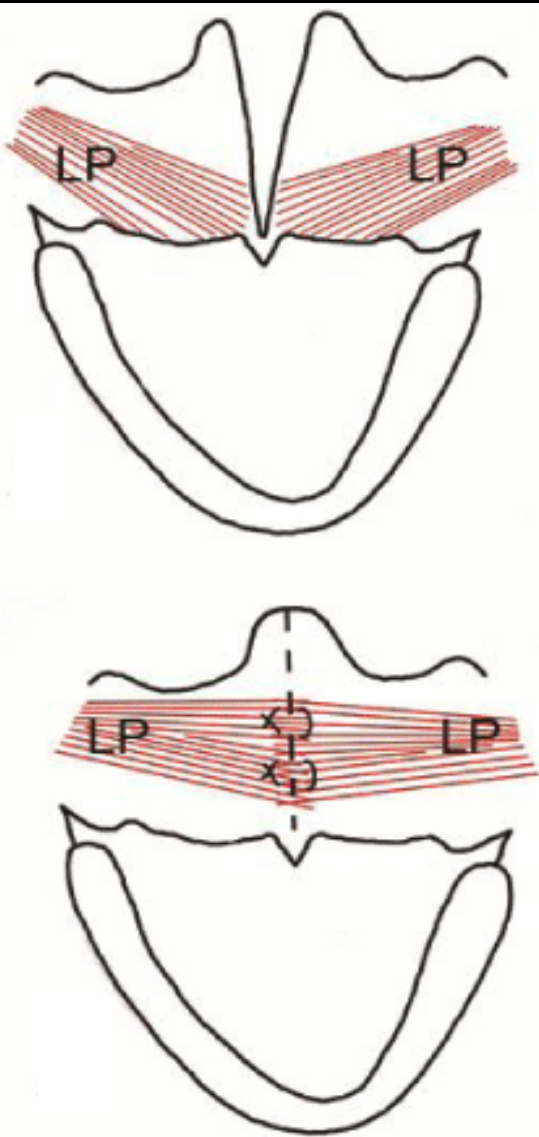
# Cleft Palate Repair: Furlow



- Alternating the reversing Z-plasties of the nasal and oral flaps and repositioning the levator veli palatini muscle within the posteriorly mobilized flaps.
- Effective for primary closure of a **submucous cleft palate** and secondary correction of marginal velopharyngeal insufficiency.
- **Advantages:-**
  - No need to raise large mucoperiosteal flaps from the hard palate.
  - The soft palate can be lengthened.[Good speech outcome]
- **Disadvantages:-**
  - Non anatomical palatal closure
  - Ignores musculus uvulae
  - Difficult to close wider clefts
  - Large raw area - needs to be covered with buccal flap.



# Intervelar Veloplasty



- Dissection of the Levator Palati from the posterior border of the hard palate, nasal and oral mucosa and posterior repositioning.
- Suturing of the muscle with that of the opposite side for the reconstruction of the Levator sling.
- **Sommerlad** dissects the levator palatini belly separately and sutures independently as the Levator is the dominant muscle for elevation of the soft palate during speech. Also tensor tenotomy is performed.
- **Court Cutting** transects the Tensor Palati and to keep its function intact, the cut end is transfixed with the hook of the hamulus.





Contents lists available at ScienceDirect

## Journal of Cranio-Maxillo-Facial Surgery

journal homepage: [www.jcmfs.com](http://www.jcmfs.com)



### Maxillofacial growth and speech outcome after one-stage or two-stage palatoplasty in unilateral cleft lip and palate. A systematic review

Rajgopal R. Reddy <sup>a,\*</sup>, Srinivas Gosla Reddy <sup>a</sup>, Anitha Vaidhyanathan <sup>a</sup>, Stefaan J. Bergé <sup>b</sup>, Anne Marie Kuijpers-Jagtman <sup>c</sup>

<sup>a</sup> G.S.R. Hospital (Head: Prof. S. Gosla Reddy), Institute of Cranio-Maxillofacial and Facial Plastic Surgery, Vinay Nagar Colony, Saidabad, Hyderabad, India

<sup>b</sup> Department of Cranio-maxillofacial Surgery (Head: Prof. S.J. Bergé), Radboud University Medical Center, Nijmegen, The Netherlands

<sup>c</sup> Department of Orthodontics (Prof. Emeritus: A.M. Kuijpers-Jagtman), Radboud University Medical Center, Nijmegen, The Netherlands

**Aim of this systematic review** was to investigate the **relationship Between** the number of surgical procedures performed to repair the cleft palate and maxillofacial **Growth, speech and fistula formation** in non-syndromic patients with unilateral cleft lip and palate.



- Search Engine / Database
  - Pubmed
  - Cochrane Library
  - EMBASE
  - Scopus
  - CINAHL

### Conclusion:-

This systematic review shows **inconclusive evidence** for the relative effects of one-stage or two stage palate repair on maxillofacial growth, speech and fistula rates in patients with unilateral cleft lip and palate. Further, well-designed, randomized controlled studies, especially targeting long-term results, are required.

R.R. Reddy et al. / Journal of Cranio-Maxillo-Facial Surgery (2017) 1-9





## Effect of One-Stage versus Two-Stage Palatoplasty on Hypernasality and Fistula Formation in Children with Complete Unilateral Cleft Lip and Palate: A Randomized Controlled Trial

Rajgopal R. Reddy,  
M.B.B.S., B.D.S.,  
F.D.S.R.C.P.S. (Glasg.)  
Srinivas Gosla Reddy,  
M.B.B.S., M.D.S.,  
F.D.S.R.C.S. (Eng.),  
F.D.S.R.C.S. (Edin.), Ph.D.  
Anusha Chilakalapudi,  
M.Sc.  
Swapnika Kokali, M.Sc.  
Ewald M. Bronkhorst, Ph.D.  
Ann W. Kummer, Ph.D.  
Stefaan J. Bergé, M.D.,  
D.D.S., Ph.D.  
Anne Marie Kuipers-  
Jagtman, D.D.S., Ph.D.,  
F.D.S.R.C.S.

Vinay Nagar Colony, Saidabad,  
Hyderabad, India; Nijmegen,  
The Netherlands; and Cincinnati, Ohio



**Background:** Is one-stage or two-stage palatoplasty more effective for preventing fistula formation and hypernasality in patients with complete unilateral cleft lip and palate?

**Methods:** This parallel blocked randomized controlled trial included 100 patients with nonsyndromic complete unilateral cleft lip and palate with a repaired cleft lip, divided into two equal groups. Group A had one-stage palatoplasty patients at age 12 to 13 months while group B had two-stage palatoplasty patients with soft palatoplasty at age 12 to 13 months and hard palatoplasty at age 24 to 25 months. Presence of a fistula was tested clinically at 3 years and speech was tested using nasometry and perceptual analyses at 6 years. Group C consisted of noncleft controls ( $n = 20$ , age 6 years) for speech using nasometry. Fistula rates, hypernasality ratings, and nasalance scores were compared between groups A and B. Nasometry recordings of groups A and B were compared with control group C.

**Results:** There was no difference in fistula rates between groups A and B ( $p = 0.409$ ; 95 percent CI, 0.365 to 11.9). Mean nasalance scores of group A showed higher nasalance than group B ( $p = 0.006$ ; 95 percent CI, 1.16 to 6.53). Perceptual analysis showed no difference between groups A and B ( $p = 0.837$  and  $p = 1.000$ ). Group A showed higher mean nasalance than group C ( $p = 0.837$  and  $p = 1.000$ ), whereas group B showed no difference ( $p = 0.088$ ; 95 percent CI, -0.14 to 2.02).

**Conclusions:** There was no difference in fistula rates between groups. Nasalance was slightly higher in patients in the one-stage palatoplasty group than two-stage palatoplasty group, but the difference was not clinically significant. (*Plast. Reconstr. Surg.* 142: 42e, 2018.)

**CLINICAL QUESTION/LEVEL OF EVIDENCE:** Therapeutic, II.

•Parallel blocked randomized controlled trial of **100 consecutive children.**

**Group A**

One stage repair  
(**Complete palate** age **12 months**)

**Group B**

Two stage repair  
(**Soft Palate** at age **12 months**,  
**Hard Palate** at age **24 months**)

**Group C**

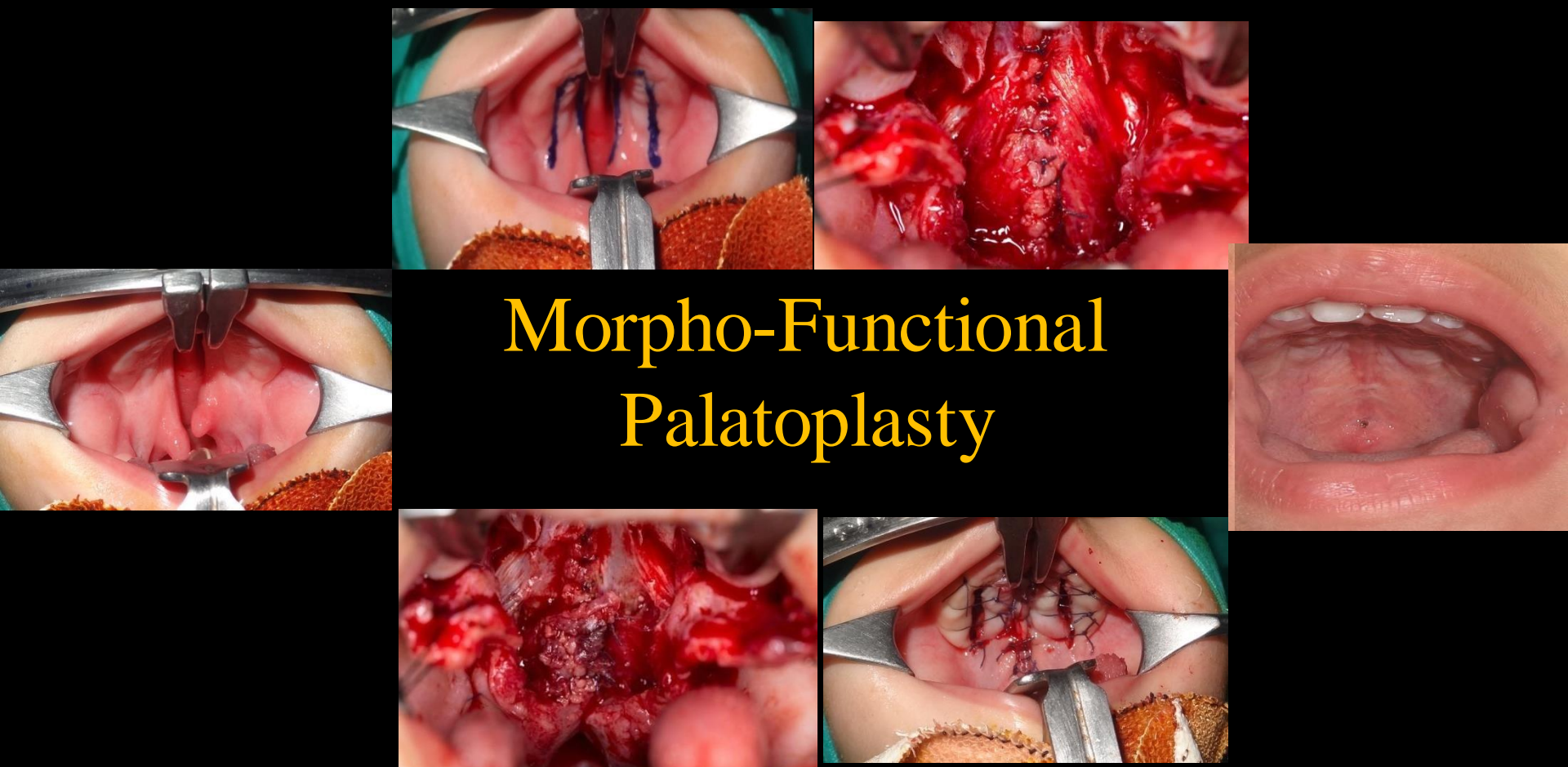Children with unaffected  
palates ( **Controlled Group**)

### Conclusion:-

There was **no difference** in **fistula rates** between groups.

- Although the **mean nasalance** of the **one-stage group** was a **little higher** than the **two-stage group** and the difference was statistically significant for speech outcome.
- The difference **may not be clinically** relevant as the score was still in the borderline/normal range.
- It was **concluded** that **One Stage palatoplasty** has **better outcome** than **Two stage palatoplasty** on hypernasality and fistula formation.





# Morpho-Functional Palatoplasty



# Protocols for Morphofunctional Repair of Cleft Palate

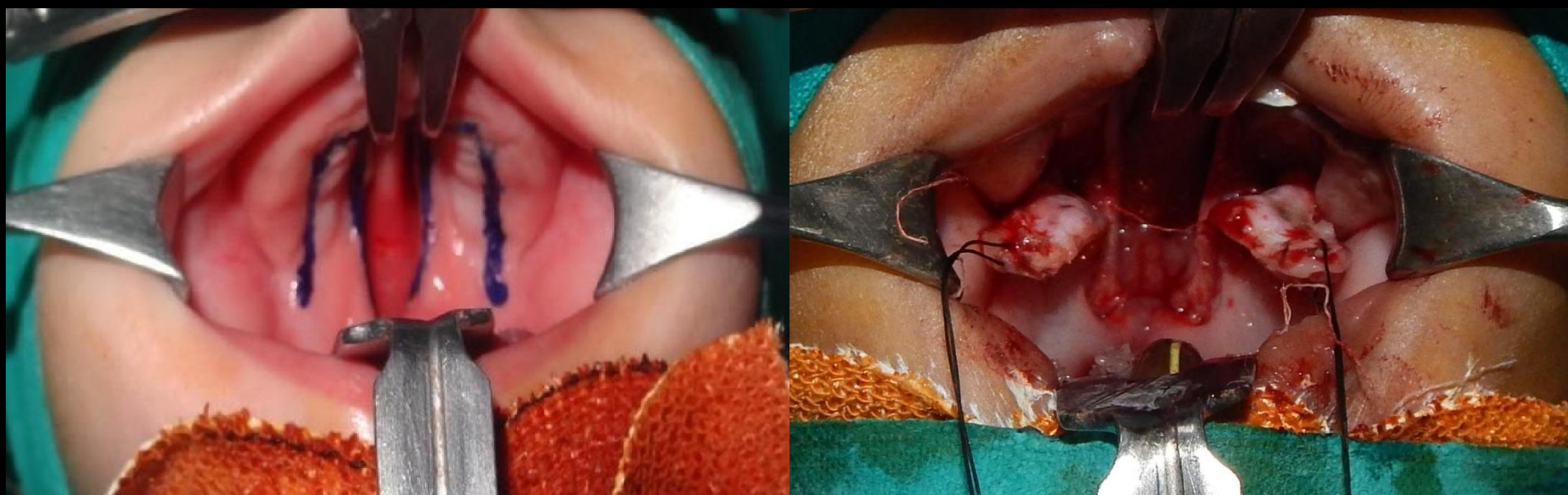
- Age :- 12 months
- Surgery :- One stage
- Technique:- Two flap with optimal muscle dissection
- Speech :-
  - Pre surgical :-
    - Parent Counselling
  - Post surgical:-
    - Screening for Language Development & Counselling
    - Demonstration of Language Stimulation
    - Speech Assessment
    - Guidance & Demonstration for Speech Correction
- VPI : - Modified Furlows 'Z' Plasty with Levator Myoplasty
  - Pharyngeal flap
  - Combination of both





# Morphofunctional Cleft Palate Repair

Two flap technique with optimal muscle dissection



Medial and Lateral incisions to expose the soft palate musculature and mobilize the hard palate flaps.

Gosla Reddy, S. (2017). Morphofunctional palatoplasty: evidence based recommendations. International Journal of Oral and Maxillofacial Surgery. 46. 21. 10.1016/j.ijom.2017.02.077.

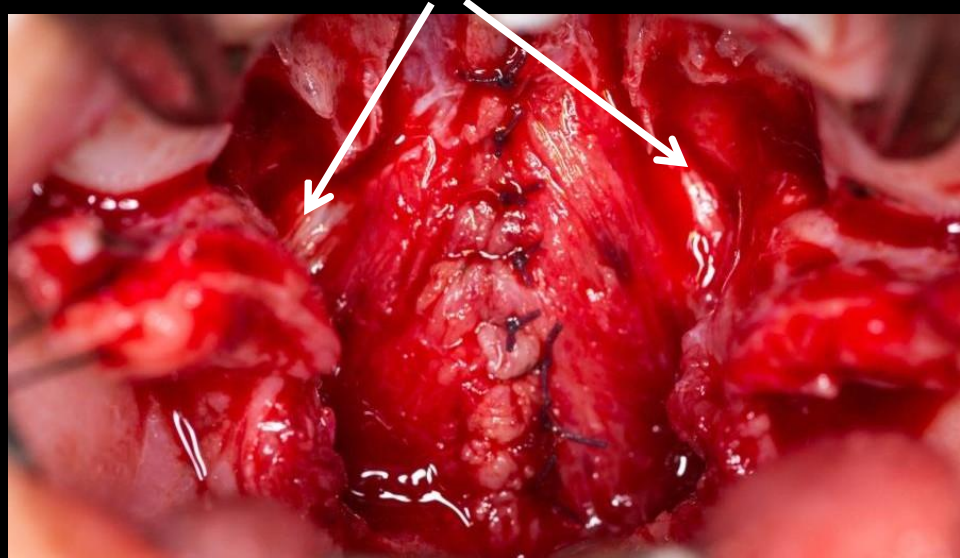


[www.craniofacialinstitute.org](http://www.craniofacialinstitute.org)

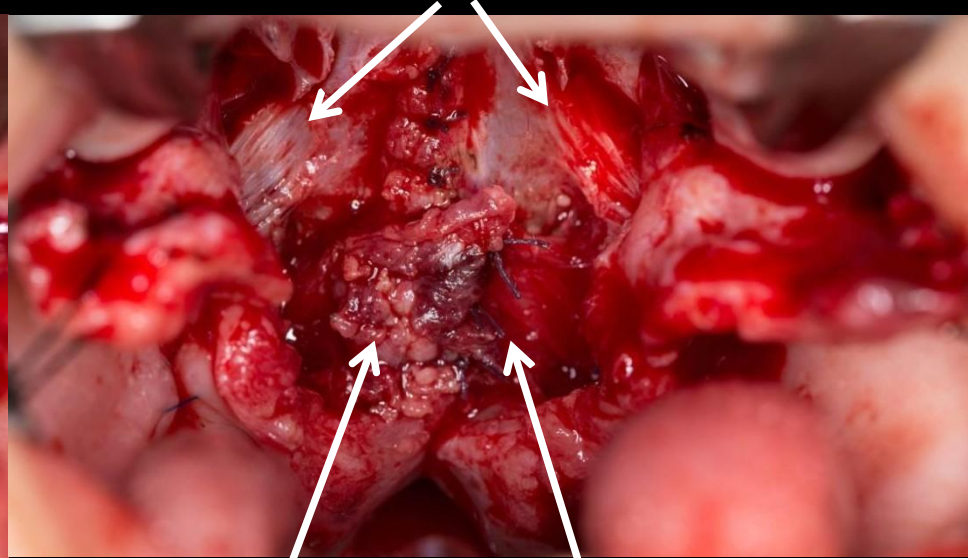
# Two flap technique with optimal muscle dissection

## Soft Palate Muscle Dissection

Tensor veli Palatini



Tensor veli Palatini



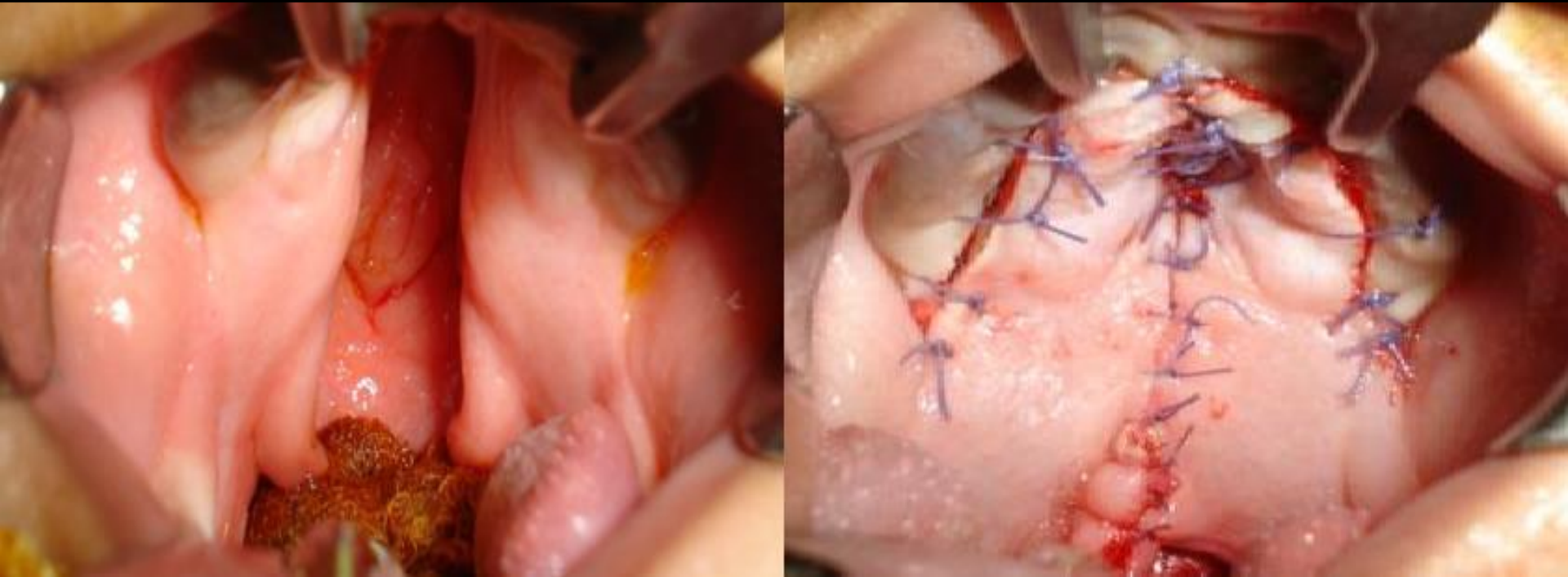- Optimal muscle dissection
- Dissection only of Levator muscle bundle (Levator Myoplasty)
- Tensor tendon is not dissected

Gosla Reddy, S. (2017). Morphofunctional palatoplasty: evidence based recommendations. International Journal of Oral and Maxillofacial Surgery. 46. 21. 10.1016/j.ijom.2017.02.077.





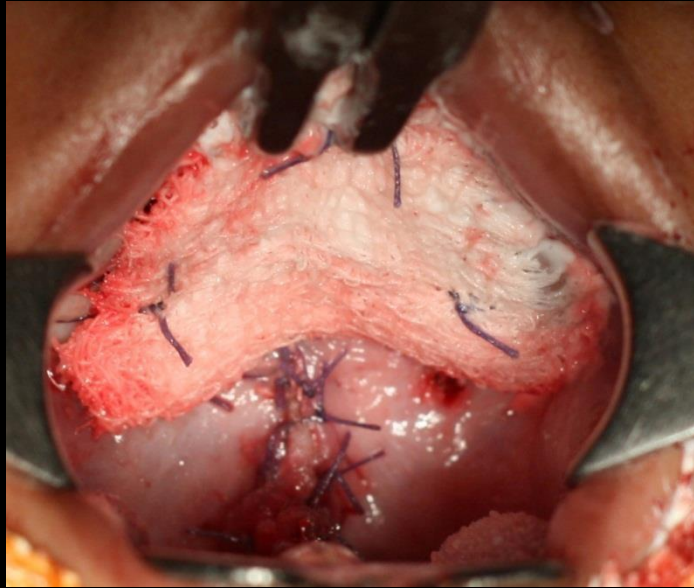
## Two flap technique with optimal muscle dissection



Gosla Reddy, S. (2017). Morphofunctional palatoplasty: evidence based recommendations. International Journal of Oral and Maxillofacial Surgery. 46. 21. 10.1016/j.ijom.2017.02.077.



# Postoperative Management



- Postoperative antibiotic dressing for 5 days
- Postoperative feeding: **Clean, Clear and Filtered fluids for 1 month.**
- Plenty of oral fluids.
- Parent counselling.



# Common Sequele

- Formation of Fistula
- Velopharyngeal Insufficiency



# Common Sequele

- Formation of Fistula
- Velopharyngeal Insufficiency





# Placement of an antibiotic oral pack on the hard palate after primary cleft palatoplasty: a randomized controlled trial into the effect on fistula rates

Rajgopal R. Reddy<sup>1,2,3</sup> • Srinivas Gosla Reddy<sup>1</sup> • Bhavya Banala<sup>4</sup> • Ewald M. Bronkhorst<sup>5</sup> • Ann W. Kummer<sup>6</sup> • Anne Marie Kuijpers-Jagtman<sup>7</sup> • Stefaan J. Bergé<sup>8</sup>

Received: 18 October 2016 / Accepted: 21 November 2017  
© The Author(s) 2017. This article is an open access publication

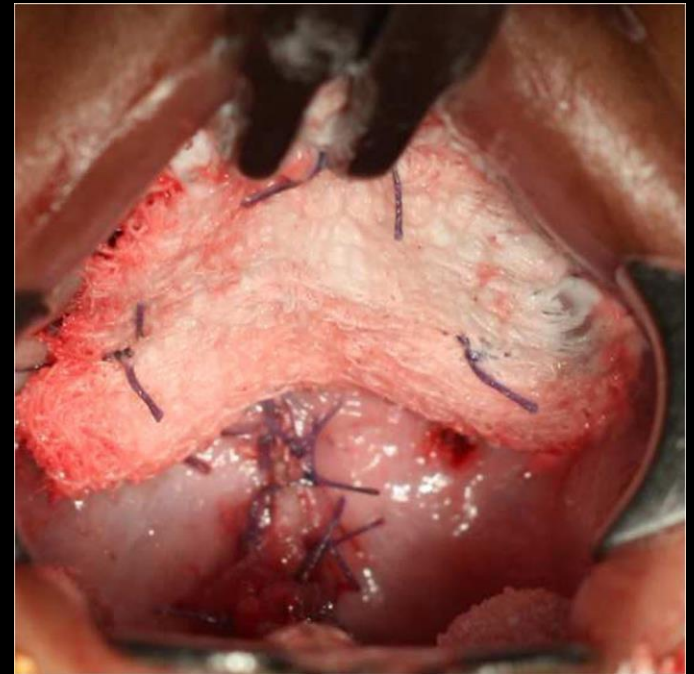
The **objective** of this study is to determine whether placement of an antibiotic oral pack on the hard palate **reduces fistula rates** after primary cleft palatoplasty





- 100 Patients in each group
- Technique Used:-

Bardach two flap with levator myoplasty keeping tensor tendon intact.
- **Group A** :-
  - Oral pack placed on the hard palate for 5 days postop
  - 2 % patients had fistula
- **Group B** :-
  - Without Oral Pack
  - 21 % patients had fistula
- Follow-up period :- 6 months
- Oral pack made of **Sterile cotton gauze soaked in framycetin sulfate** antibiotic cream (Soframycin Skin Cream, Sanofi India Limited, India) for 5 days postoperatively



Rajgopal R. Reddy & Srinivas Gosla Reddy , Clinical Oral Investigations, 2017





# Placement of an antibiotic oral pack on the hard palate after primary cleft palatoplasty: a randomized controlled trial into the effect on fistula rates

Rajgopal R. Reddy<sup>1,2,3</sup> • Srinivas Gosla Reddy<sup>1</sup> • Bhavya Banala<sup>4</sup> • Ewald M. Bronkhorst<sup>5</sup> • Ann W. Kummer<sup>6</sup> • Anne Marie Kuijpers-Jagtman<sup>7</sup> • Stefaan J. Bergé<sup>8</sup>

Received: 18 October 2016 / Accepted: 21 November 2017  
© The Author(s) 2017. This article is an open access publication

## Conclusion:-

The findings of this study provide evidence that the **rate of fistula formation** after primary palatoplasty is significantly **reduced if a pack** soaked with antibiotic cream is **placed on the palate** postoperatively **for 5 days**.



CLINICAL PAPER

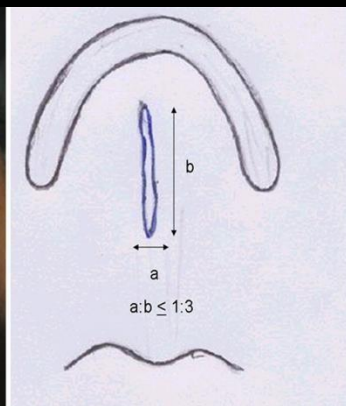
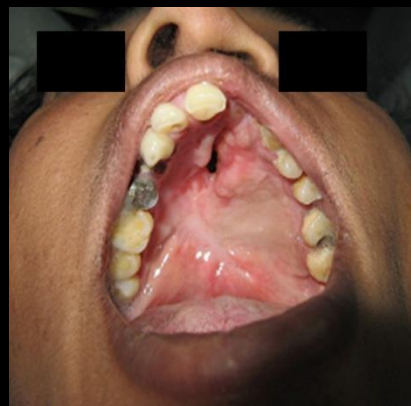# Palatal Fistulae: A Comprehensive Classification and Difficulty Index

Sunil Richardson • Nisheet A. Agni

Received: 23 July 2012 / Accepted: 15 May 2013 / Published online: 26 May 2013  
© Association of Oral and Maxillofacial Surgeons of India 2013

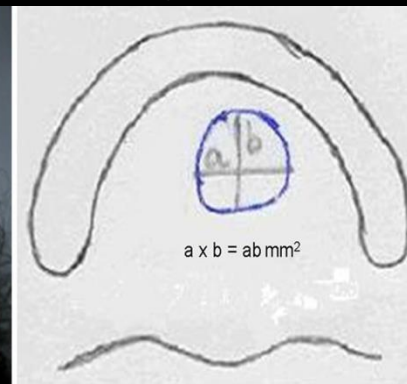
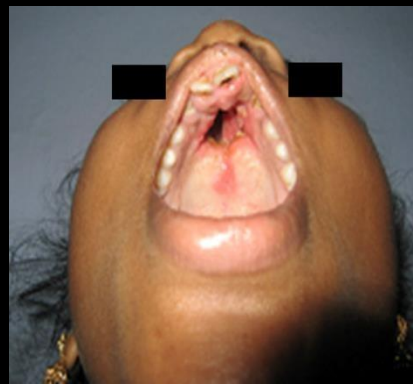(A) Based on type,

- Longitudinal



- Transverse fistulae

- small - medium - large

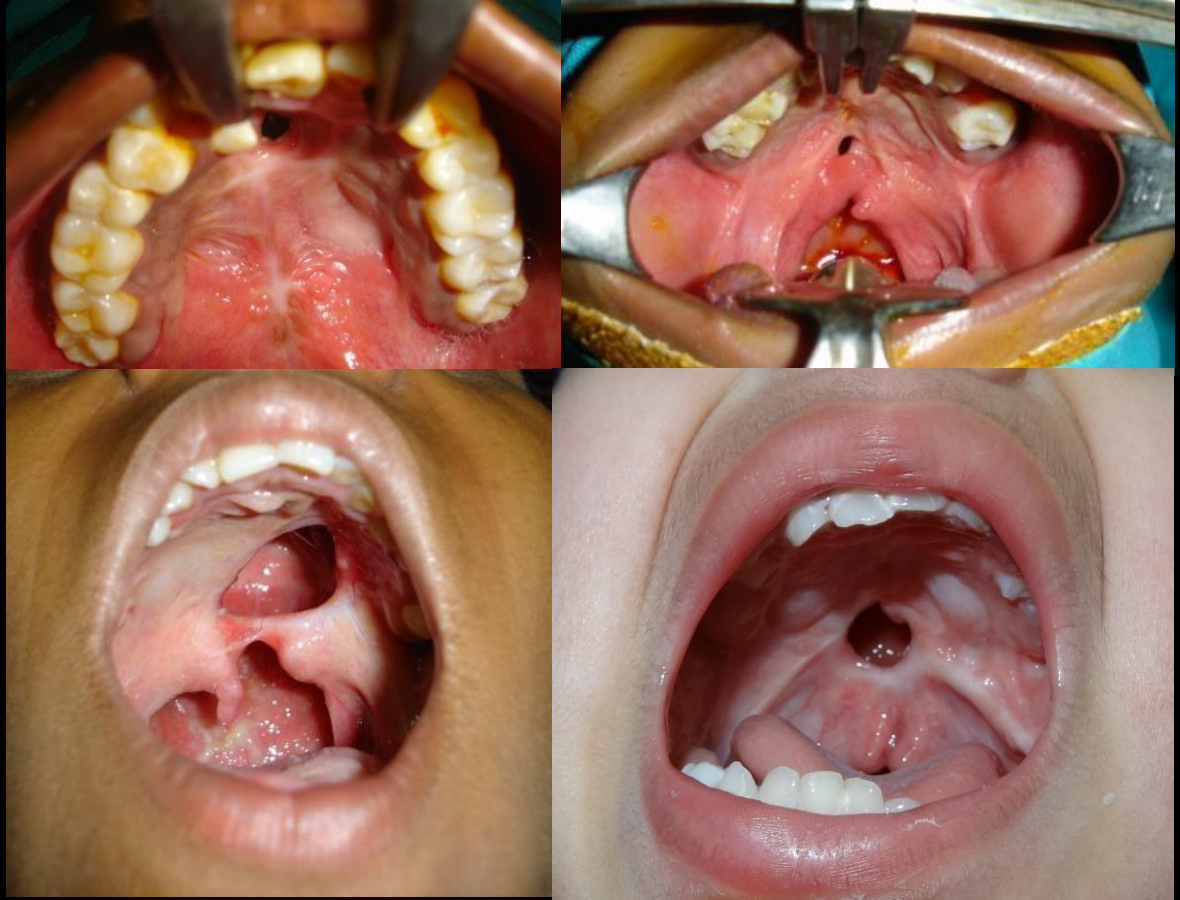


**(B) Based on site**

**1. Hard palate**

- (a) Anterior
- (b) Middle
- (c) Posterior

**2. Soft palate and Uvula**



**Factors affecting success:**

- 1. **Site** of Fistula.
- 2. **Size** of Fistula
- 3. **Degree of scarring** of palatal tissues (no. of previous procedures on palate)



# **Treatment modalities for surgical management of anterior palatal fistula: Comparison of various techniques, their outcomes, and the factors governing treatment plan: A retrospective study**

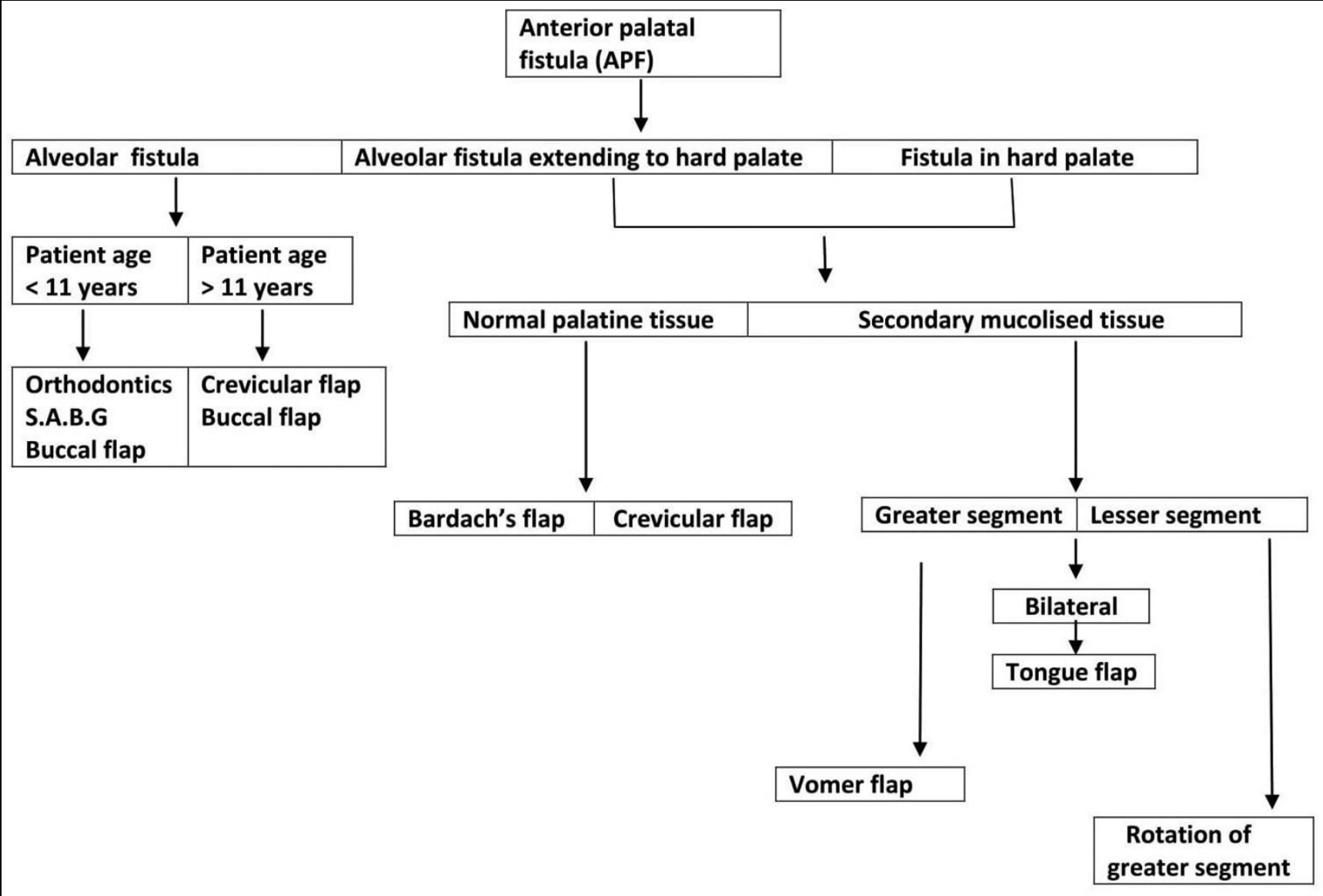
Krishnamurthy Bonanthaya<sup>1,2</sup>, Pritham Shetty<sup>1,2</sup>, Abhimanyu Sharma<sup>3</sup>, Jyoti Ahlawat<sup>4</sup>, Deepak Passi<sup>3</sup>, Mahinder Singh<sup>5</sup>

National Journal of Maxillofacial Surgery | Volume 7 | Issue 2 | July-December 2016 |

---



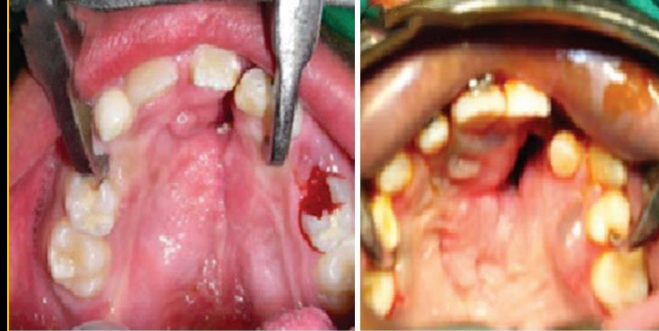



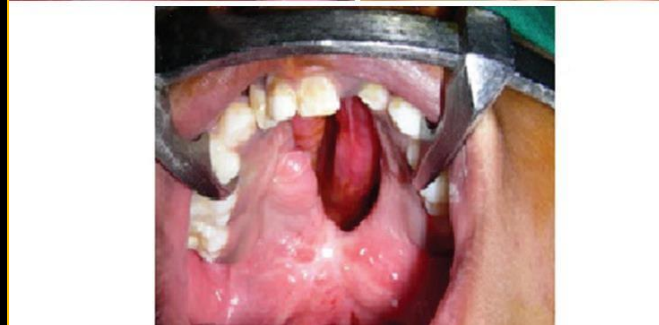Bonanthaya, et al.: Surgical treatment strategies for management of anterior palatal fistula, National Journal of Maxillofacial Surgery | Volume 7 | Issue 2 | July-December 2016



(a) Alveolar fistula

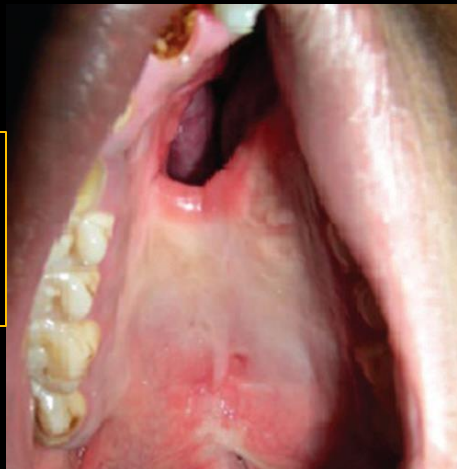

(b) Fistula extending to hard palate

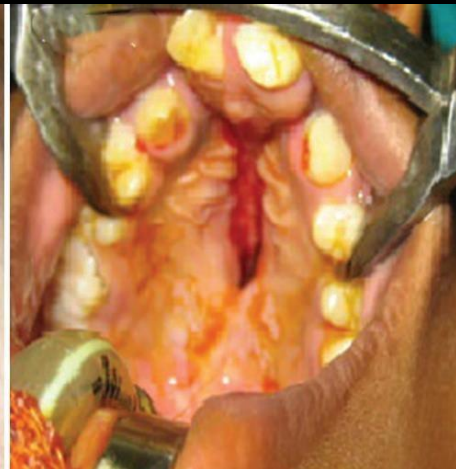

(c) Fistula in hard palate

(a) Fistula with secondary mucolized tissue.

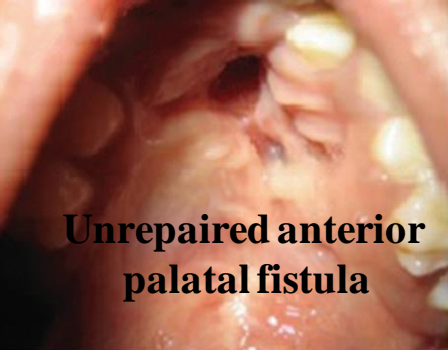

(b) Normal anatomical tissue

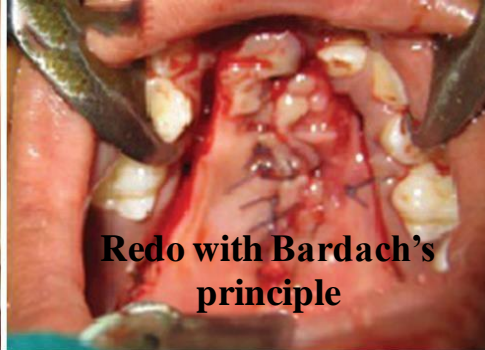

Bonanthaya, et al.: Surgical treatment strategies for management of anterior palatal fistula, National Journal of Maxillofacial Surgery | Volume 7 | Issue 2 | July-December 2016

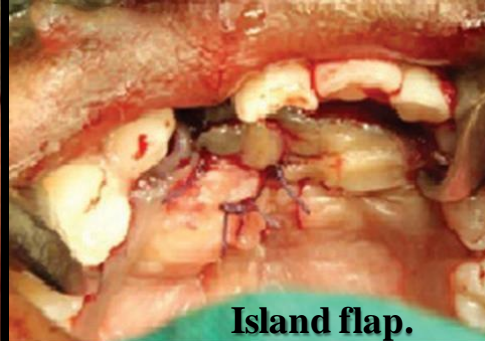



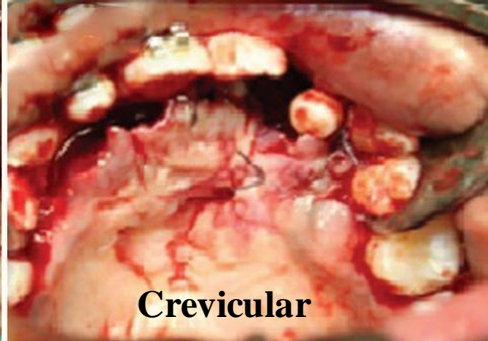
**Unrepaired anterior palatal fistula**



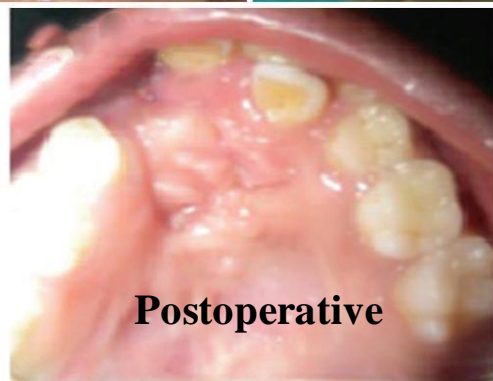**Redo with Bardach's principle**



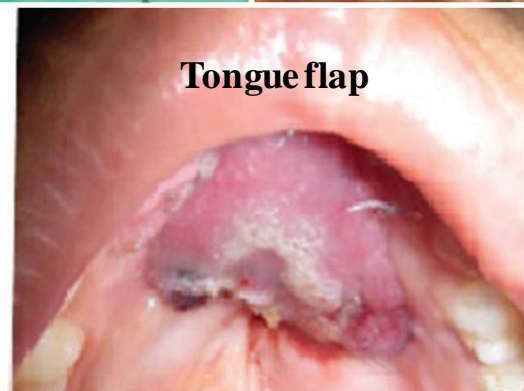**Island flap.**



**Crevicular**



**Postoperative**

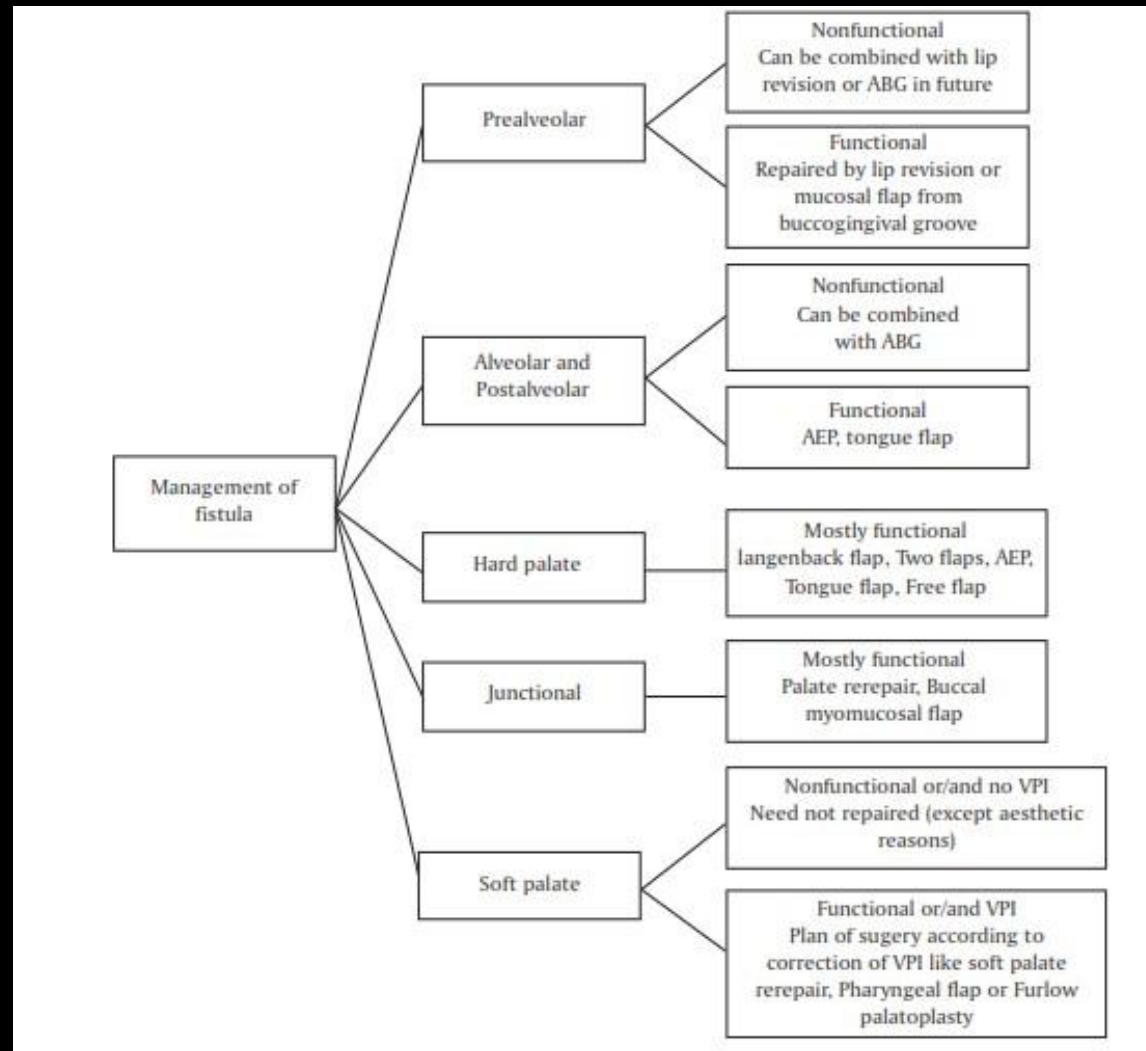


**Tongue flap**

Bonanthaya, et al.: Surgical treatment strategies for management of anterior palatal fistula, National Journal of Maxillofacial Surgery | Volume 7 | Issue 2 | July-December 2016



# Algorithm for the management of palatal fistula

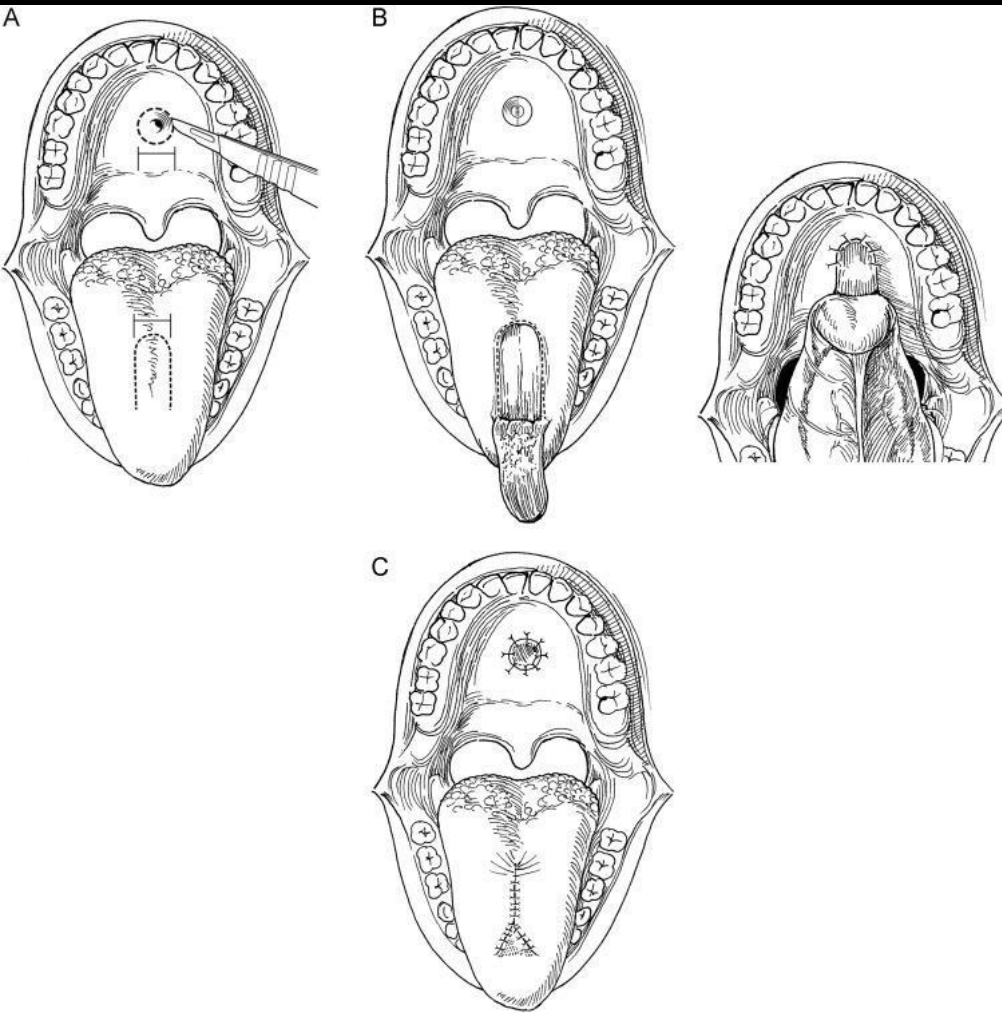


Murthy J. Descriptive study of management of palatal fistula in one hundred and ninety-four cleft individuals. Indian J Plast Surg. 2011 Jan;44(1):41-6. doi: 10.4103/0970-0358.81447.



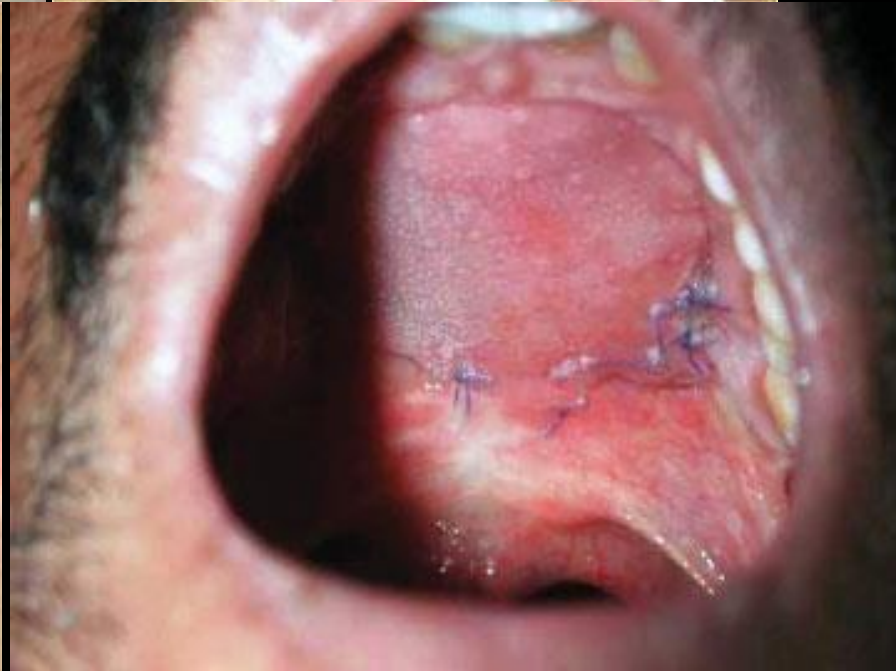
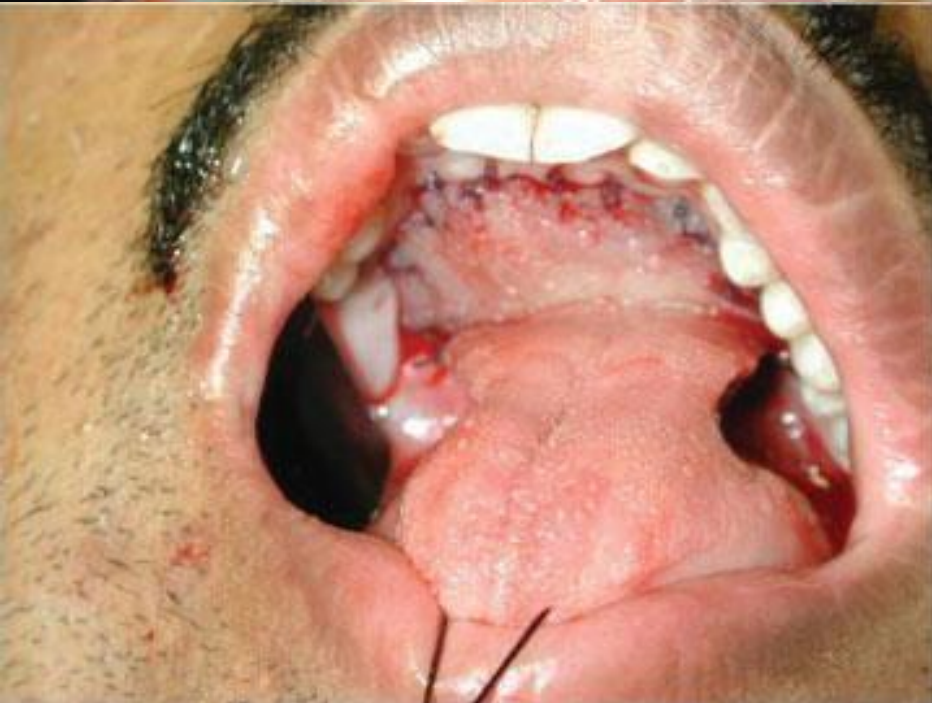
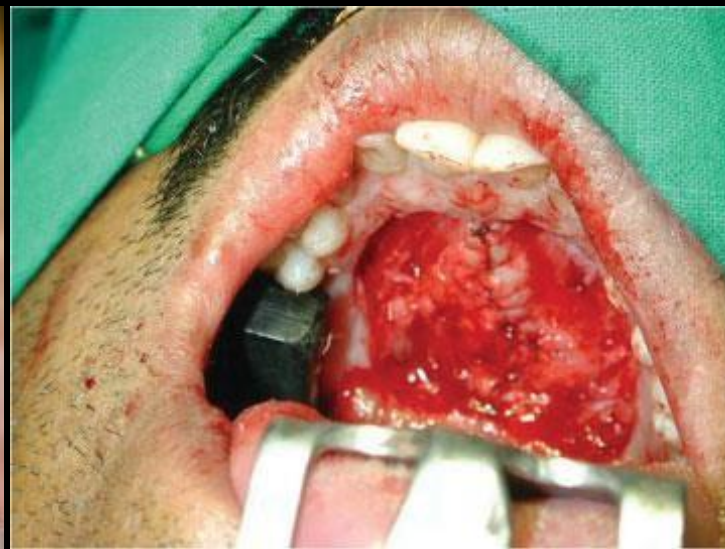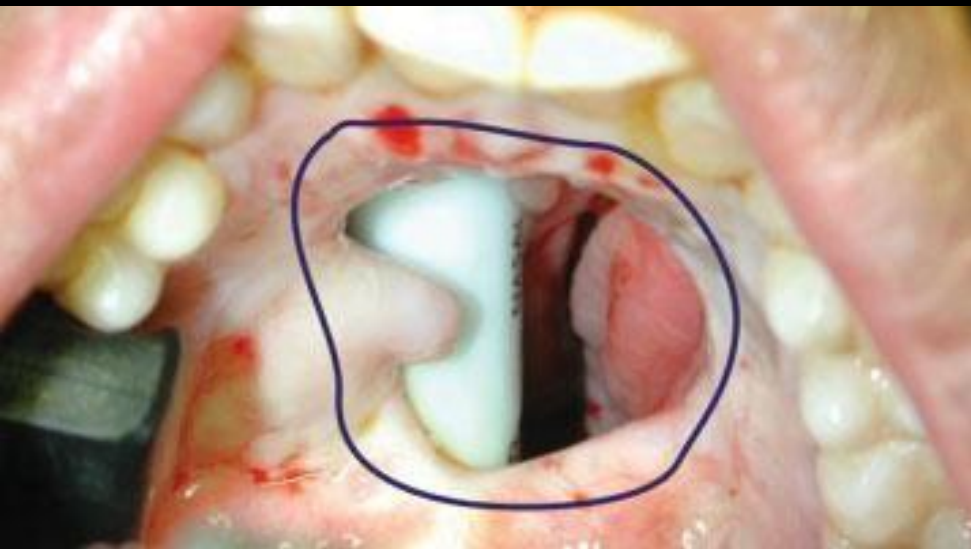# Tongue Flap



- **Guerrero-Santos and Altamirano**, were the first to report on the use of tongue flaps for palatal defect closure.
- The tongue flap is easy and reproducible with excellent esthetical and functional results.
- **Advantages:** The advantages are the use of adjacent tissue, the excellent blood supply and the low morbidity in donor site.
- **Disadvantage:** Inability in swallowing and speech until depedicling of the flap and in some cases the attachment of the flap can be lost due to traction.



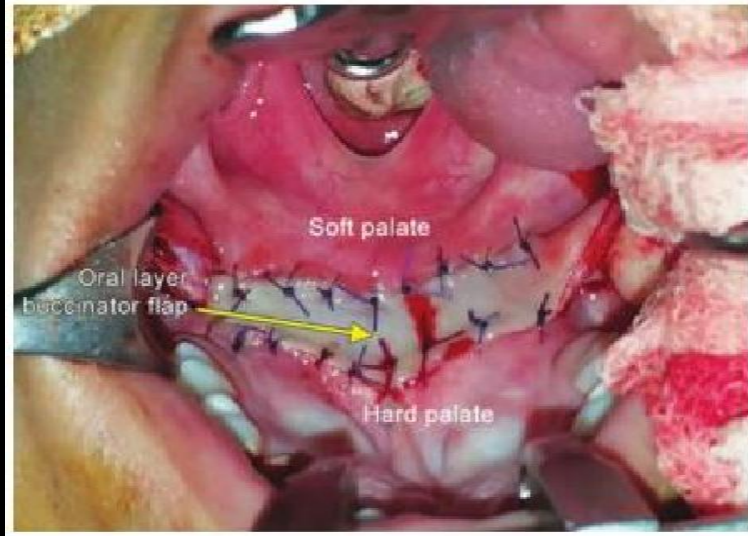
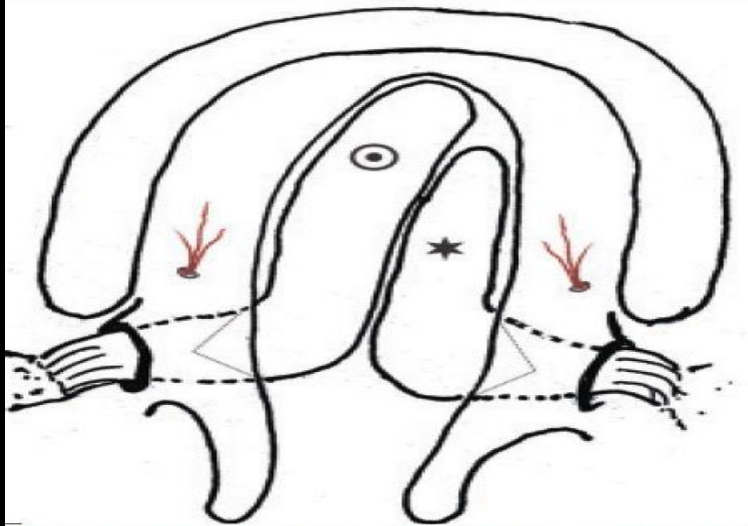


Source :- Internet





# Buccal Myomucosal Flap



- BMMF is a vascular and dependable flap.
- Vascular supply of the flap is consistent and profuse.
- The buccinator myomucosal flap is effective in reducing/eliminating hypernasality in patients with cleft palate and velopharyngeal insufficiency.
- **Advantages:**
  - Flap congestion is occasional and necrosis is rare.
  - It tolerates stretching, folding, and twisting.
- **Disadvantages:**
  - Fibrosis. Secondary healing.
  - Parotid duct orifice injury.

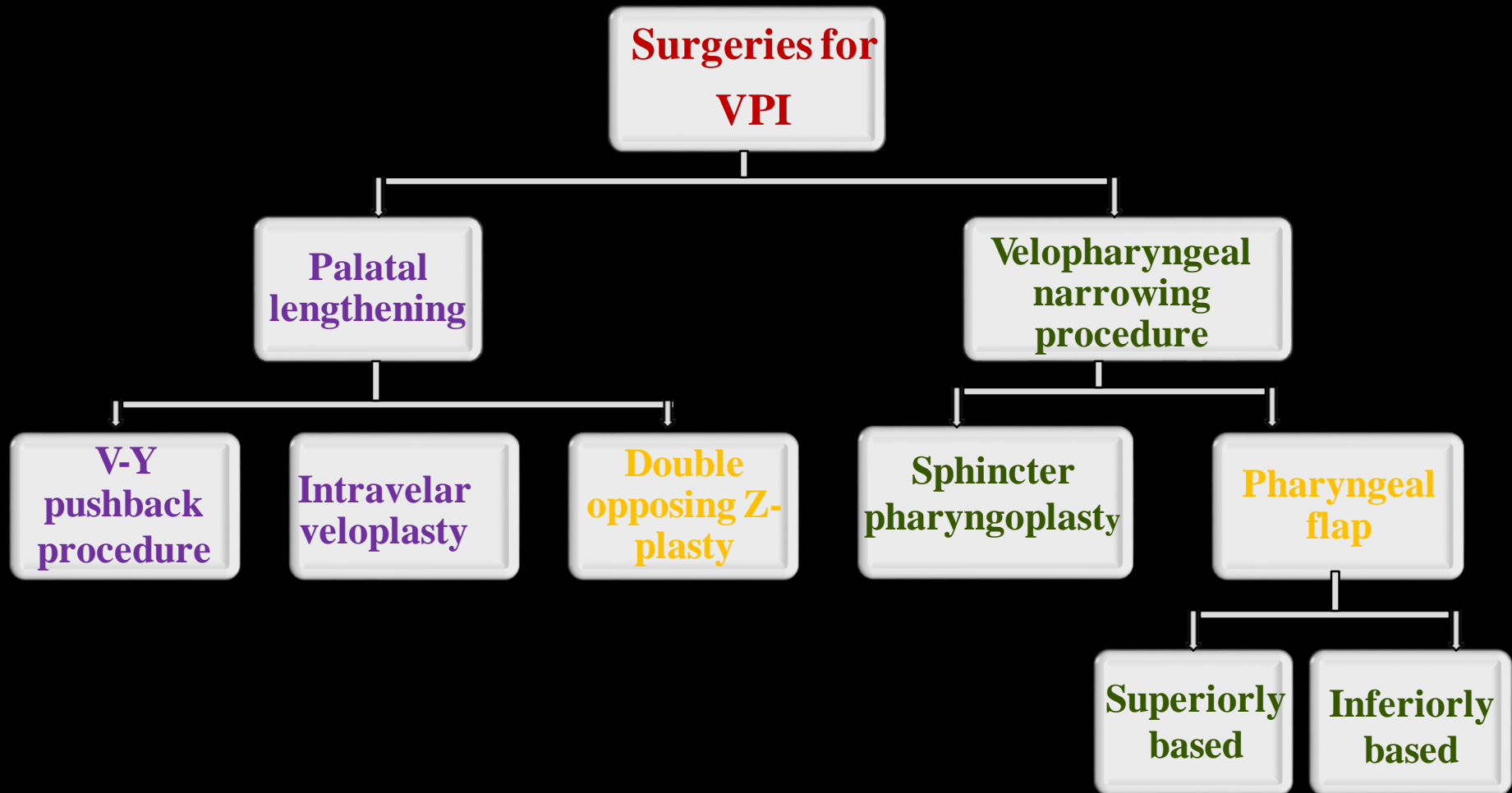


# Common Sequele

- Formation of Fistula
- Velopharyngeal Insufficiency



# VPI correction



We recommend

Modified Furlows 'Z' Plasty With Levator Myoplasty



## Why 'Z' plasty?

- Several studies have supported the selection of double opposing Z-plasty in individuals with **small VP gaps of 5 mm or less**  
(Chen et al., 1994, 1996; Lindsey and Davis, 1996; D'Antonio, 1997; Seagle et al., 1999, 2002; D'Antonio et al., 2000; Sie et al., 2001).
- With increasing experience with patient selection and modification of the z plasty design, however, increases in **length up to 10mm** have been reported.  
(Hudson et al. 1995, Orgun Deren et al, William H. Lindsey and Paul T. Davis)

## Why Levator Myoplasty?

- The physiologic orientation of the levator veli palatini muscle is crucial so that the **velum is long enough and mobile enough**. Either one alone is not enough to ensure velopharyngeal closure.





Clinical Paper  
Cleft Lip and Palate

# Use of a modified Furlow Z-plasty as a secondary cleft palate repair procedure to reduce velopharyngeal insufficiency

R. R. Reddy<sup>1</sup>, S. G. Reddy<sup>1</sup>,  
B. Banala<sup>1</sup>, E. Bronkhorst<sup>2</sup>,  
A. W. Kummer<sup>3</sup>,  
A. M. Kuijpers-Jagtman<sup>2</sup>,  
S. J. Bergé<sup>2</sup>

<sup>1</sup>GSR Institute of Craniofacial Surgery, Vinay Nagar Colony, Saidabad, Hyderabad, India;

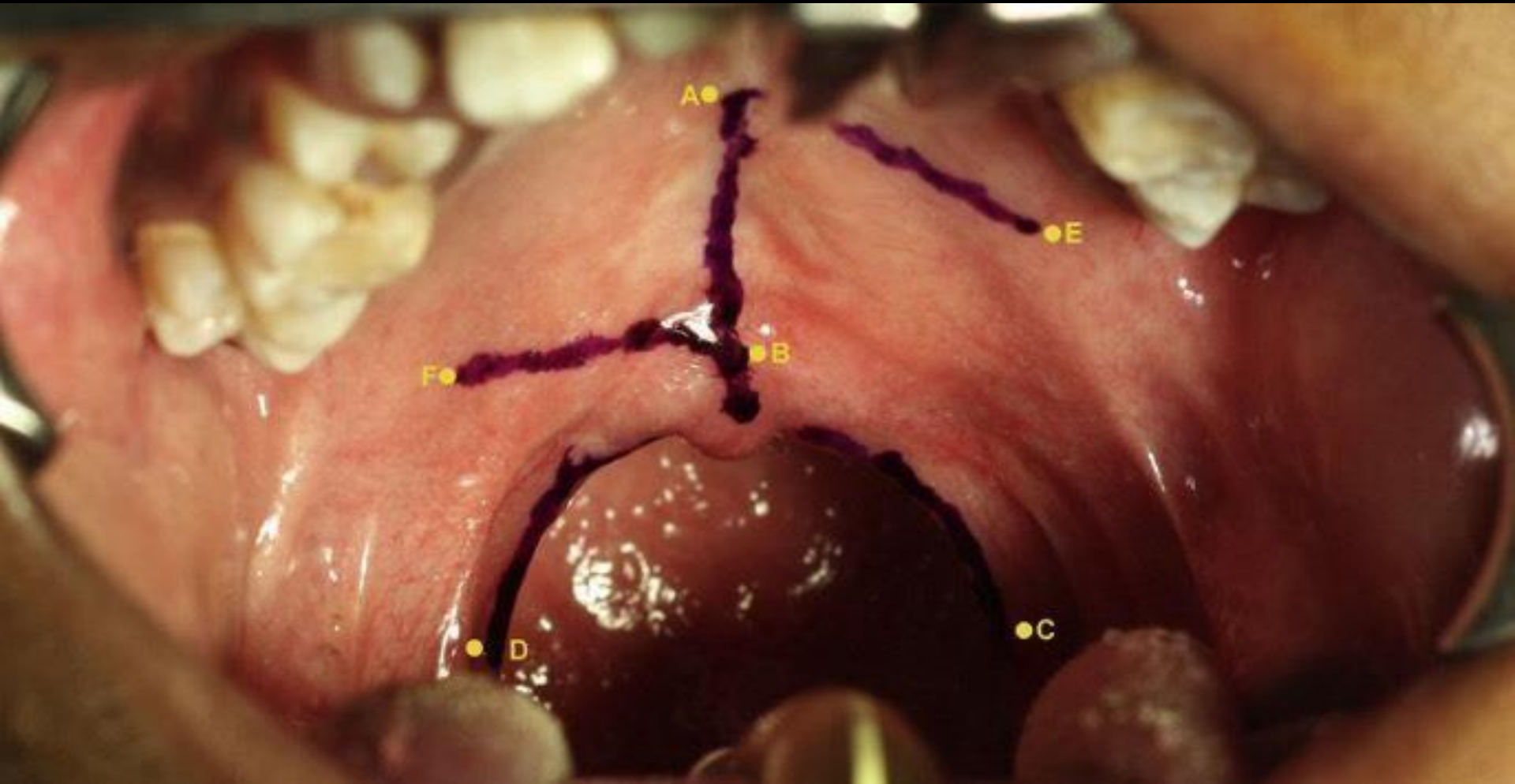
<sup>2</sup>Radboud University Nijmegen Medical Centre, Nijmegen, Netherlands; <sup>3</sup>Cincinnati Children's Hospital Medical Center and the University of Cincinnati Medical Center, Cincinnati, OH, USA

R. R. Reddy, S. G. Reddy, B. Banala, E. Bronkhorst, A. W. Kummer, A. M. Kuijpers-Jagtman, S. J. Bergé: Use of a modified Furlow Z-plasty as a secondary cleft palate repair procedure to reduce velopharyngeal insufficiency. *Int. J. Oral Maxillofac. Surg.* 2015; xxx: xxx–xxx. © 2015 Published by Elsevier Ltd on behalf of International Association of Oral and Maxillofacial Surgeons.

This Study conducted to determine the effectiveness of a modified secondary Furlow Z-plasty in improving VPI.



# Modified Furlows 'Z' Plasty with Levator Myoplasty



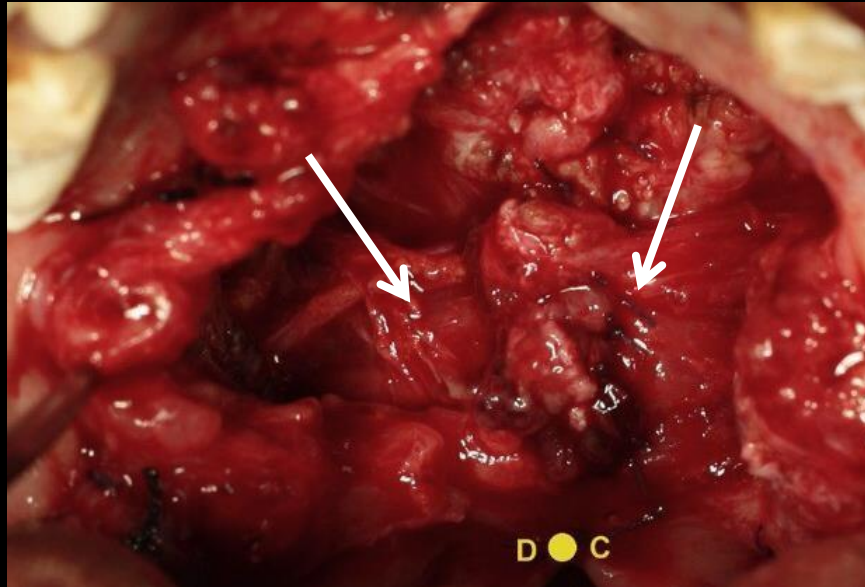
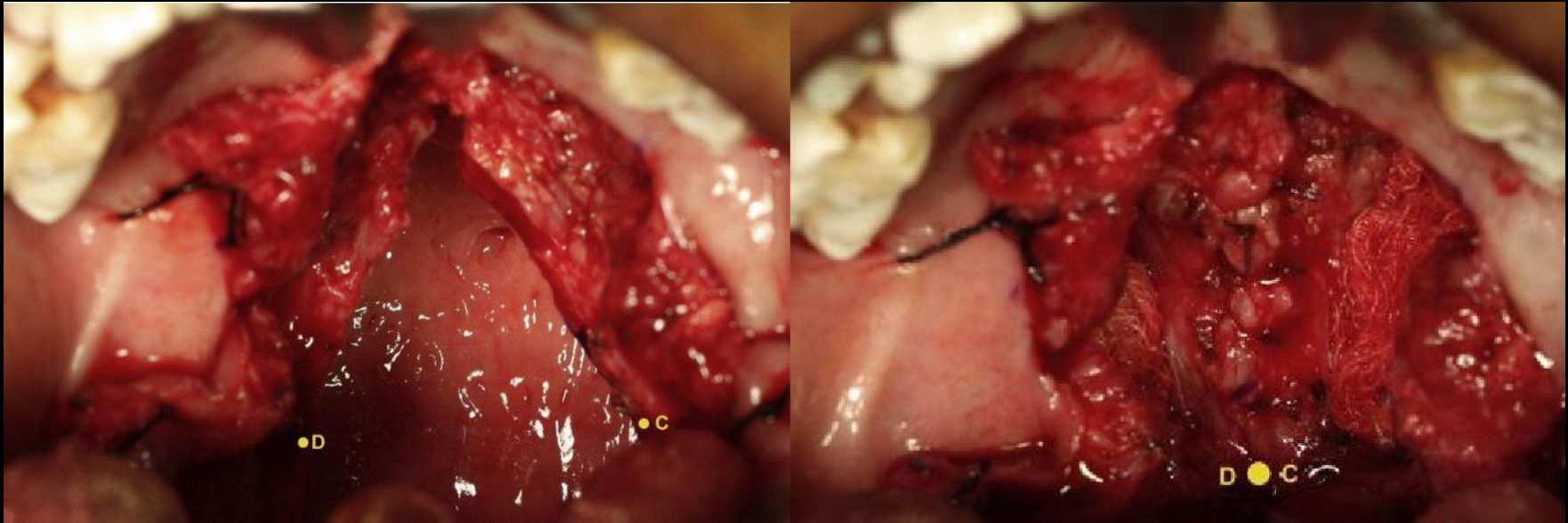
Incision marking

Reddy et al, Int J Oral Maxillofac Surg (2015), <http://dx.doi.org/10.1016/j.ijom.2015.07.006>



[www.craniofacialinstitute.org](http://www.craniofacialinstitute.org)

# Modified Furlows 'Z' Plasty with Levator Myoplasty

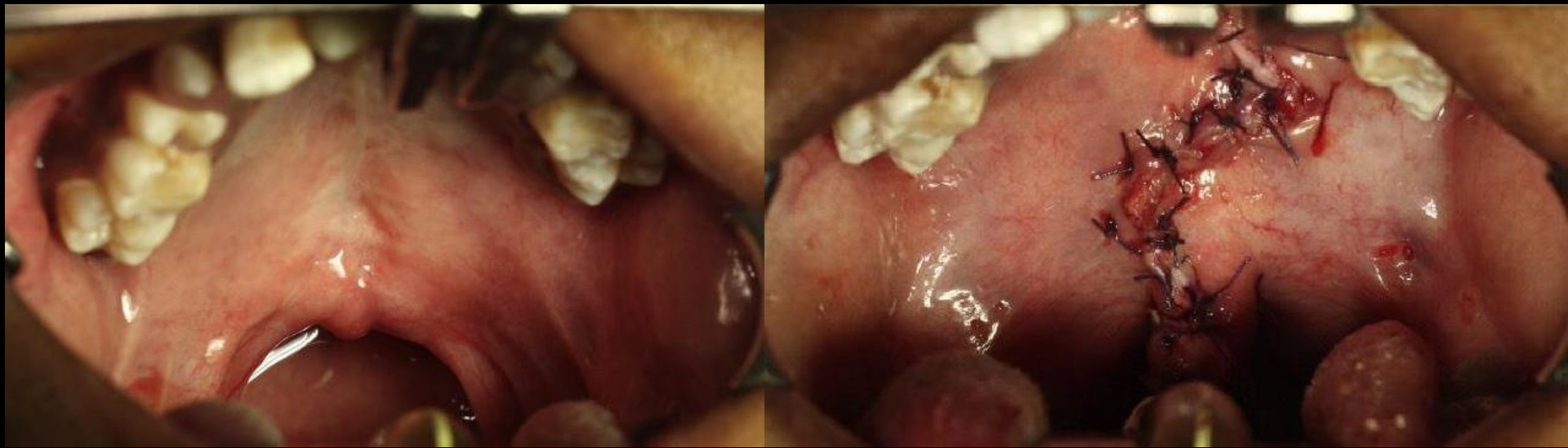

Levator Myoplasty





# Modified Furlows 'Z' Plasty with Levator Myoplasty



Closure

Reddy et al, Int J Oral Maxillofac Surg (2015), <http://dx.doi.org/10.1016/j.ijom.2015.07.006>



[www.craniofacialinstitute.org](http://www.craniofacialinstitute.org)

## RESULTS

- Post operative **hypernasality reduced** significantly.
- Post operative **hyponasality did not develop**.
- Furlow's z- plasty with levator myoplasty for secondary repair of VPI seems is a proven technique in reduction of hypernasality during speech.





# My Recommendations

- **Primary Palatoplasty:-**

Evidenced based Morpho-Functional Palatoplasty

- One Stage

- Two Flap Technique with optimal Muscle dissection keeping Tensor Tendon intact

- **Fistula :-**

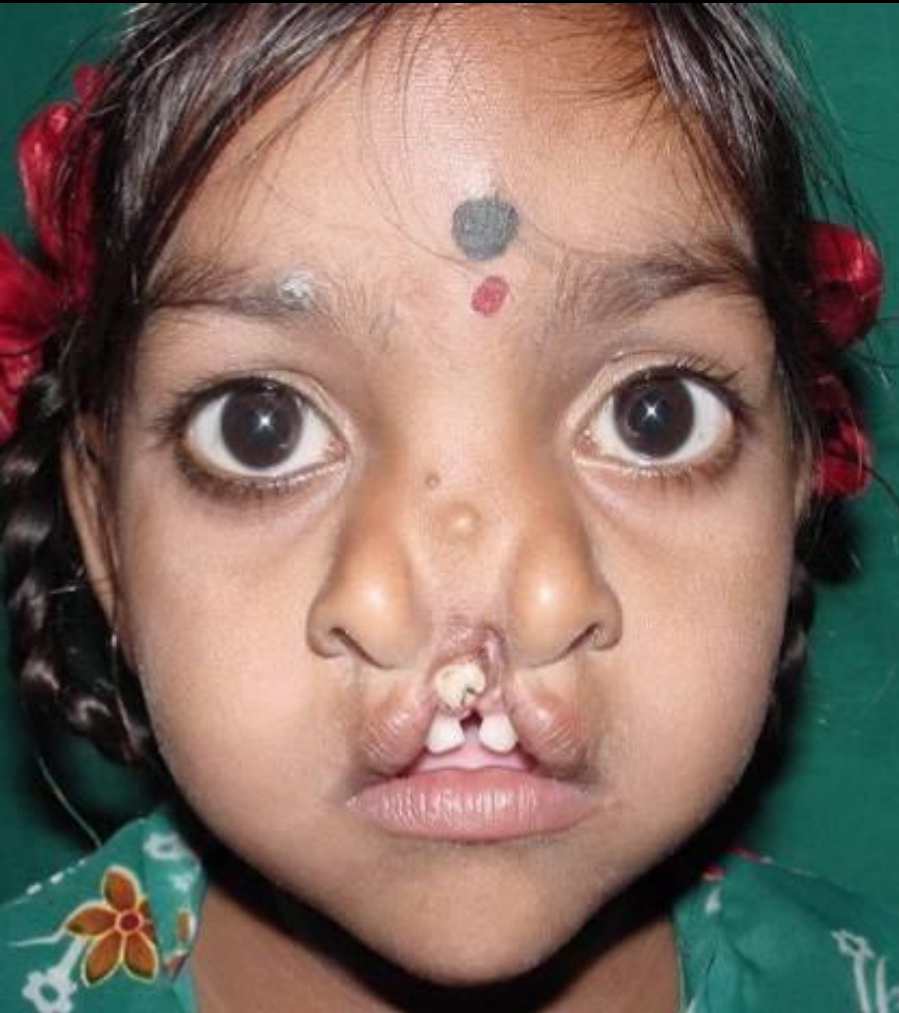Prevent using an antibiotic soaked pack

- **Velopharyngeal Incompetence:-**

Modified Furlows 'Z' plasty with levator myoplasty



# Bring the Smile Back



## Thank You



[www.craniofacialinstitute.org](http://www.craniofacialinstitute.org)