

CRANIOSYNOSTOSIS WHEN, WHY AND HOW TO INTERVENE

Prof. Dr. Dr. Srinivas Gosla Reddy

MBBS, MDS, FRCS (Edin.), FDSRCS (Edin), FDSRCS (Eng), FDSPCPS (Glasg) PhD

Dr. Rajgopal R. Reddy MBBS, BDS, FDSRCPS (Glasg) PhD

Dr. Ashish Fanan MDS

Dr. Avni Pandey MDS

Dr Madhav Thumati, MDS

GSR Institute of Craniofacial Surgery Hyderabad, India



GSR Institute of Facial Plastic Surgery



- Non-profit hospital established in 1996
- Dedicated Cleft & Craniofacial Centre of Excellence
- Presently 1,600 cleft and craniofacial surgeries are done every year
- 3 surgeons and 4 fellows with full support team
- More than 30,000 documented cleft & craniofacial surgeries have been performed since 1996
- 600 primary new born cleft children are registered every year



Craniosynostosis

What?

A craniosynostosis is a **developmental anomaly** which occurs as a **consequence of abnormal and non-physiological sutural fusion** of cranial bones which normally are supposed to be fused after 1 year of birth.

When one or more sutures are prematurely closed, the compensatory growth starts perpendicular to the patent sutures since the brain still grows and expands in the direction of lower resistance

Craniosynostosis - Recognition, clinical characteristics, and treatment Nina Kajdic^{1,2}, Peter Spazzapan², Tomaz Velnar² *


¹ Chair of Surgery, Medical Faculty, University of Ljubljana, Ljubljana, Slovenia, ² Department of Neurosurgery, University Medical Centre Ljubljana, Ljubljana, Slovenia

DOI: <http://dx.doi.org/10.17305/bjbms.2017.2083> Bosn J Basic Med Sci. 2018;18(2):110-116. © 2018 ABMSFBIH



CRANIOSYNOSTOSIS

The term craniosynostosis was first used by Otto in 1830



ABNORMALLY SHAPED SKULL



INCREASED INTRACRANIAL PRESSURE (ICP), AS WELL AS
SENSORY, RESPIRATORY AND NEUROLOGICAL
DYSFUNCTIONS



FREQUENCIES:

Different types of craniosynostoses are as follows:

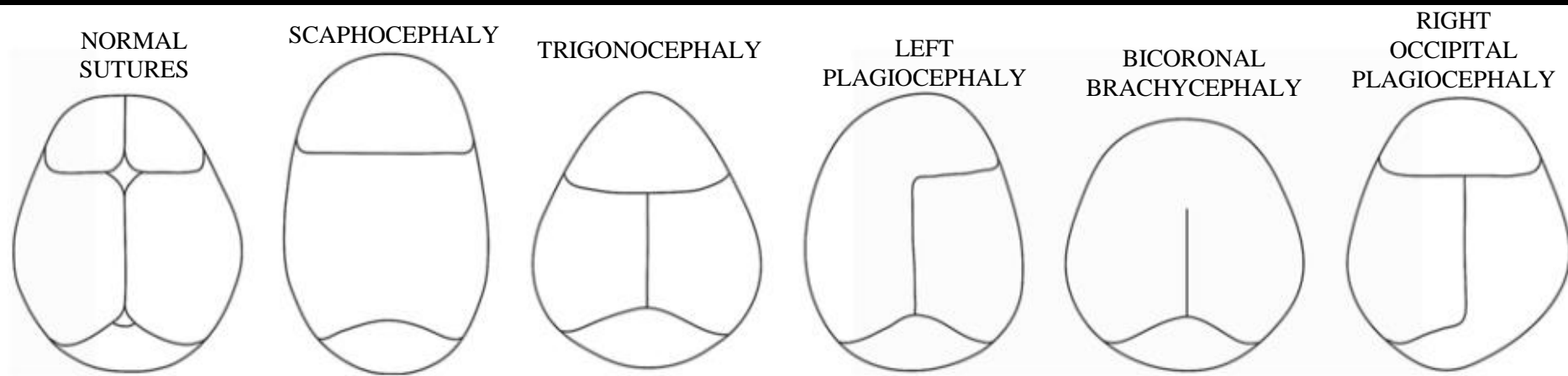
- Sagittal ($\approx 60\%$)=SCAPHOCEPHALY
- Coronal ($\approx 25\%$)=UNILATERAL –PLAGIOCEPHALY /
BILATERAL-BRACHYCEPHALY
- Metopic ($\approx 15\%$)=TRIGONOCEPHALY
- Lambdoid ($\approx 2\%$) =POSTERIOR PLAGIOCEPHALY

Craniosynostosis - Recognition, clinical characteristics, and treatment Nina Kajdic^{1,2}, Peter Spazzapan², Tomaz Velnar² *

¹ Chair of Surgery, Medical Faculty, University of Ljubljana, Ljubljana, Slovenia, ² Department of Neurosurgery, University Medical Centre Ljubljana, Ljubljana, Slovenia

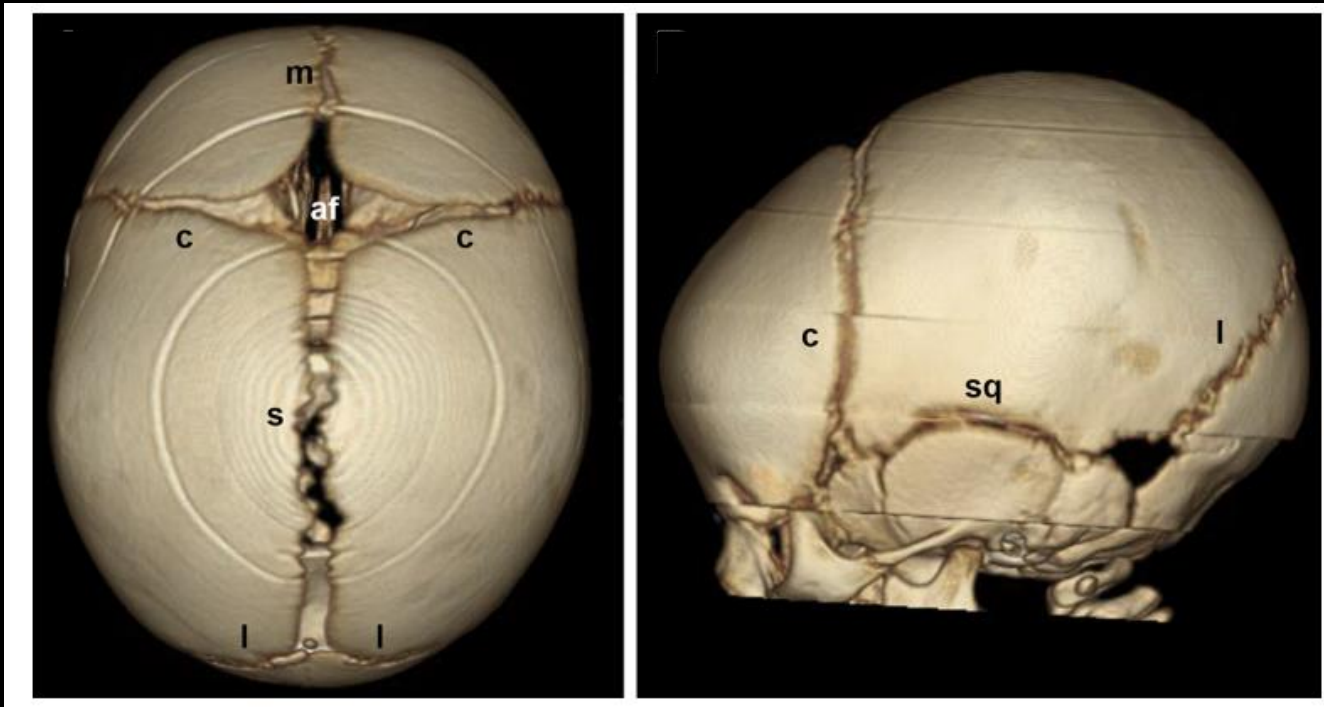
DOI: <http://dx.doi.org/10.17305/bjbms.2017.2083> Bosn J Basic Med Sci. 2018;18(2):110-116. © 2018 ABMSFBIH





Genetic Causes of Craniosynostosis: An Update Jacqueline A.C. Goos Irene M.J. Mathijssen
Department of Plastic and Reconstructive Surgery and Hand Surgery, Erasmus MC,
University Medical Center Rotterdam, Rotterdam , The Netherlands
Mol Syndromol 2019;10:6–23 DOI: 10.1159/000492266

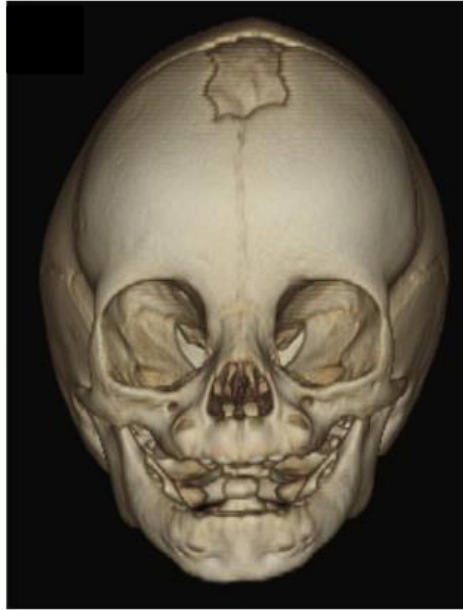
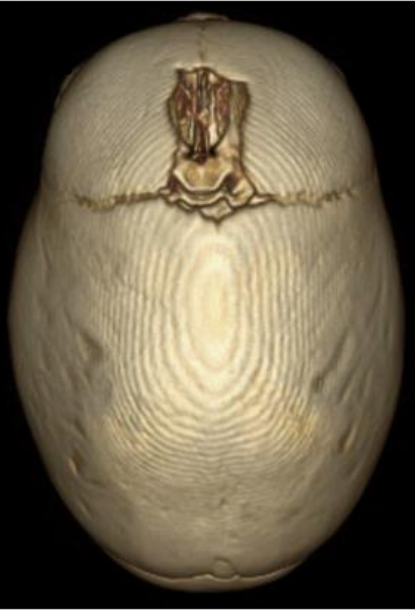ANATOMY



NORMAL CRANIAL SUTURES

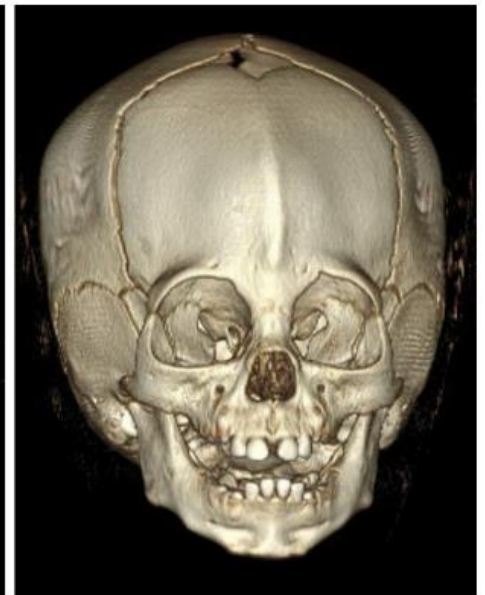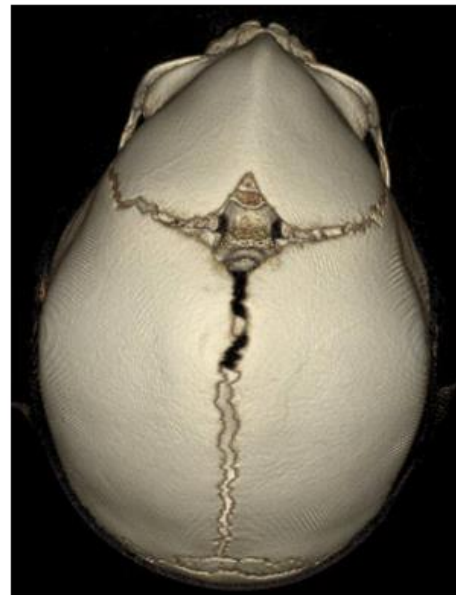THREE DIMENSIONAL CT SCAN SHOWS METOPIC (m),CORONAL (c),SAGITTAL(s),LAMBDOID(l),and SQUAMOSAL(sq) SUTURES AS WELL AS ANTERIOR FONTANEL(af)

Topical Review Craniosynostosis,L.S. Governale / Pediatric Neurology 53 (2015) 394e401

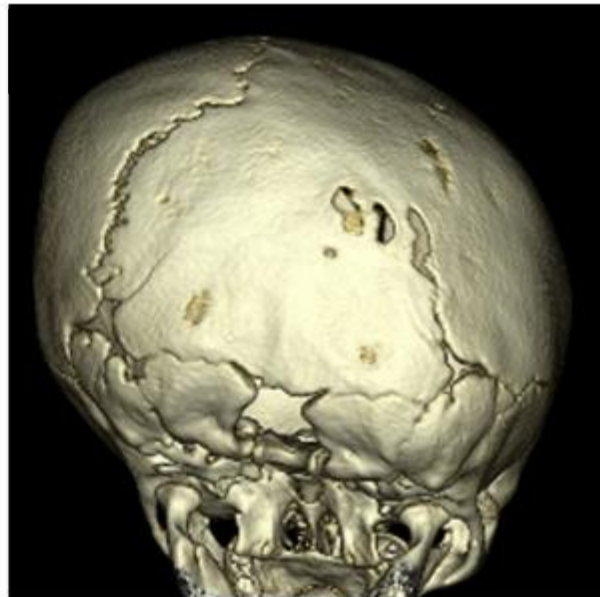
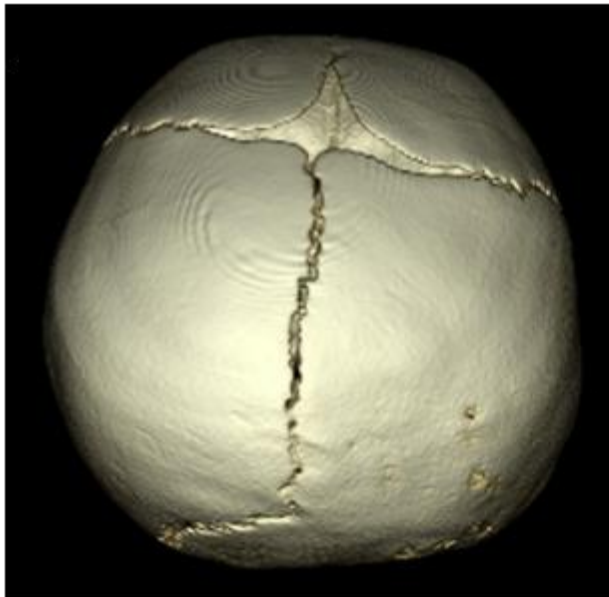


**SAGITTAL
CRANIOSYNOSTOSIS
(SCAPHOCEPHALY)**

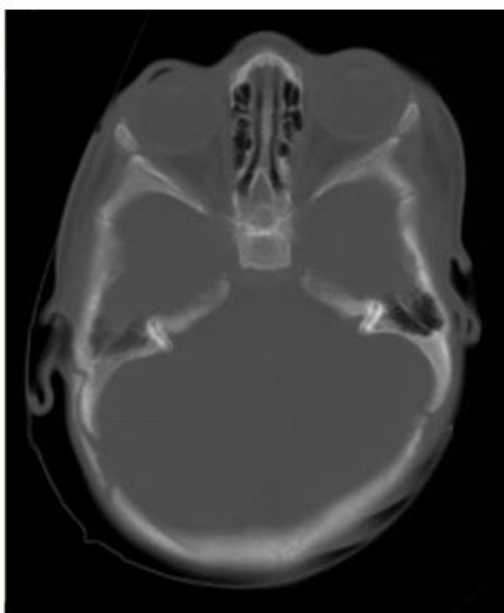
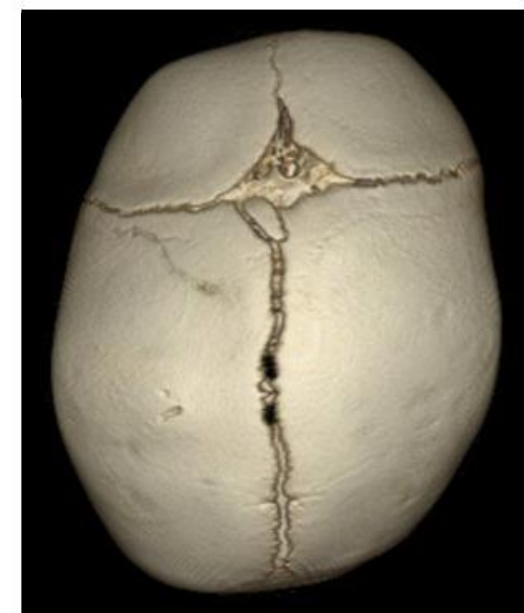
**METOPIC
CRANIOSYNOSTOSIS
(TRIGONOCEPHALY)**



Topical Review
Craniosynostosis, L.S. Governale /
Pediatric Neurology 53 (2015)
394e401



**LAMBDROID
CRANIOSYNOSTOSIS
(POSTERIOR
PLAGIOCEPHALY)**



**POSITIONAL
PLAGIOCEPHALY**

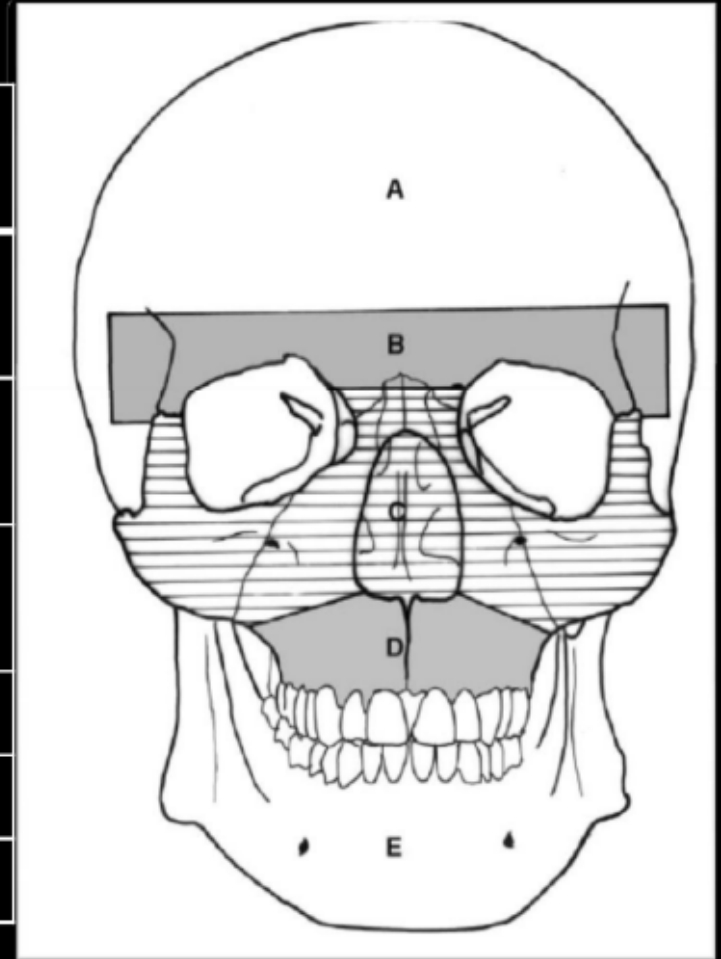
Topical Review
Craniosynostosis, L.S. Governale /
Pediatric Neurology 53 (2015)
394e401

Classification Craniofacial Synostosis and Dysostosis

Tessier divided the craniofacial framework into five levels

Classified Synostosis and Dysostosis topographically and anatomically into six groups

Tessier's classification	Levels of malformation
Class 1: isolated cranial vault dysmorphism	Level A
Class 2: syndromic orbitocranial dysmorphism	Level B
Class 3: asymmetric orbitocranial dysmorphism	Level B and C
Class 4: Saethre-Chotzen group	Level A-C
Class 5: Crouzon group	Level A-D
Class 6: Apert group	Level A-E



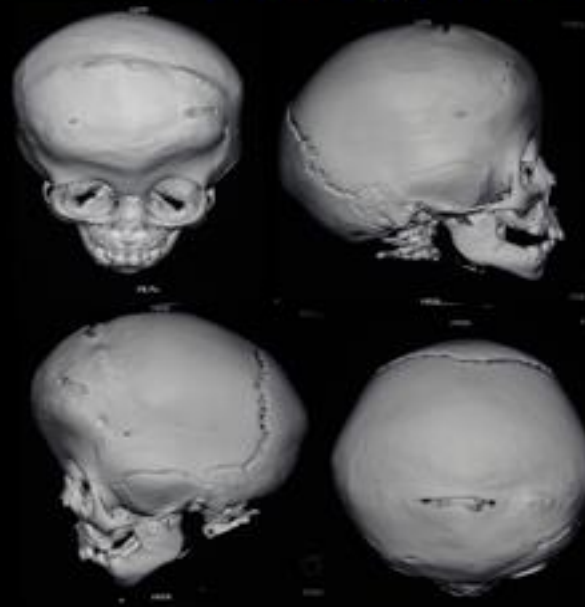
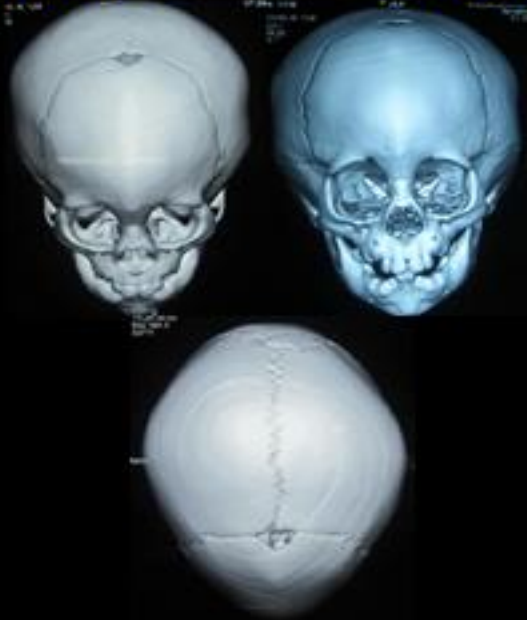
Craniosynostosis

Plagiocephaly/Trigonocephaly/Scaphocephaly/Brachycephaly

Premature fusion of cranial sutures

Plagio~	=	Oblique shaped	=	Unilateral coronal or lambdoid suture synostosis
Trigon~	=	Triangular shaped	=	Metopic suture synostosis
Scapho~	=	Boat shaped	=	Sagittal suture synostosis
Brachy~	=	Flat shaped	=	Coronal suture synostosis

Irregular shaped head → CT Scan Skull → Suture synostosis



CLASSIFICATION OF CRANIOSYNOSTOSES

1.PRIMARY CRANIOSYNOSTOSIS

A craniosynostosis develops due to a **primary defect of the ossification process** .

2.SECONDARY CRANIOSYNOSTOSIS

is the result of **known systemic diseases with hematologic or metabolic dysfunction**, such as rickets and hypothyroidism.

Secondary craniosynostosis can also develop in newborns with microcephaly due to a failure of brain growth or following shunt placement in children with hydrocephalus.

3.SYNDROMIC CRANIOSYNOSTOSIS (CRANIOFACIAL DYSOSTOSIS)

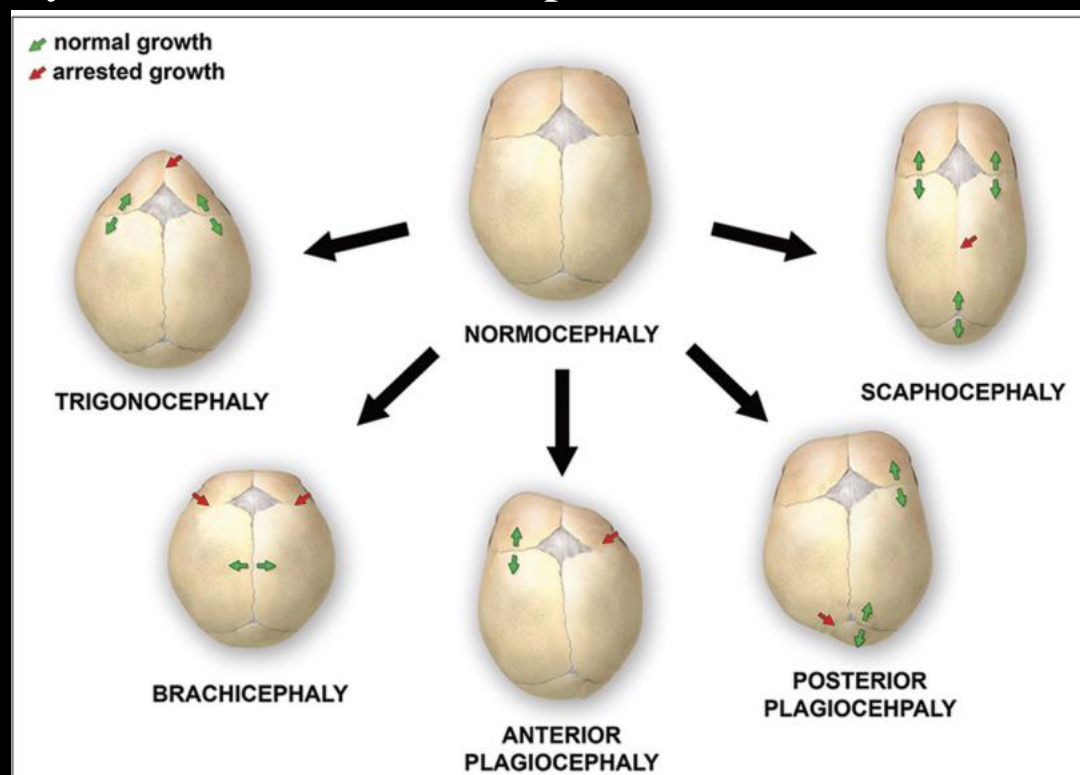
Crouzon Syndrome/Apert Syndrome/Pfeiffer Syndrome/Cloverleaf skull

4.NON SYNDROMIC CRANIOSYNOSTOSIS (CRANIOSYNOSTOSIS)

Plagiocephaly/Trigonocephaly/Scaphocephaly/Brachycephaly

CLASSIFICATION OF CRANIOSYNOSTOSES

1. Simple craniosynostosis : When only one suture fuses prematurely
2. Complex craniosynostosis : Describes a premature fusion of multiple sutures



Craniosynostosis - Recognition, clinical characteristics, and treatment Nina Kajdic^{1,2}, Peter Spazzapan², Tomaz Velnar² * 1 Chair of Surgery, Medical Faculty, University of Ljubljana, Ljubljana, Slovenia, 2 Department of Neurosurgery, University Medical Centre Ljubljana, Ljubljana, Slovenia

DOI: <http://dx.doi.org/10.17305/bjbms.2017.2083> Bosn J Basic Med Sci. 2018;18(2):110-116. © 2018 ABMSFBIH

Type of craniosynostosis	Typical characteristics
Scaphocephaly	<ul style="list-style-type: none"> - Premature fusion of the sagittal suture - Elongated head in the anterior-posterior and shortened in the bilateral direction - Frontal bossing is present - Boys more frequently affected (3.5:1)
Anterior plagiocephaly	<ul style="list-style-type: none"> - High supraorbital margins (Harlequin sign) - Forehead pushed forward on the unaffected side - Nasal septum deviation towards the normal side - More common in girls (2:1)
Posterior plagiocephaly	<ul style="list-style-type: none"> - Unilateral lambdoid synostosis - Frontal and occipital bossing - Ipsilateral ear and mastoid displaced downward - Head shape from above may resemble a trapezoid
Positional plagiocephaly	<ul style="list-style-type: none"> - Ipsilateral ear and forehead displaced anteriorly - Parallelogram shape of the head - Ipsilateral occipital flattening accompanied by contralateral occipital bossing - Male to female ratio 3:1
Trigonocephaly	<ul style="list-style-type: none"> - Premature fusion of the metopic suture - Occipital part is broad, forehead is narrow and pointed - Triangular shape of the head - Hypotelorism
Brachycephaly	<ul style="list-style-type: none"> - Bilateral coronal synostosis - Short skull - Forehead and occipital part flattened - Frontal bone prominent and elongated in vertical direction - Hypertelorism - Harlequin malformation of the orbits

CLINICAL FEATURES OF **CRANIOSYNOSTOSES**

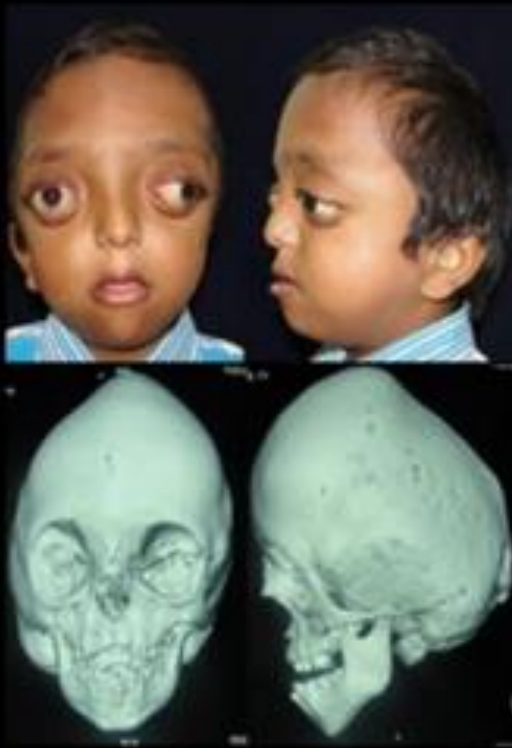CRANIOSYNOSTOSIS

In addition to cranial growth restriction, **INCREASED ICP** may develop in the syndromic patients because of venous outflow stenosis at the jugular foramina, elevated central venous pressures from obstructive sleep apnea, and hydrocephalus from aqueductal stenosis or fourth ventricular outflow obstruction.



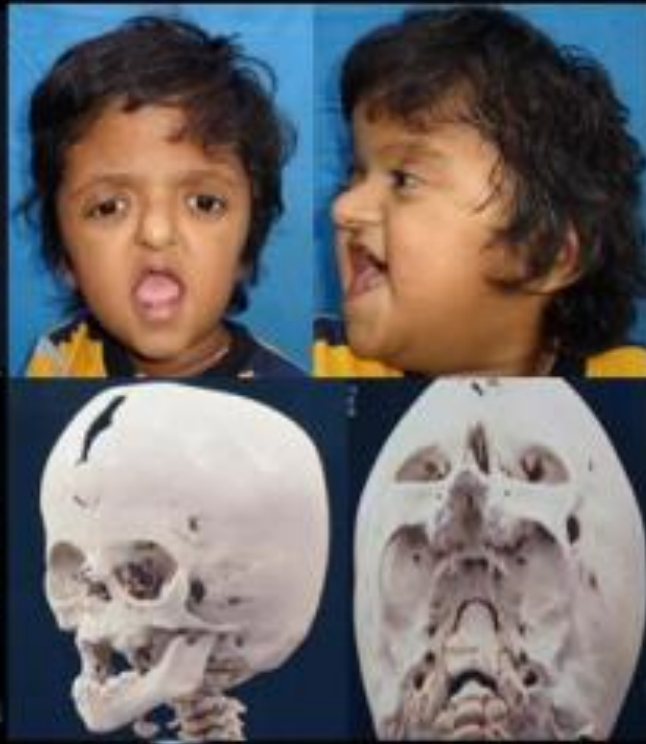SYNDROMIC CRANIOSYNOSTOSIS: CRANIOFACIAL DYSOSTOSIS

CROUZAN'S



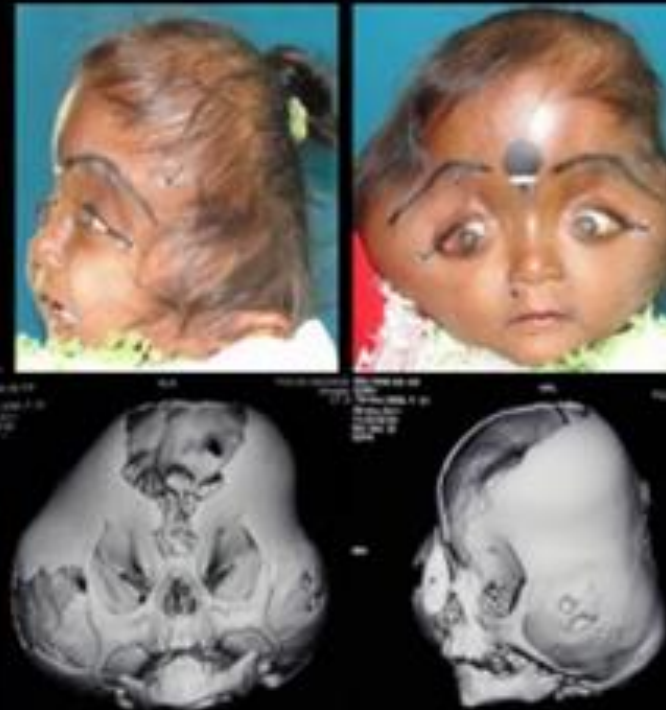- Craniosynostosis
- Exophthalmos
- Hypertelorism
- Stabismus
- Hypoplastic maxilla

APERTS



- Craniosynostosis
- Hypertelorism
- Retruded maxilla
- Stubby fingers and toes

CLOVERLEAF SHAPE

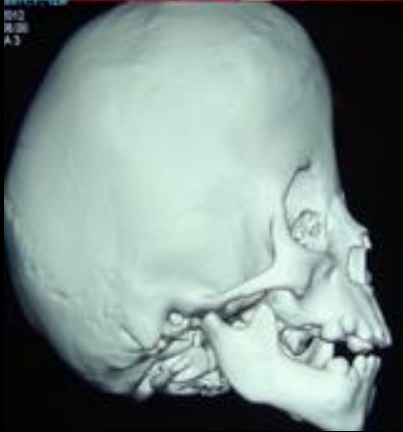
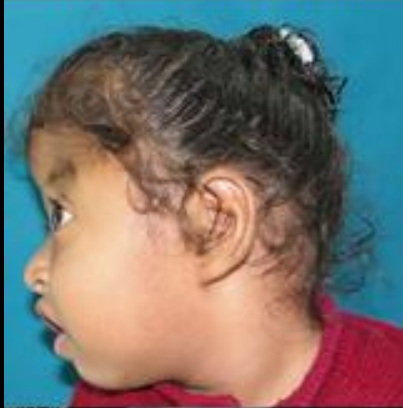
- Severe craniosynostosis
- Cloverleaf shape of skull

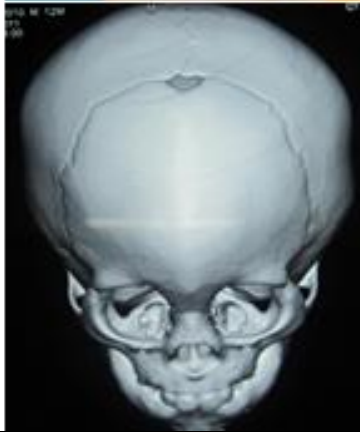
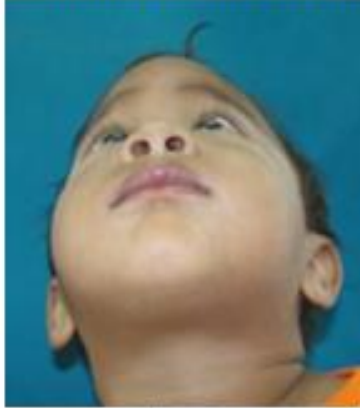
NON-SYNDROMIC CRANIOSYNOSTOSIS

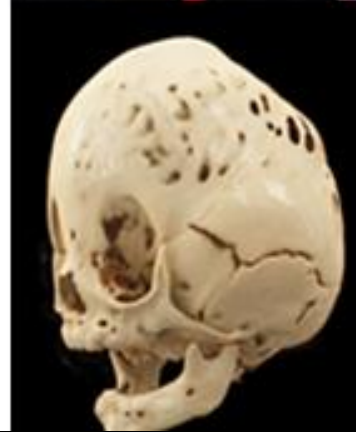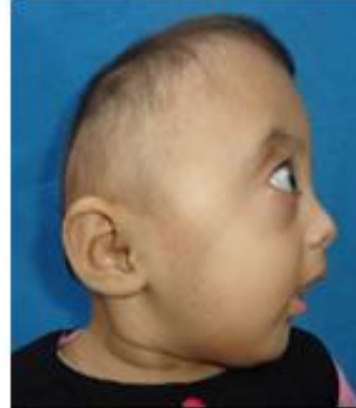BRACHYCEPHALY



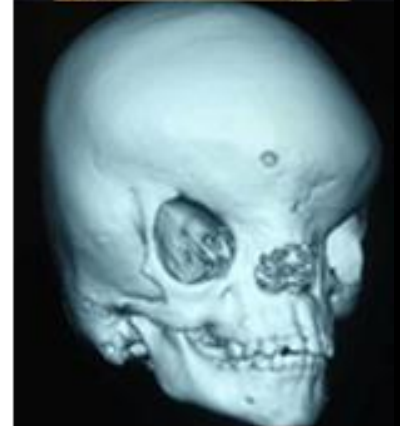
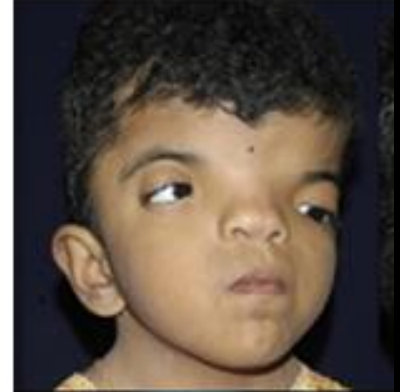TRIGONOCEPHALY



OXYCEPHALY



PLAGIOCEPHALY



WHY TO INTERVENE?



WHY TO INTERVENE?:

- If left **untreated**, craniosynostosis can **affect the development of the child**; this is due to the **restriction for growth of the brain and damage to the brain tissue due to increased intracranial pressure**.
- The degree of developmental delay hinges on the kind of craniosynostosis.
- Children with **sagittal synostosis** have a **lower risk of learning disabilities** compared to those with metopic, unicoronal, or lambdoid synostosis.
- With early identification of developmental gaps and placement in support programs, a negative academic and cognitive outcome for these children could be reduced if not prevented.
- The major functional problems associated with craniosynostosis are **intracranial hypertension, visual impairment, limitation of brain growth, and neuropsychiatric disorders**. In general, the **functional problem increases as the number of sutures involved increases**.



WHEN TO
OPERATE AND
WHEN NOT TO
OPERATE?



WHEN TO OPERATE AND WHEN NOT TO OPERATE?

- The **uncomplicated and non-syndromic types** can be managed **surgically but electively** compared to some **syndromic forms** that require **urgent surgical intervention due to the involvement of the airway, ophthalmologic, and neurological system.**
- A **conservative approach** with **remodeling helmets** could be attempted first in cases in which **unilateral craniosynostosis** is not too severe.
- **Extent**, as well as the **type of surgery**, depends on the **age** and **presentation** of the patient.
- General indications for surgical intervention in nonsyndromic craniosynostosis :
 1. Presence of cosmetic deformity
 2. Functional impairment, such as intracranial hypertension or optic atrophy
- In severe cases/syndromic cases, the focus is on maintaining the airway and nutritional support, eye protection and normal intracranial pressure.
- **THE BEST TIME IN WHICH THE CORRECTION SHOULD BE DONE** is between **6 to 12 months of age** when there are no signs of increased ICP or airway compromise, and this correlates with the period in which the infant's brain and head grow the most



HOW TO INTERVENE?



MANAGEMENT

1. Open calvarial reconstruction
2. Minimally invasive strip craniectomy with use of postoperative molding helmet
3. Minimally invasive strip craniectomy with spring implantation
4. Cranial distraction



Topical Review
Craniosynostosis, L.S.
Governale / Pediatric
Neurology 53 (2015)
394e401



- OPEN CRANIOTOMY:
 - 1.Done in patients older than six months because the bones are more rigid and cannot be manipulated as well with an endoscope.
 - 2.This modality allows for a better remodeling of the skull and decreases the need for helmet use postoperatively.
- ENDOSCOPIC SUTURECTOMY:

Done in a patient less than six months of age because the bone is more flexible and manageable by an endoscope.

ADVANTAGE:

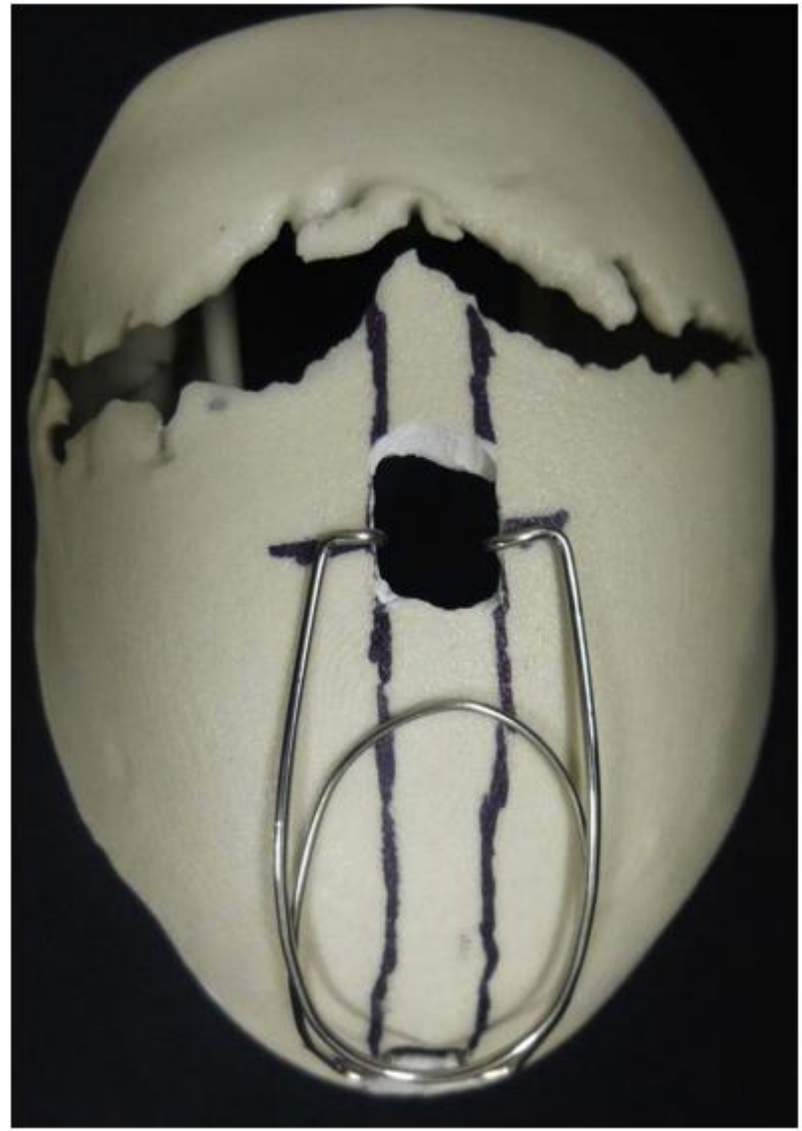 - 1.The postoperative recovery is faster,
 - 2.Less blood loss
 - 3.Surgery is shorter compared to open craniotomy.

DISADVANTAGE:

The only downside is that most times, there is a need to combine the surgery with the postoperative use of remodeling helmet for 4 to 6 months
- GOAL OF SURGERY :
 - 1.is to create enough space in the cranial vault for the brain to grow and develop properly .
 - 2.To provide the child with a more decent-looking appearance.



CRANIAL EXPANDER SPRING:



The stainless steel springs are implanted after the fused suture is resected and then removed 3 months later.

The amount of distraction force selected is based on the patient's age, bone thickness, and deformity severity

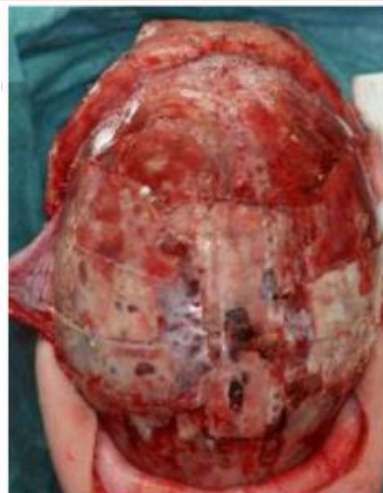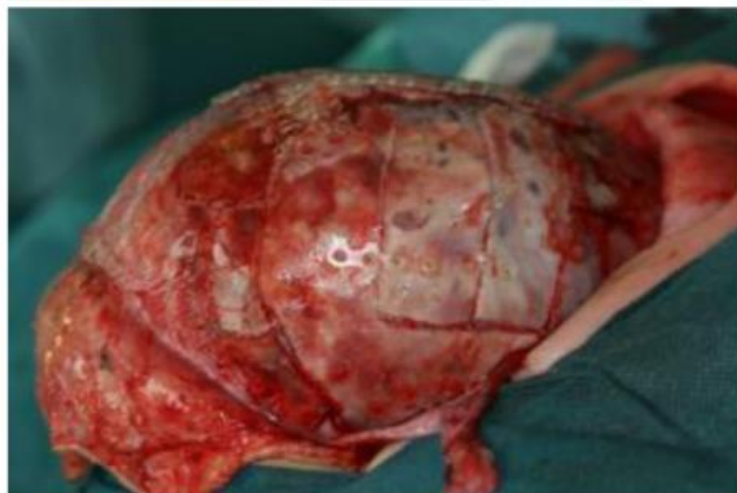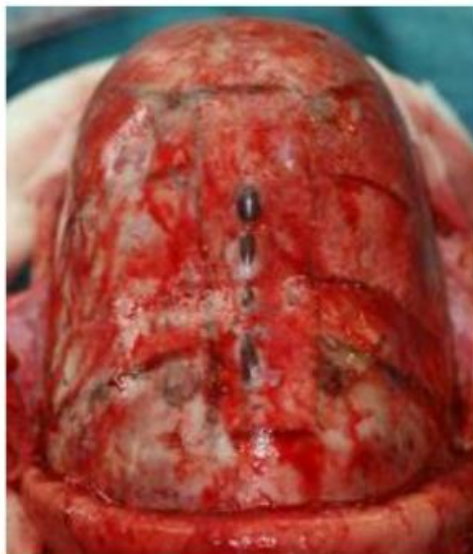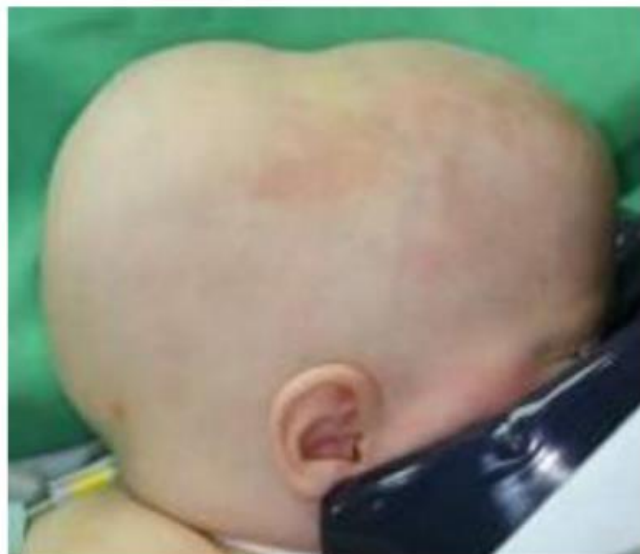Topical Review Craniosynostosis, L.S. Governale /
Pediatric Neurology 53 (2015) 394e401



SCAPHOCEPHALY:

Sagittal craniosynostosis has been treated using both cranial remodeling techniques and modification of the sagittal strip craniectomy. Surgical approaches for correction of scaphocephaly in sagittal synostosis range from synostectomy (either endoscopic or open), a Pi procedure that involves more extensive strip craniectomy for anteroposterior shortening, to near-total cranial vault reconstruction for children. Generally, greater degrees of deformity and scaphocephaly require lateral wedge, radial/frontal, and occipital osteotomies and subtotal calvarial reconstruction. For severe cases and for children who present later in life, a two stage procedure may be required in which occipital deformity is corrected in a first stage and later followed by frontal reconstruction.

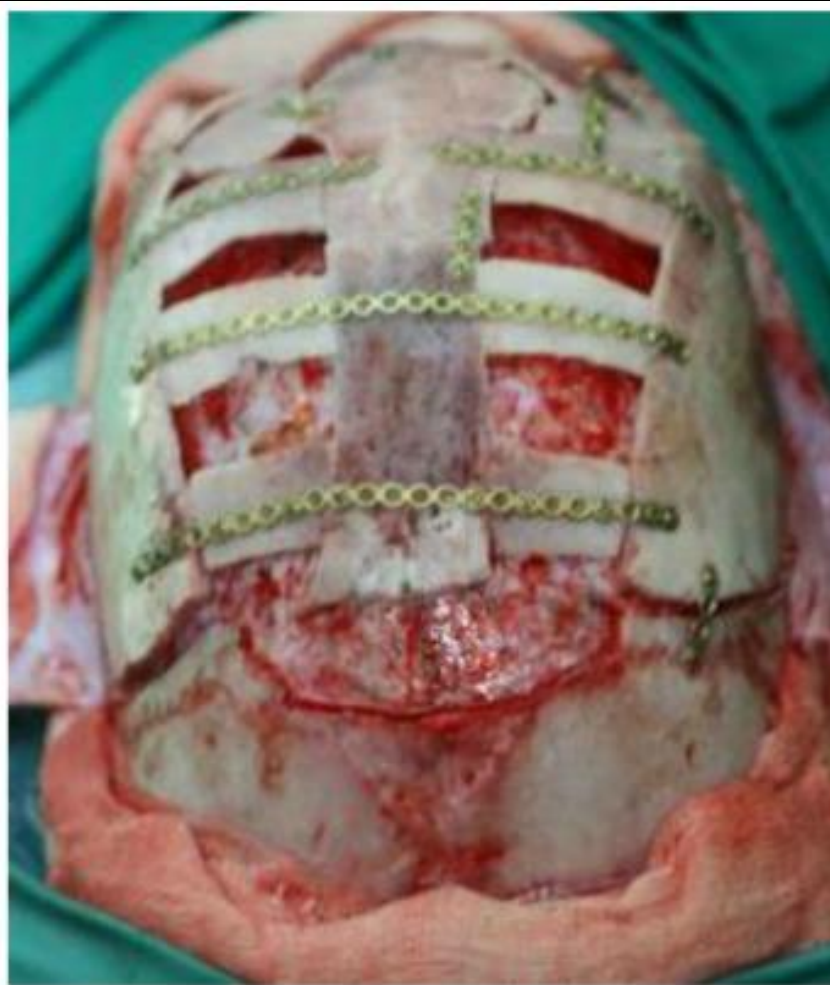
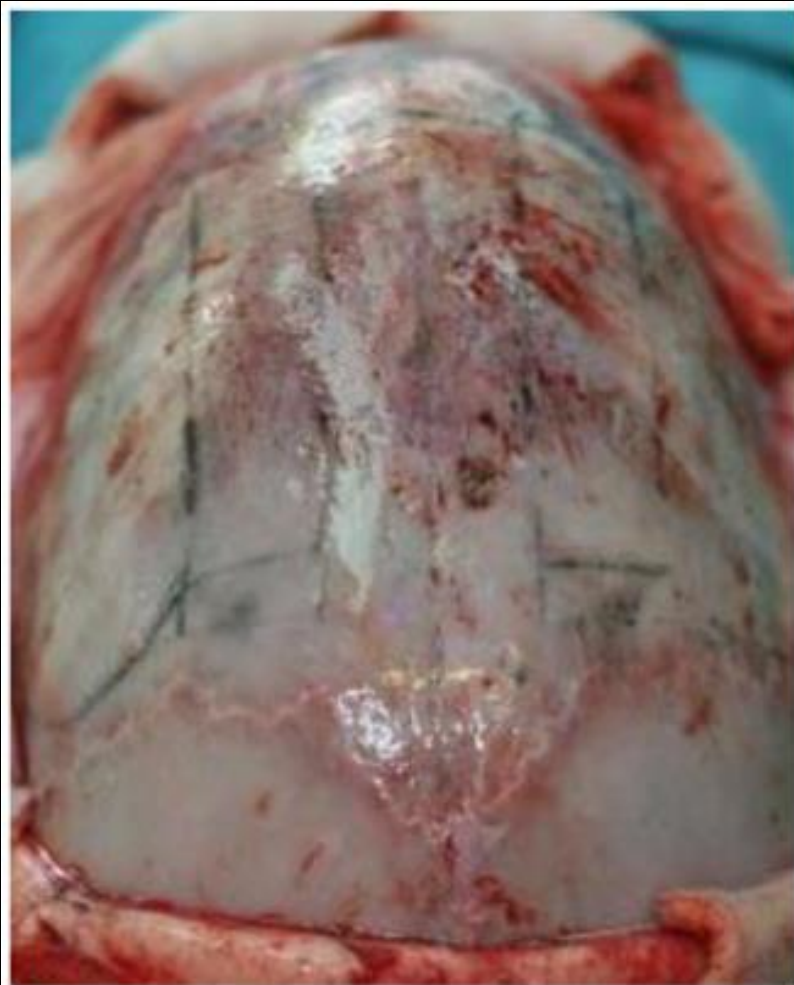


CRANEOLACUNAE AND LINES OF OSTEOTOMY

Diagnosis and treatment of craniosynostosis: Vilnius team experience : Acta medica Lituanica
August 2015 DOI: 10.6001/actamedica.v22i2.3126





Diagnosis and treatment of craniosynostosis: Vilnius team experience : Acta medica Lituanica
August 2015 DOI: 10.6001/actamedica.v22i2.3126

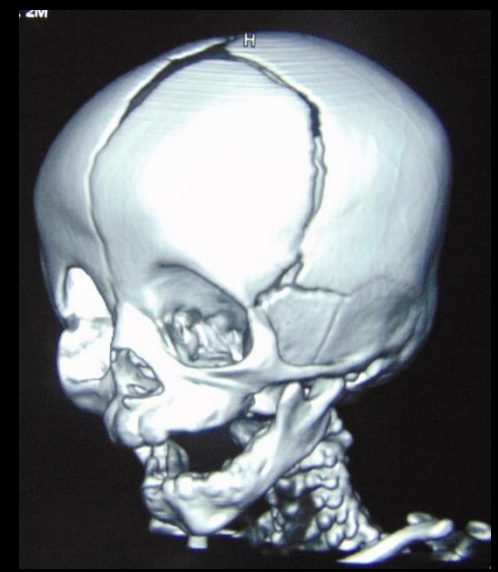
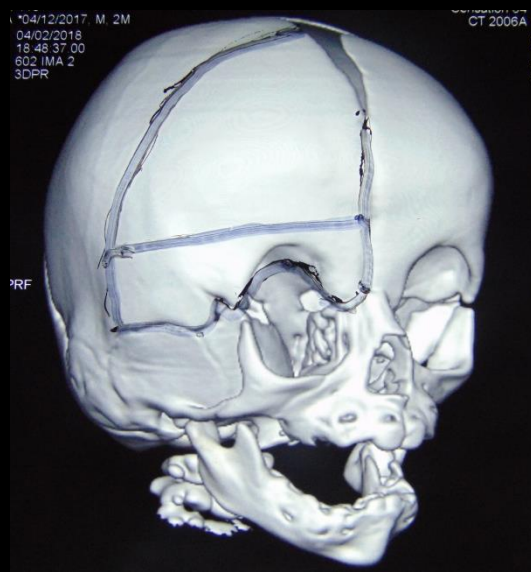
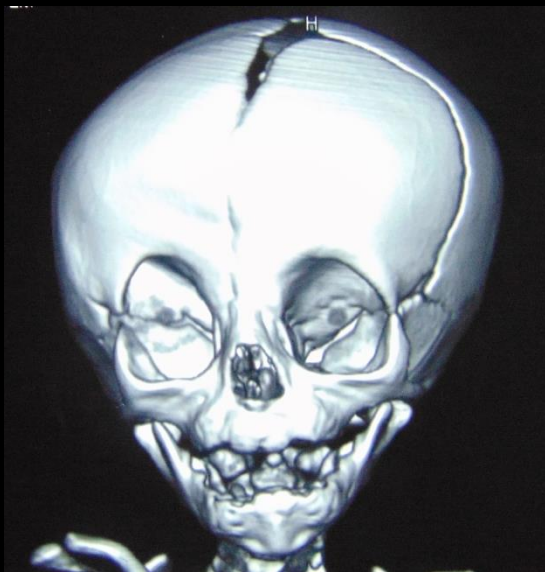
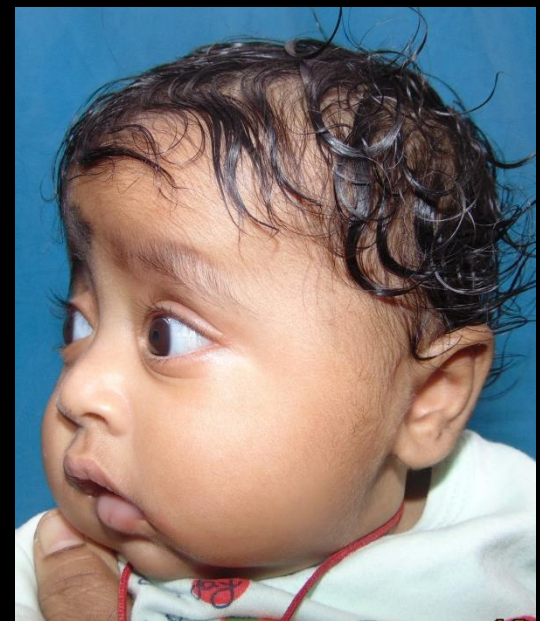
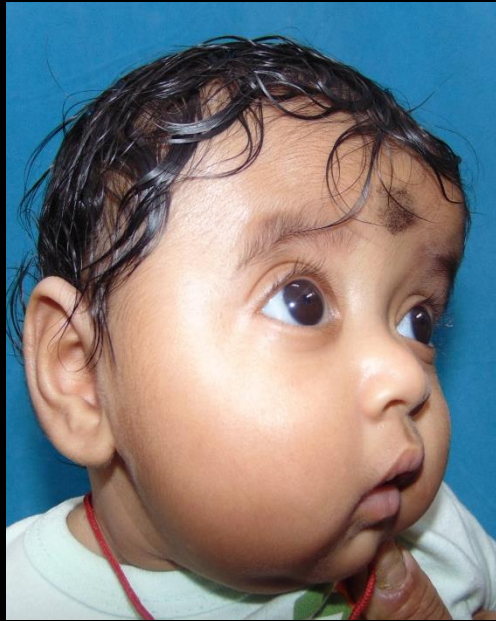
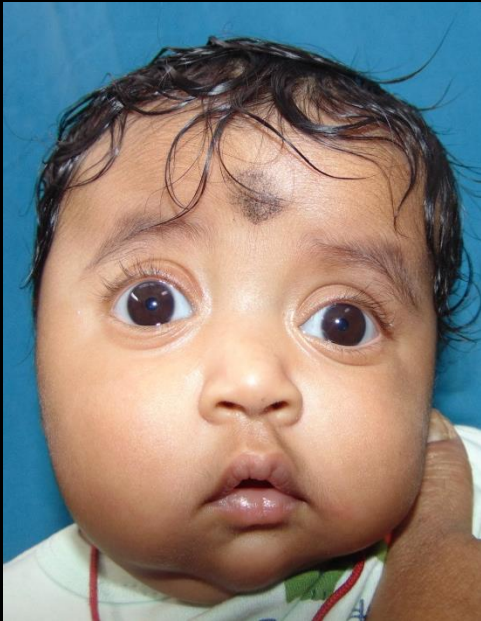PLAGIOCEPHALY:

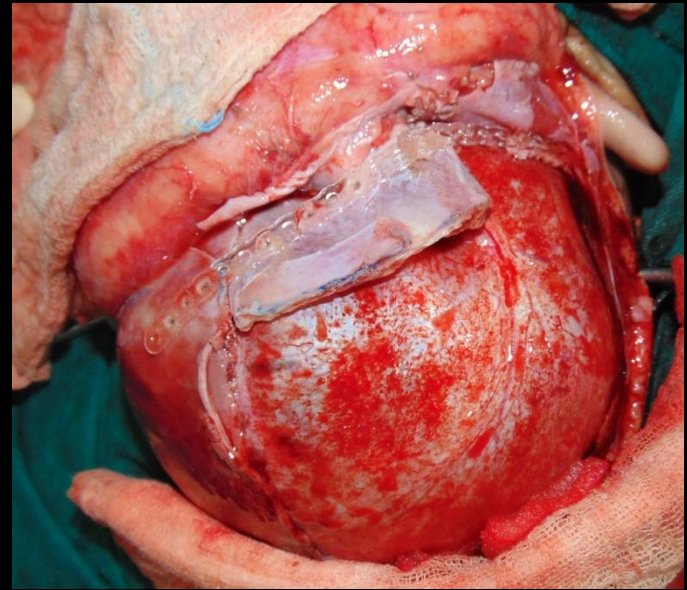
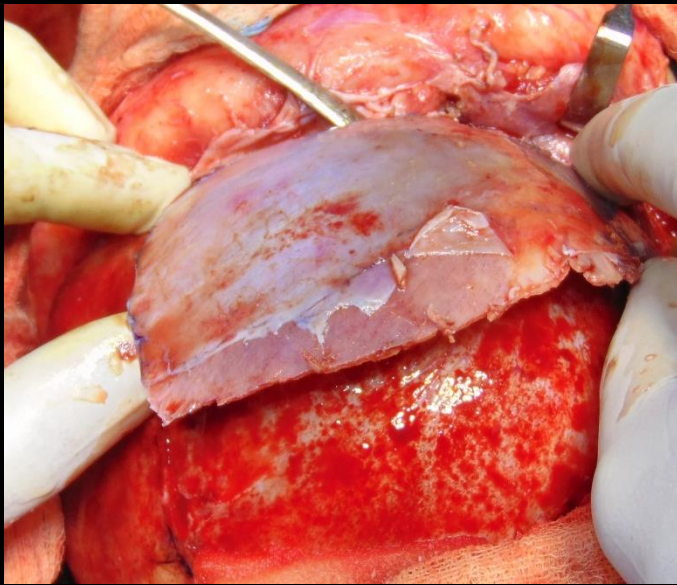
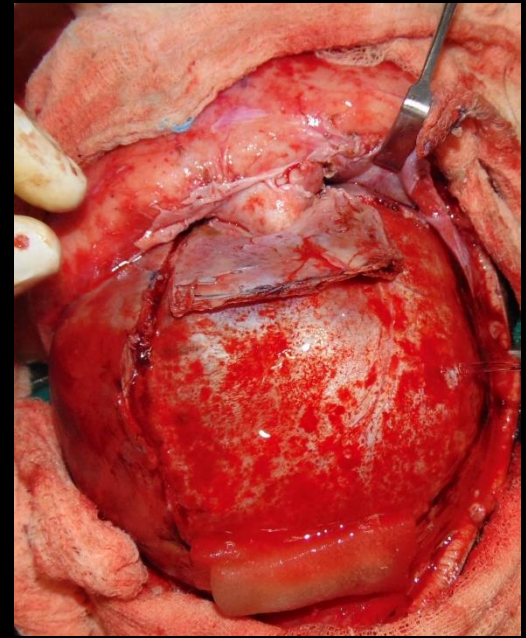
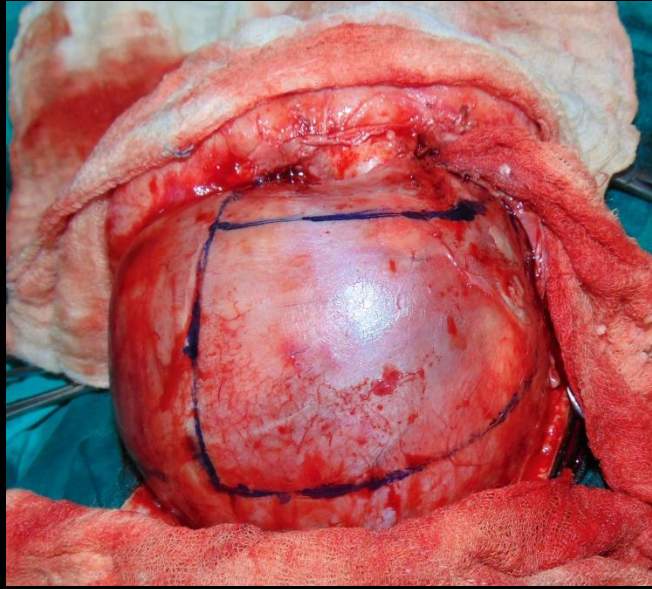
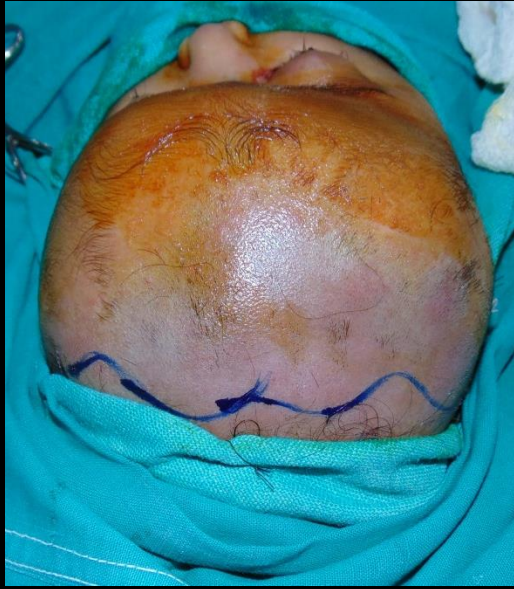External braces include helmet orthosis, cranial orthosis, cranial orthotic device, and orthotic headbands, which are known to be very effective for the correction of the asymmetrical shape of the head. At present, the total fronto-orbital reshaping, including the correction of the rotational deformity of the supraorbital area by multiple incomplete osteotomy and rigid fixation, has been performed.

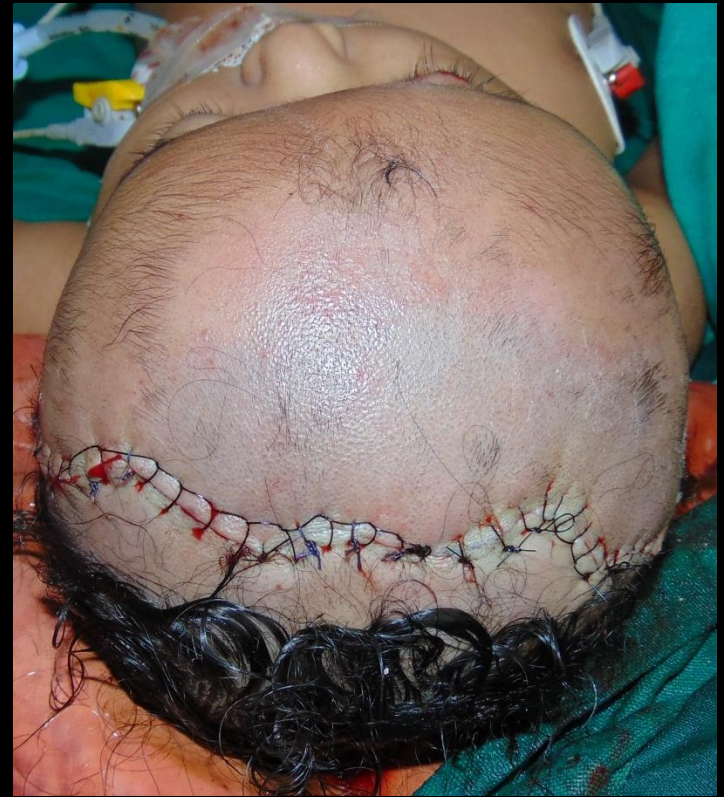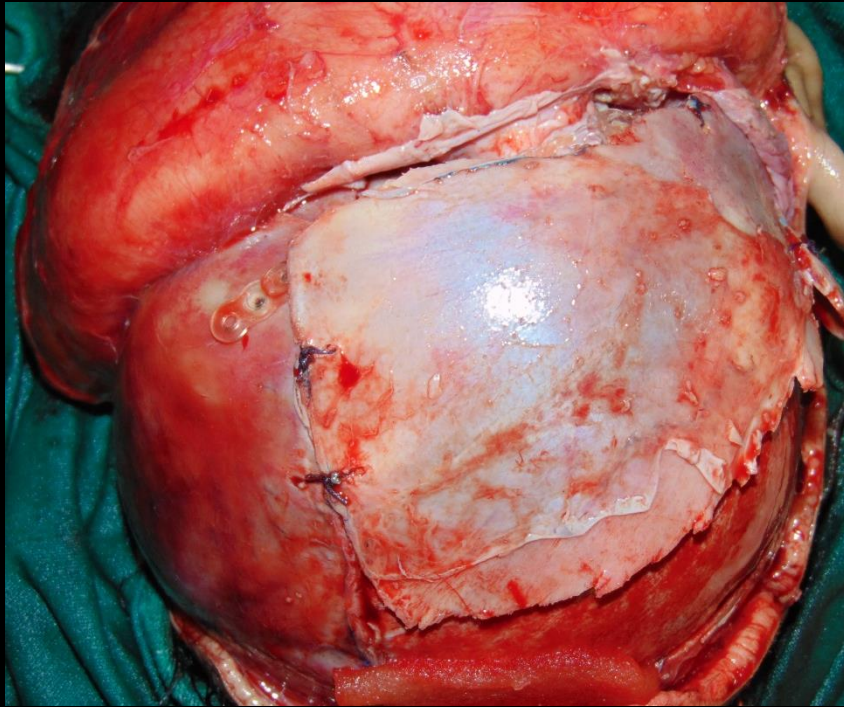


PLAGIOCEPHALY

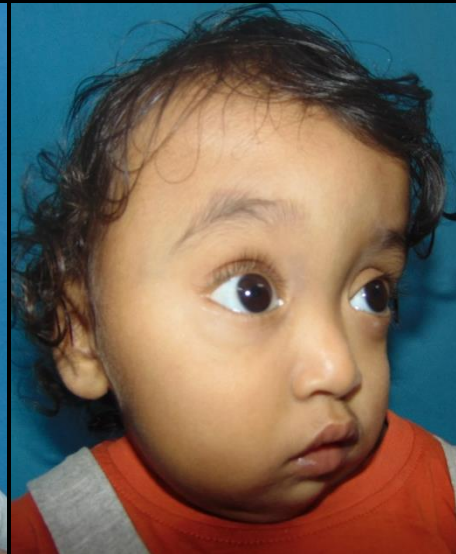
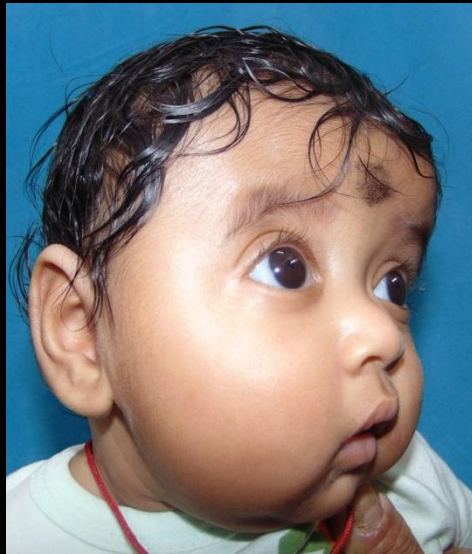
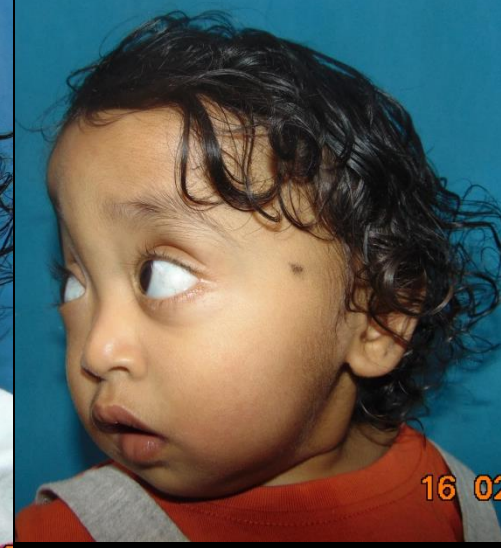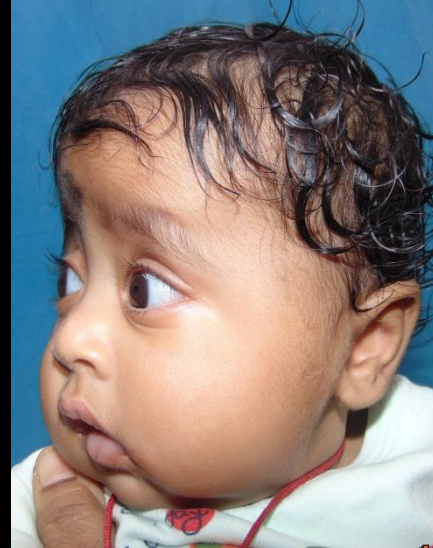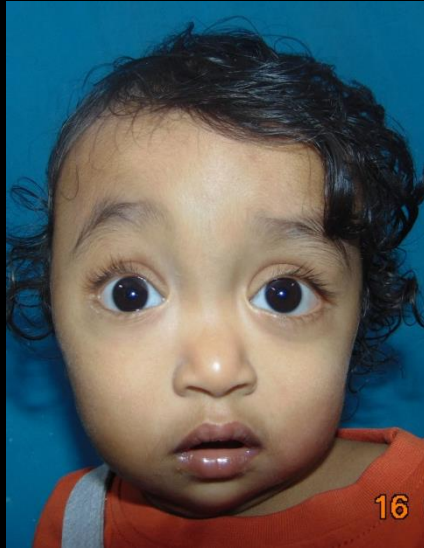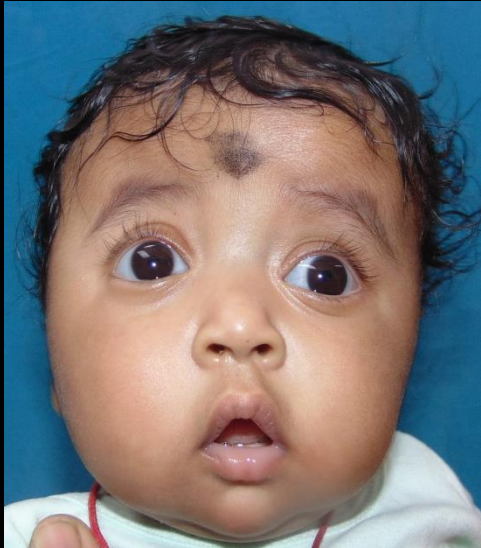PLAGIOCEPHALY





PLAGIOCEPHALY PREOP VS POST OP

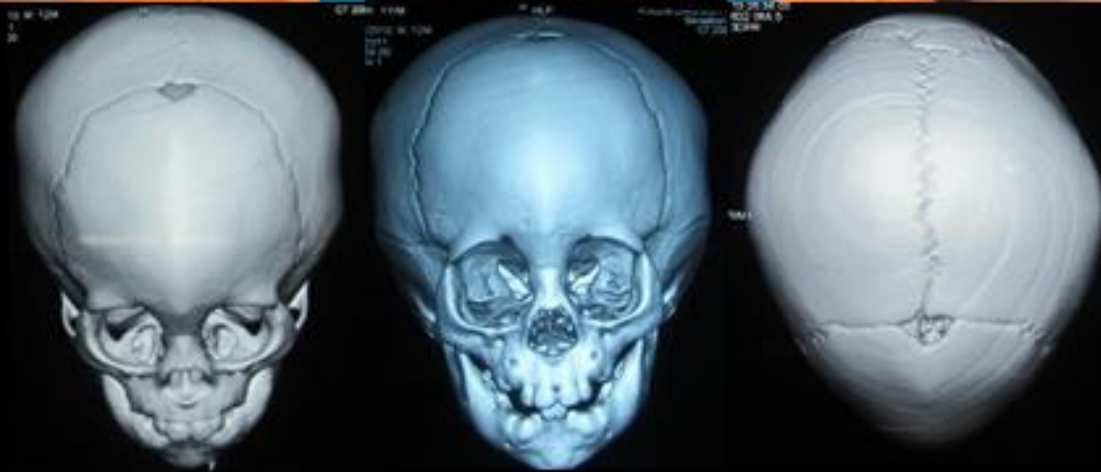
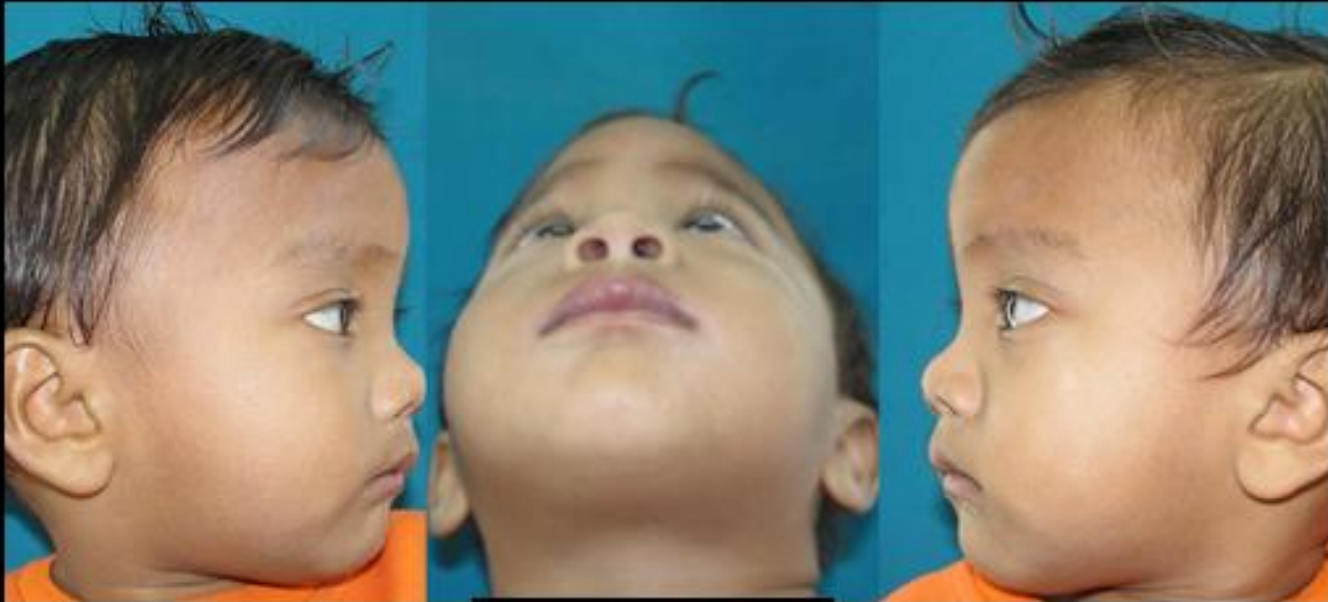

TRIGONOCEPHALY :

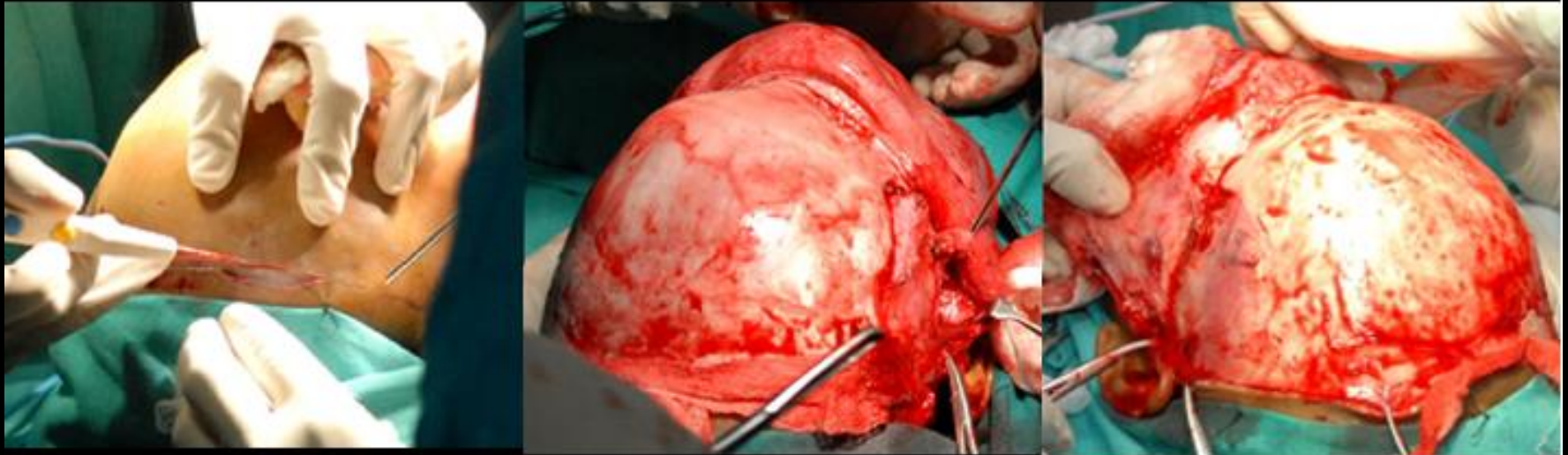
Surgical correction for metopic craniosynostosis also requires a frontal reconstruction that addresses the superior and lateral periorbital skeleton as well as the forehead .



TRIGONOCEPHALY

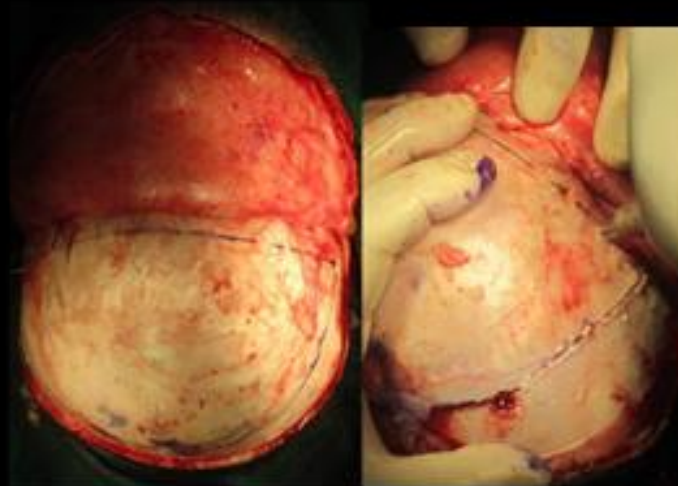


Bicoronal Incision

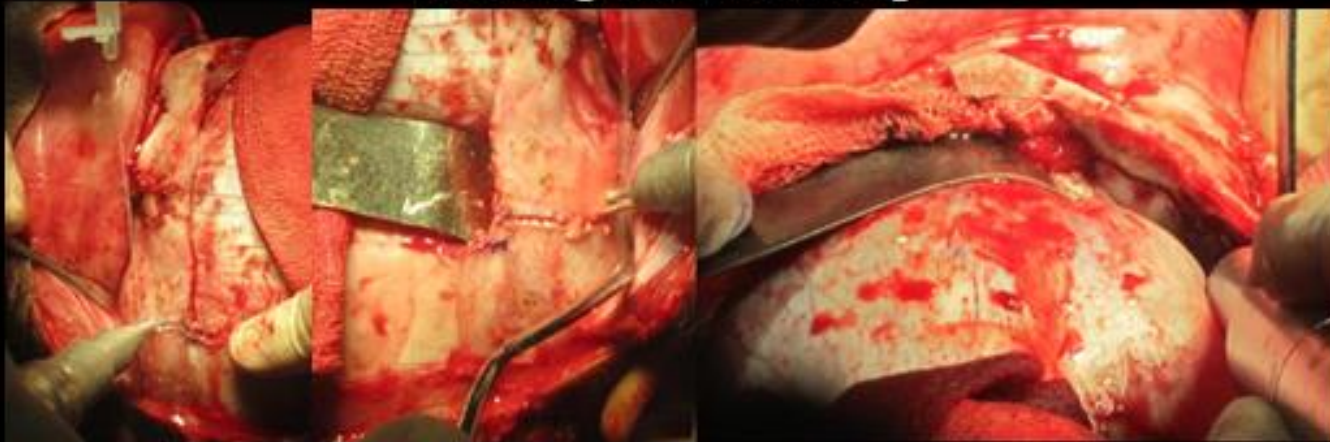


The skin incision for approaching the cranium, supraorbital area and the zygomatic area consists of bicoronal incision with the dissection as far forward and anterior as possible.



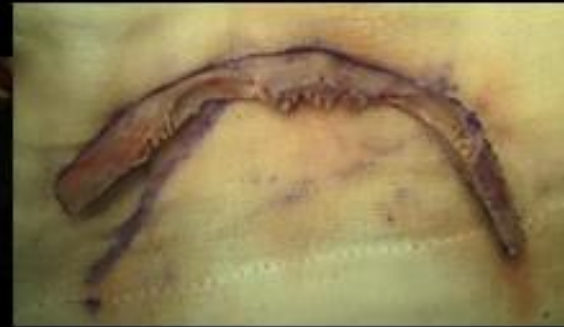
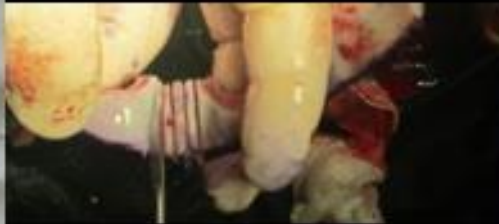
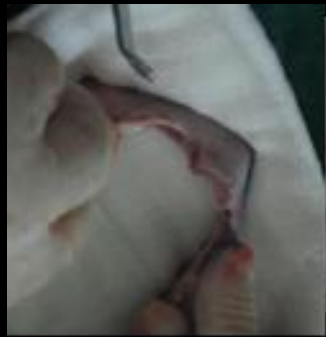Raising Frontal Flap

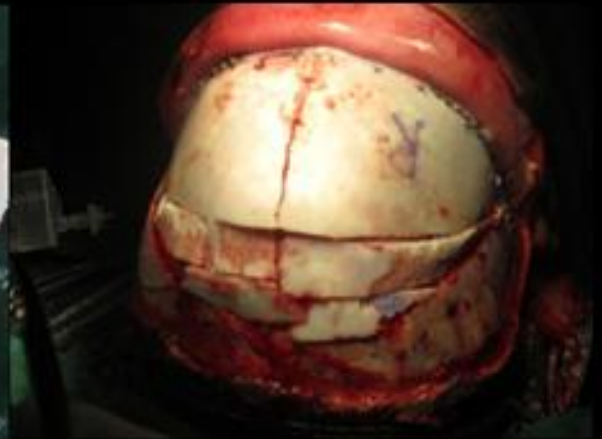
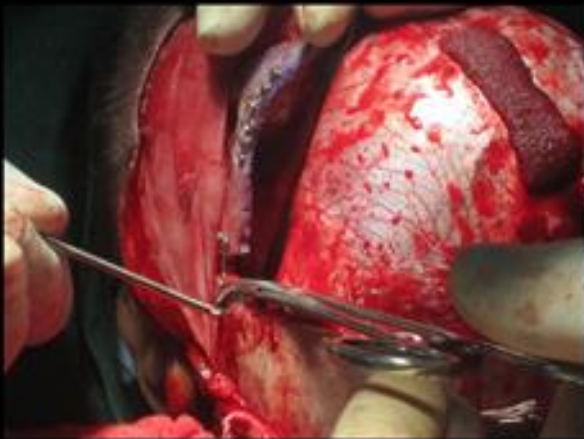
Harvesting supraorbital band





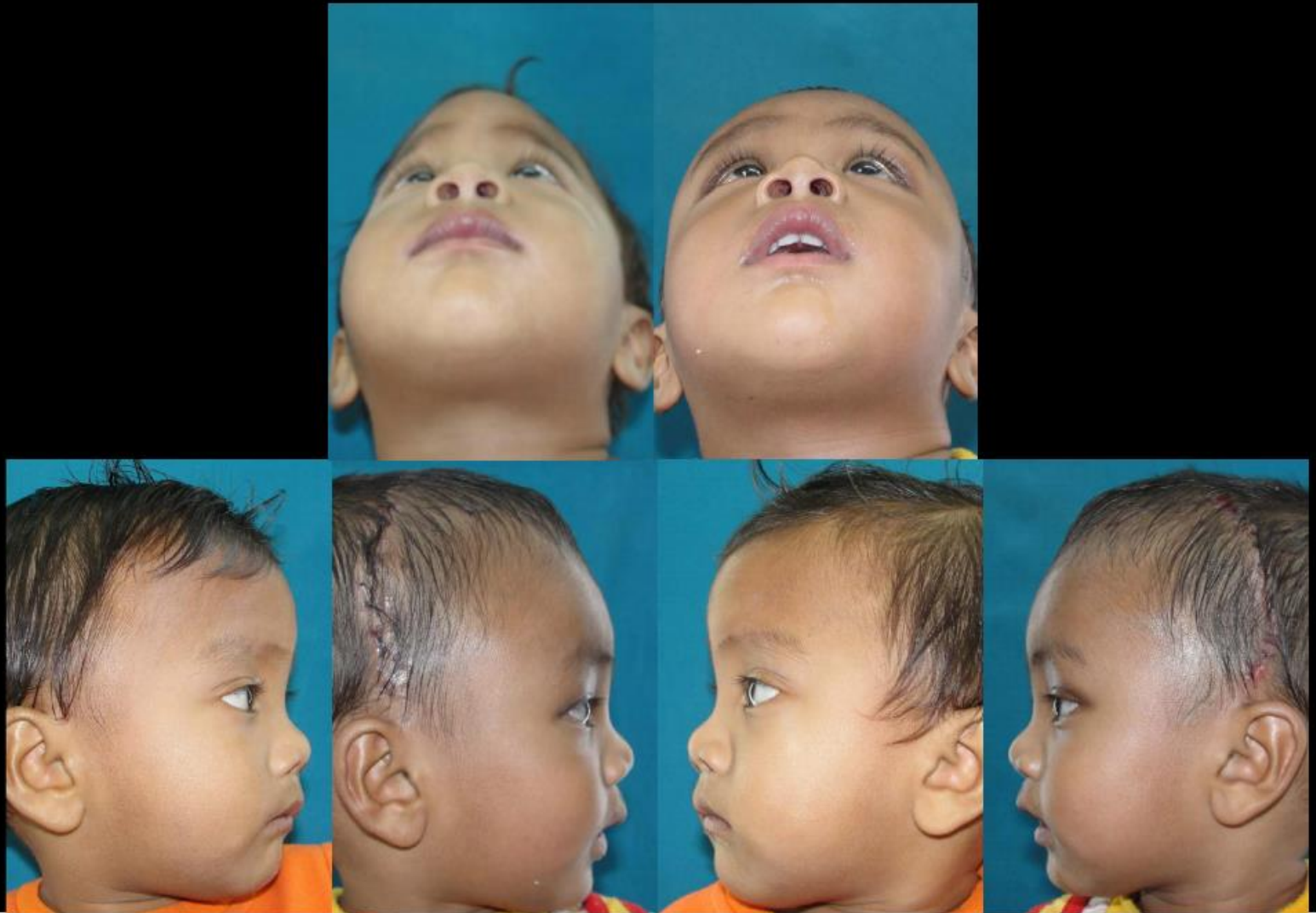Superior Orbital rim advancement and fixation



Fixation



TRIGONOCEPHALY

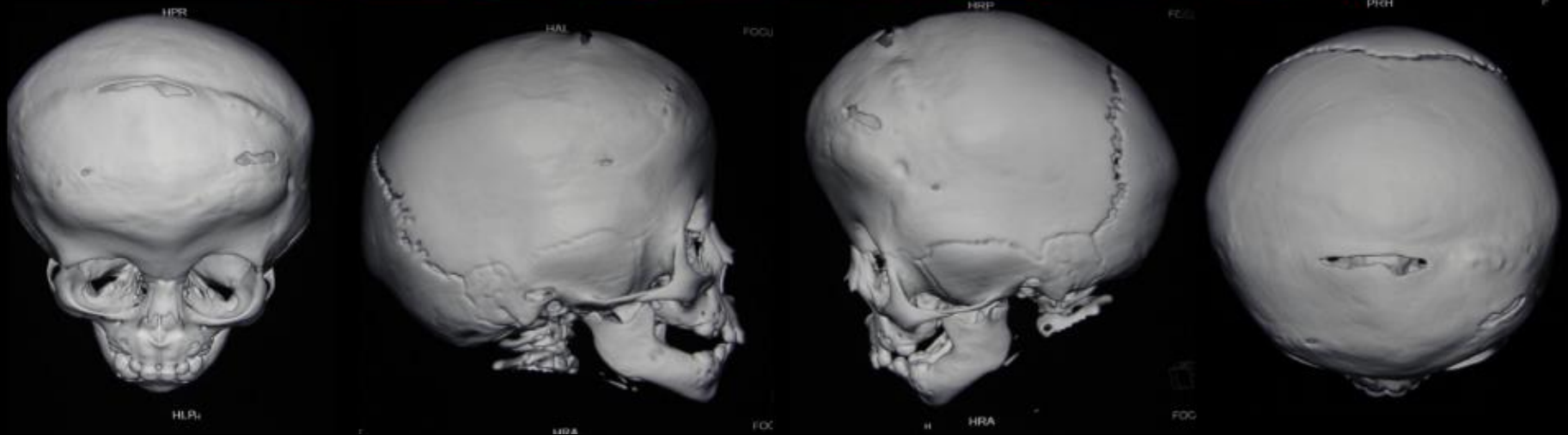
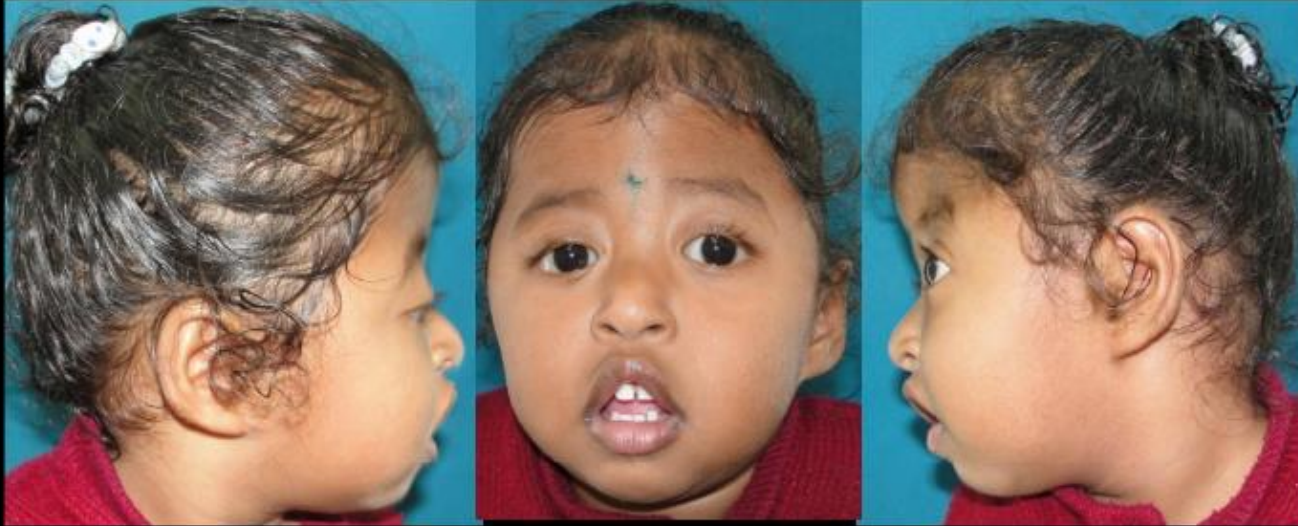

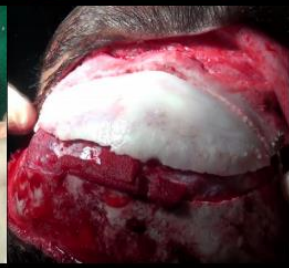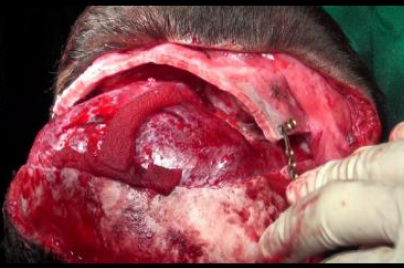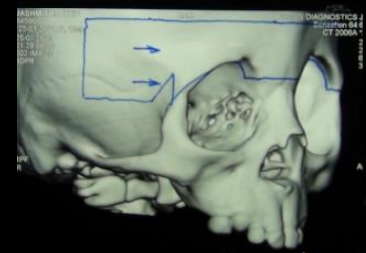
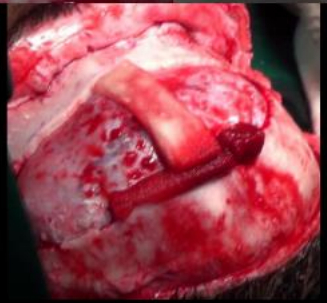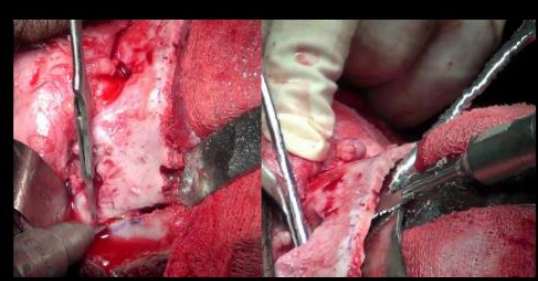
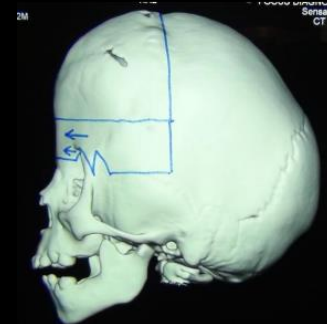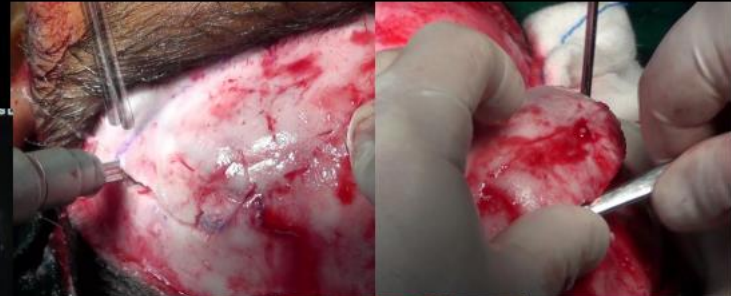BRACHYCEPHALY:

The **correction of unicoronal and bicoronal synostosis** requires a frontal reconstruction that addresses the superior and lateral periorbital skeleton as well as the forehead, classically described as **frontoorbital advancement**.



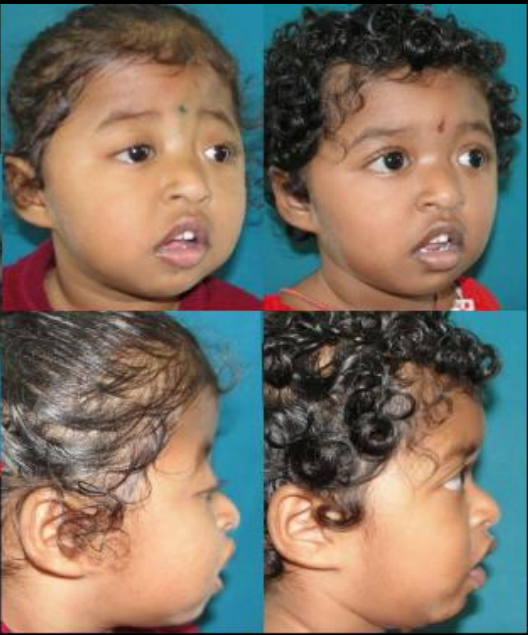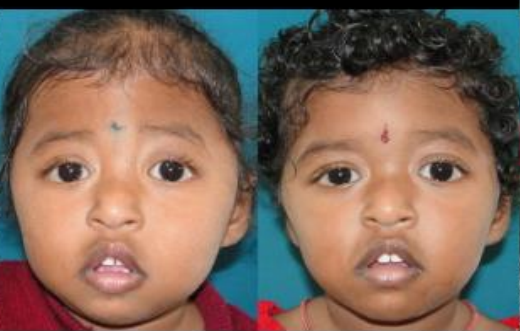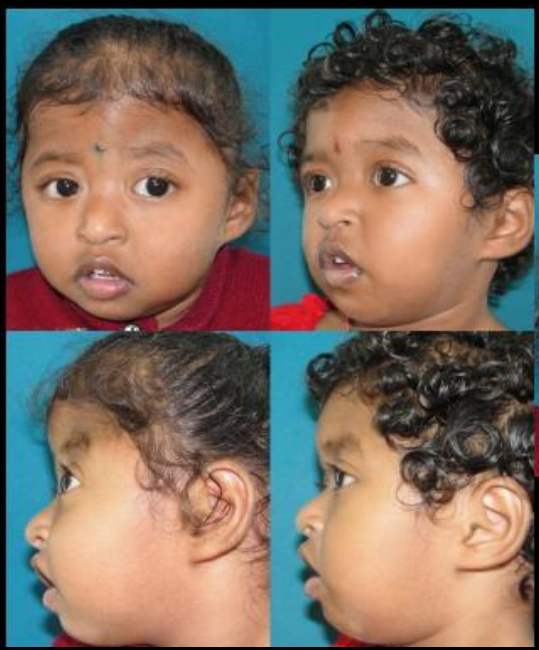BRACHYCEPHALY





Superior Orbital rim advancement and fixation

Raising Frontal Flap

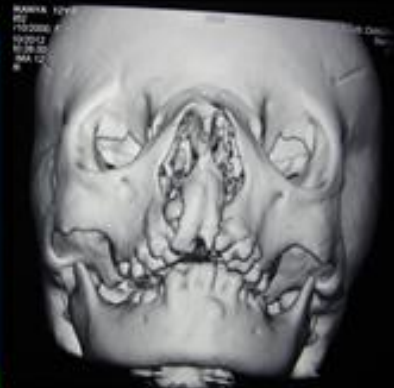
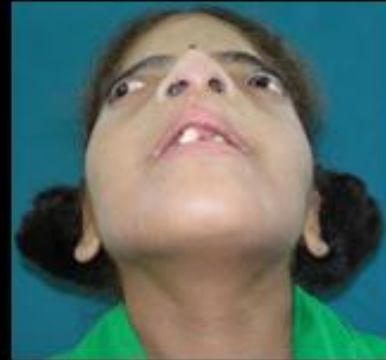
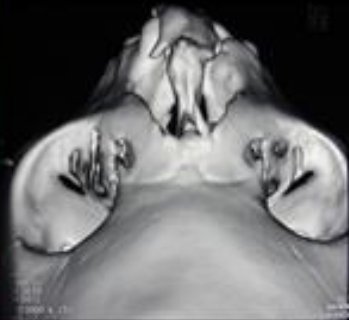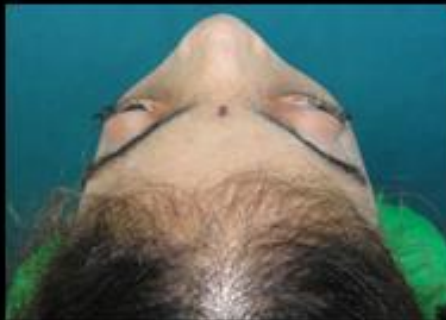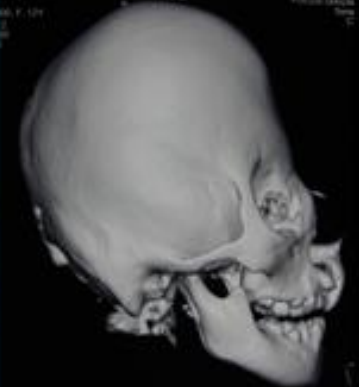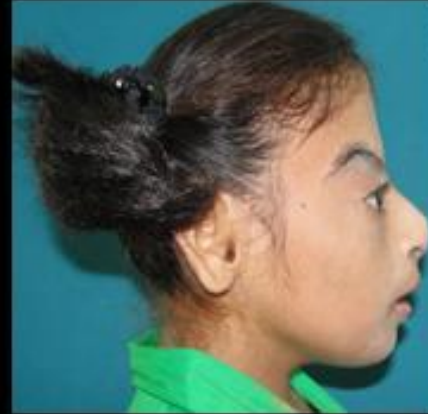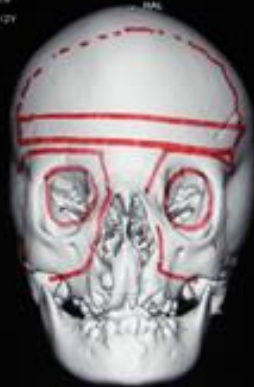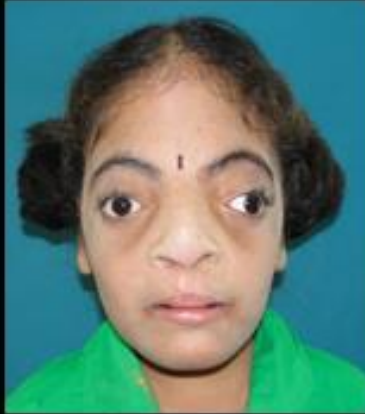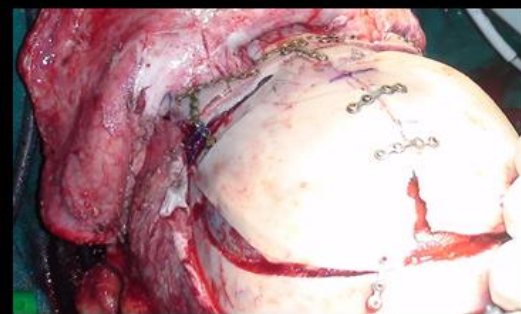
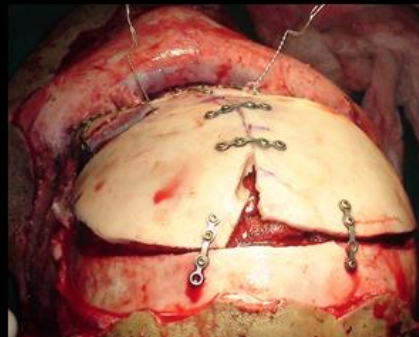
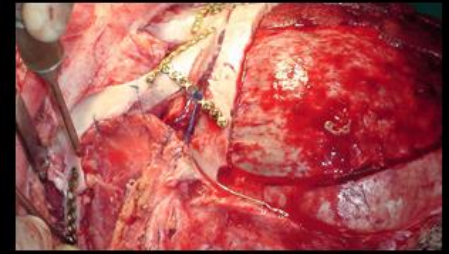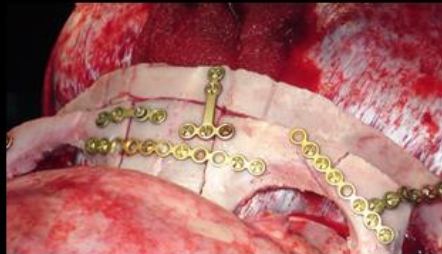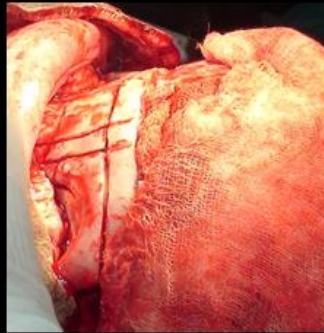
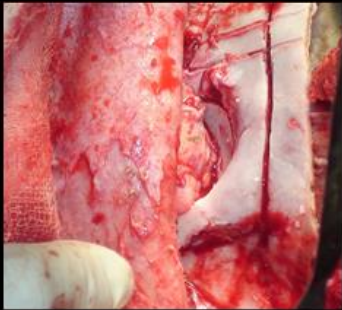
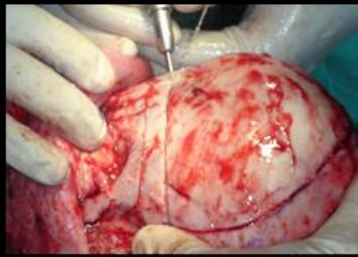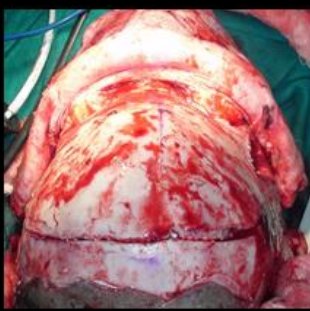
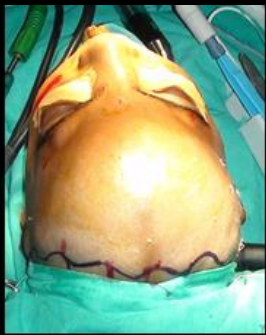OXYCEPHALY :

Posterior vault reconstruction is performed between 3 and 6 months of age in prone position. In the case of pansynostosis with delayed skull growth but normal shape, the surgical goal is creation of intracranial volume . A biparieto-occipital craniotomy is performed and distractors implanted that span the bone cut. After 30 days, distraction osteogenesis results in 3 cm of new bone . Distraction may also be used anteriorly to advance the anterior skull base and midface as a unit in a procedure called monobloc.

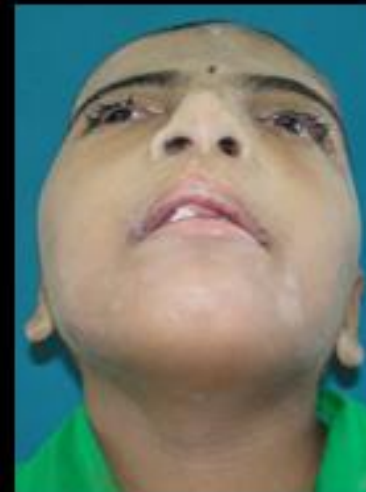
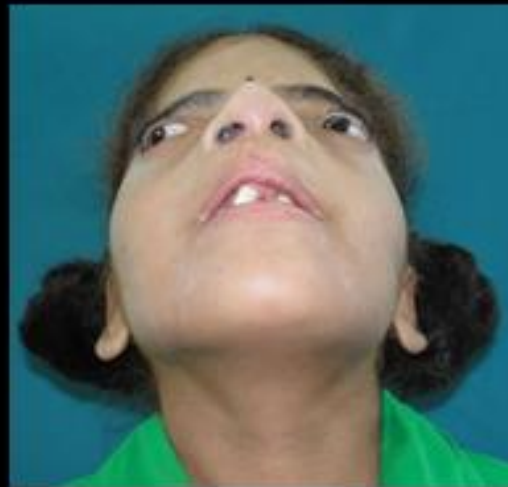
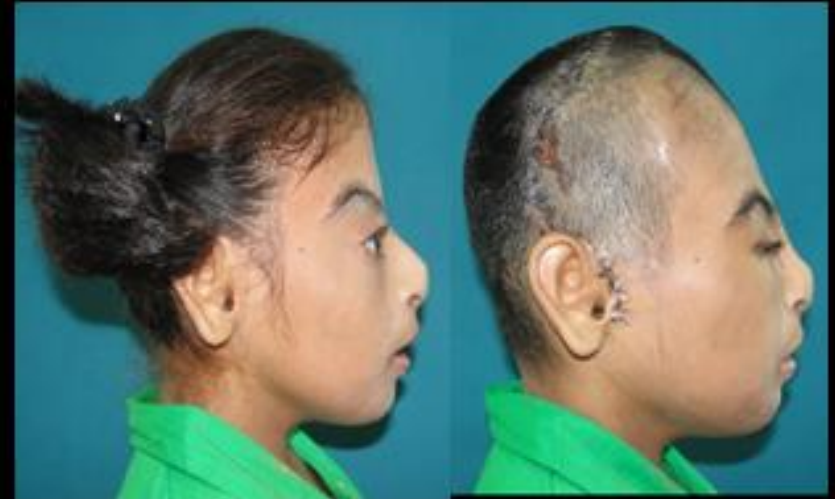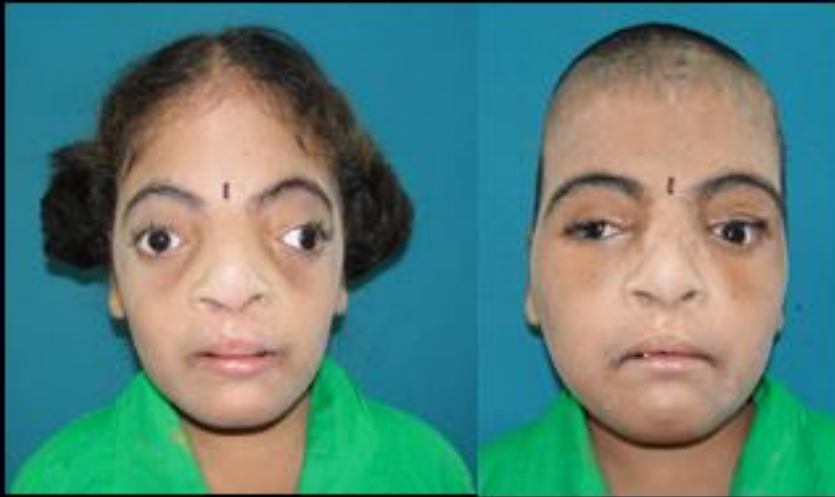OXYCEPHALY WITH HYPERTELORISM CORRECTION

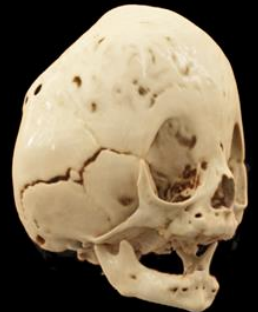
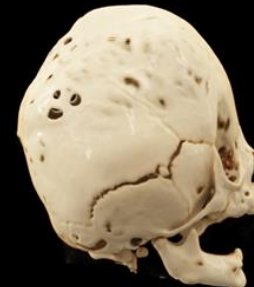
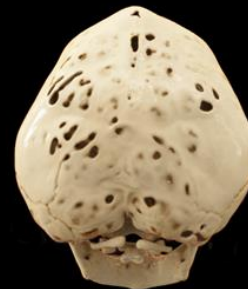
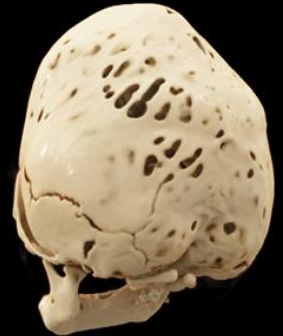
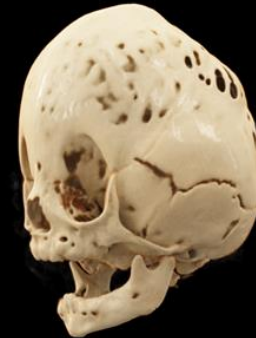
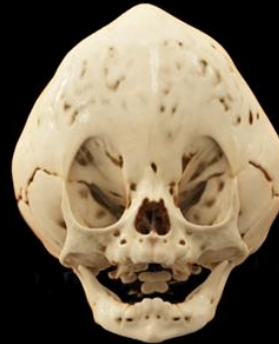
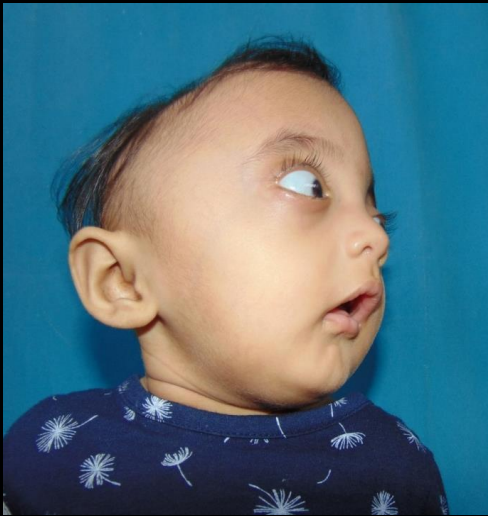
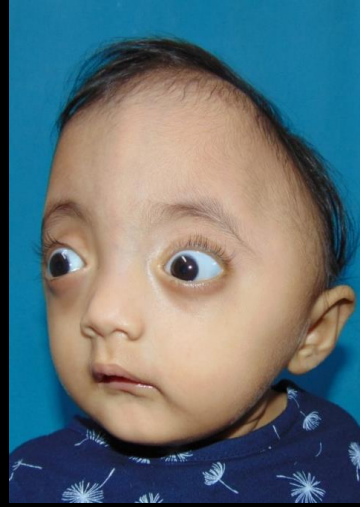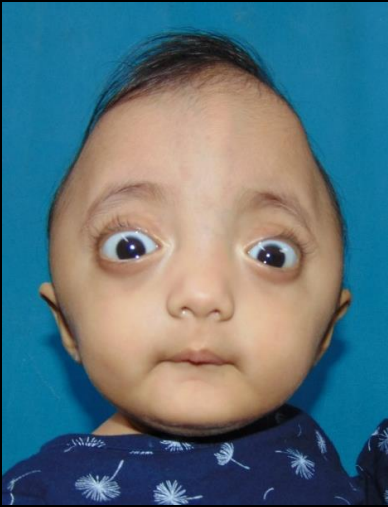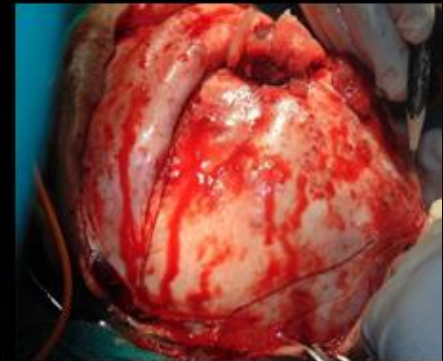
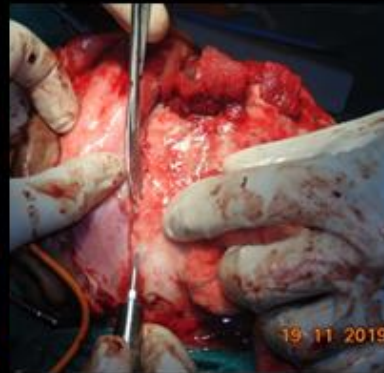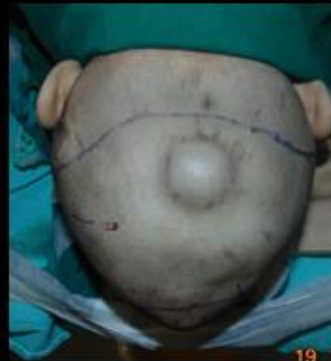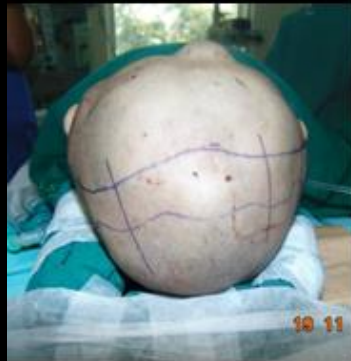OXYCEPHALY WITH HYPERTELORISM CORRECTION



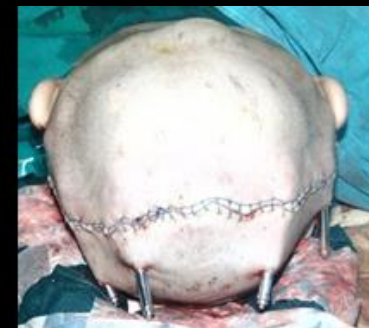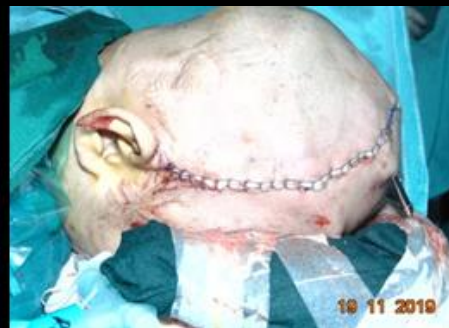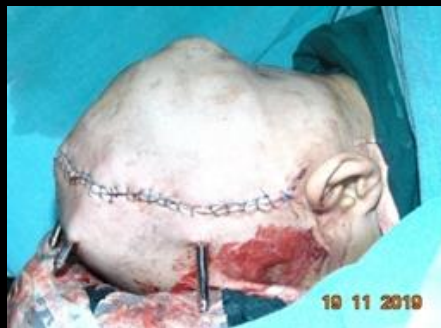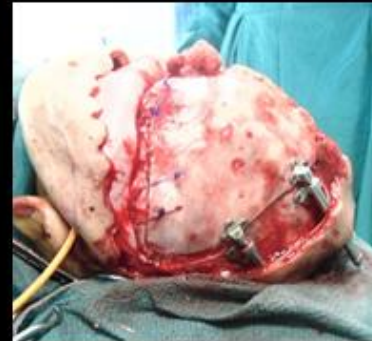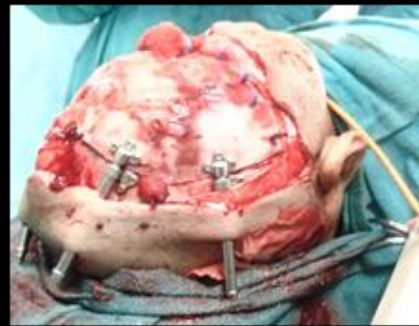CRANIOSYNOSTOSIS (TURRICEPHALY) POSTERIOR CRANIAL VAULT DISTRACTION



INCISION MARKING



DISTRACTOR PLACEMENT

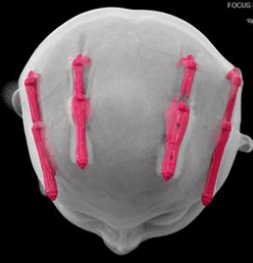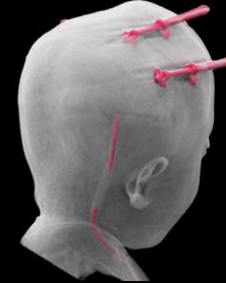
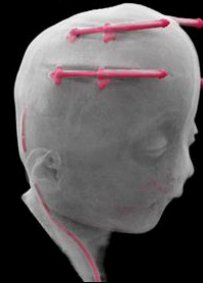
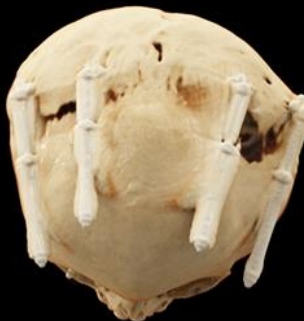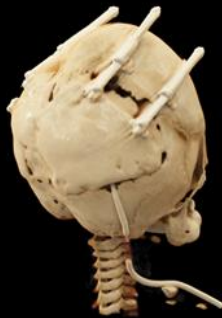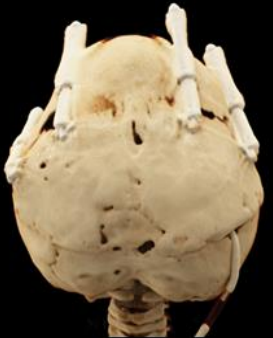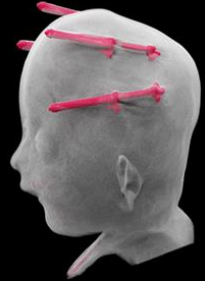
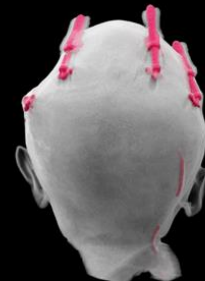


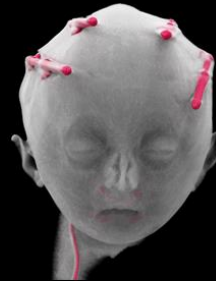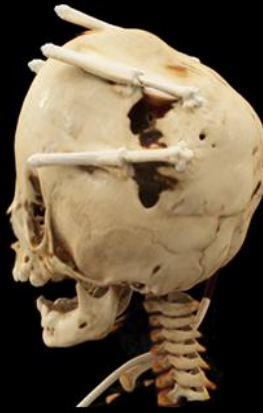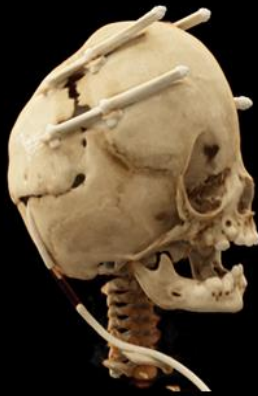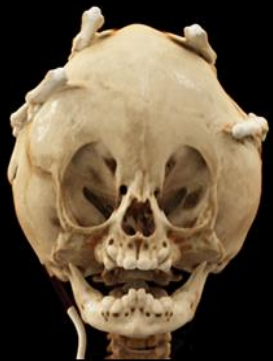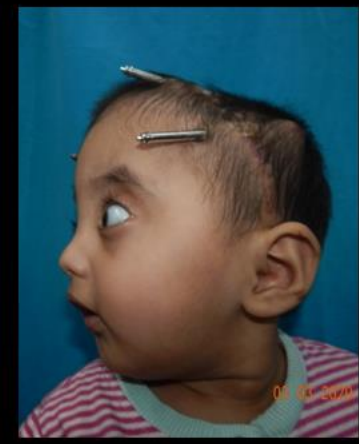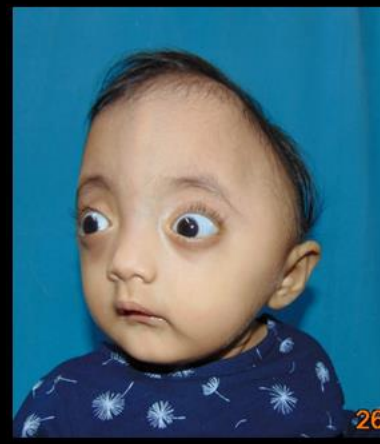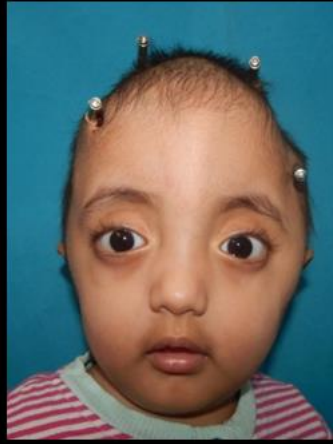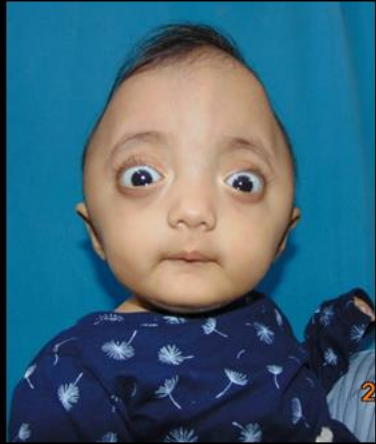PRE-OP

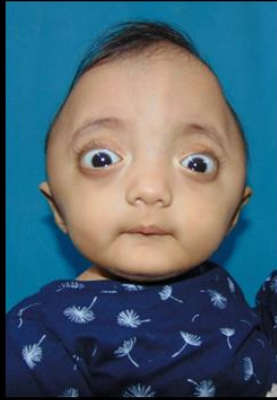POST-DISTRACTION

PRE-OP

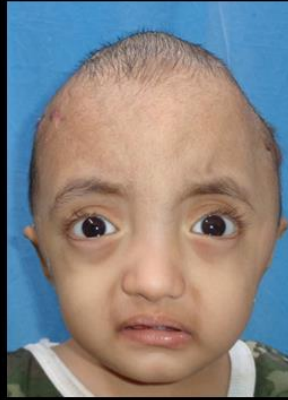POST-DISTRACTION



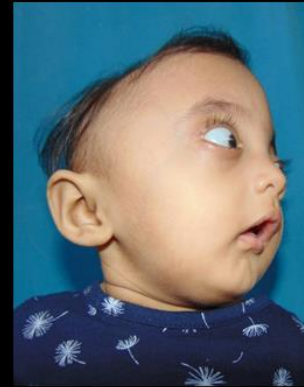PRE-OP



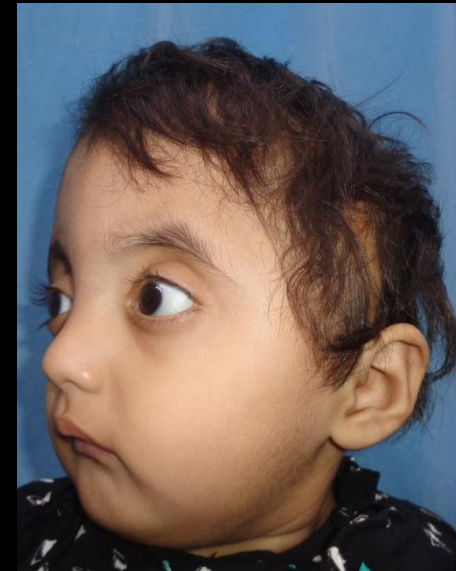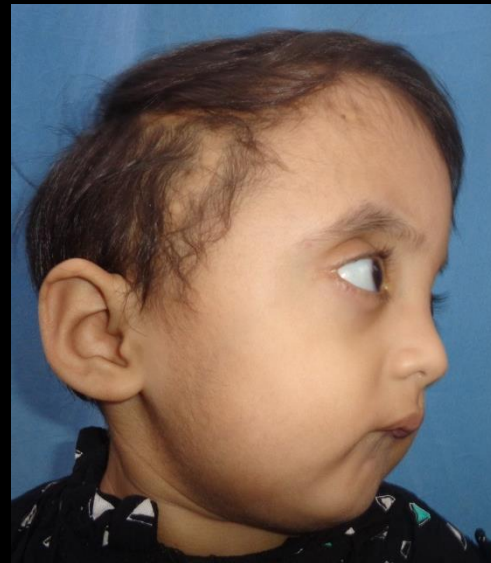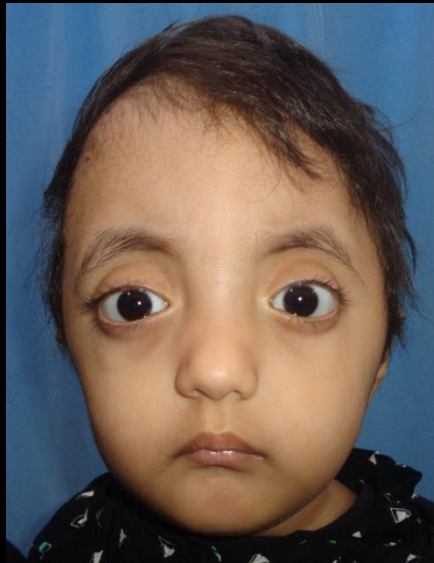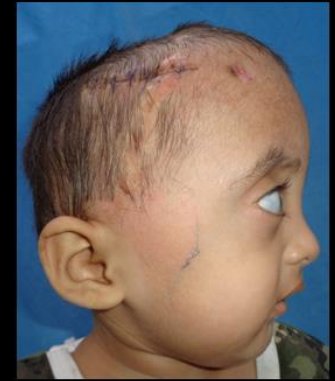POST DISTRACTOR
REMOVAL



PRE-OP



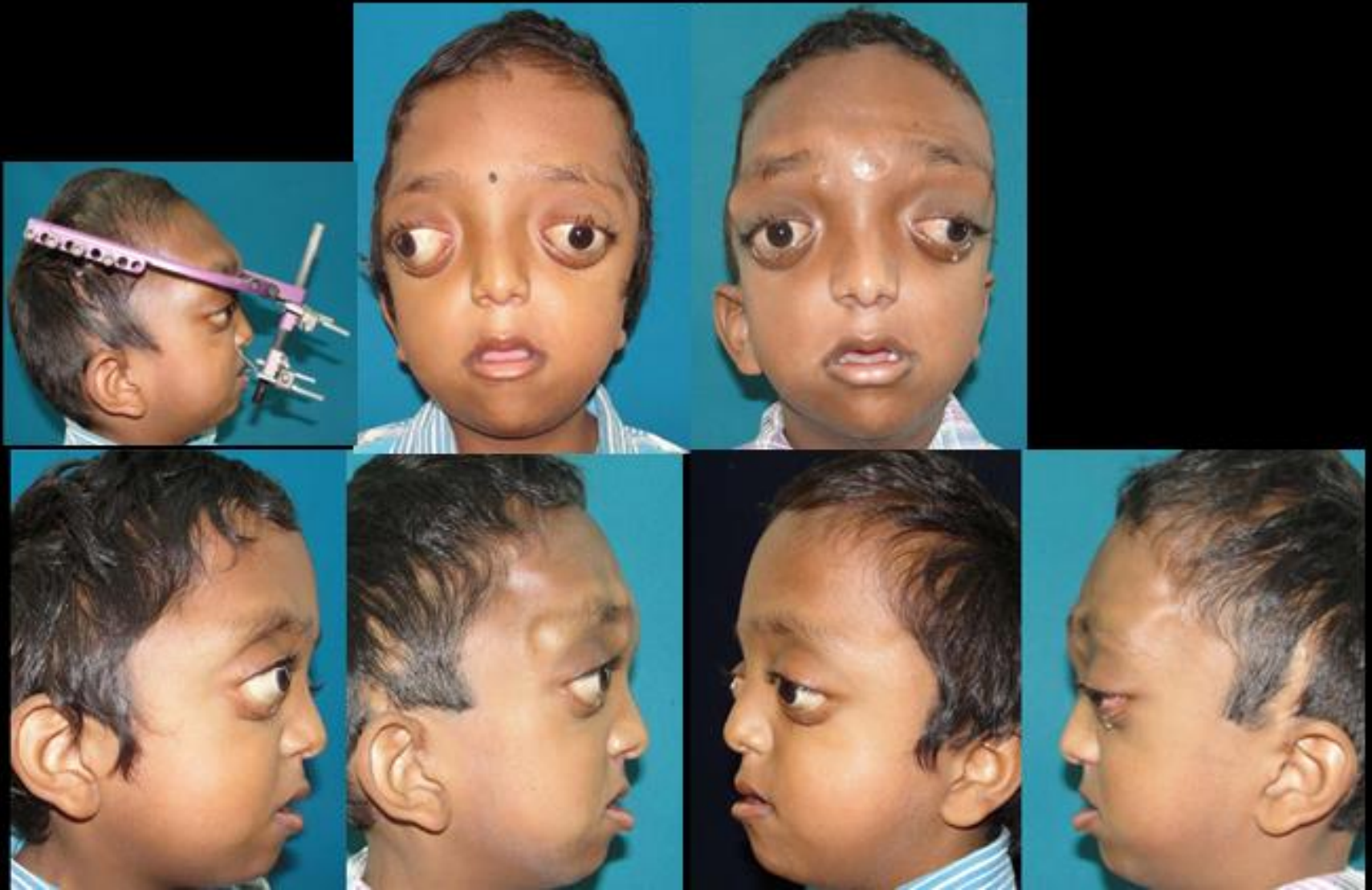POST DISTRACTOR
REMOVAL

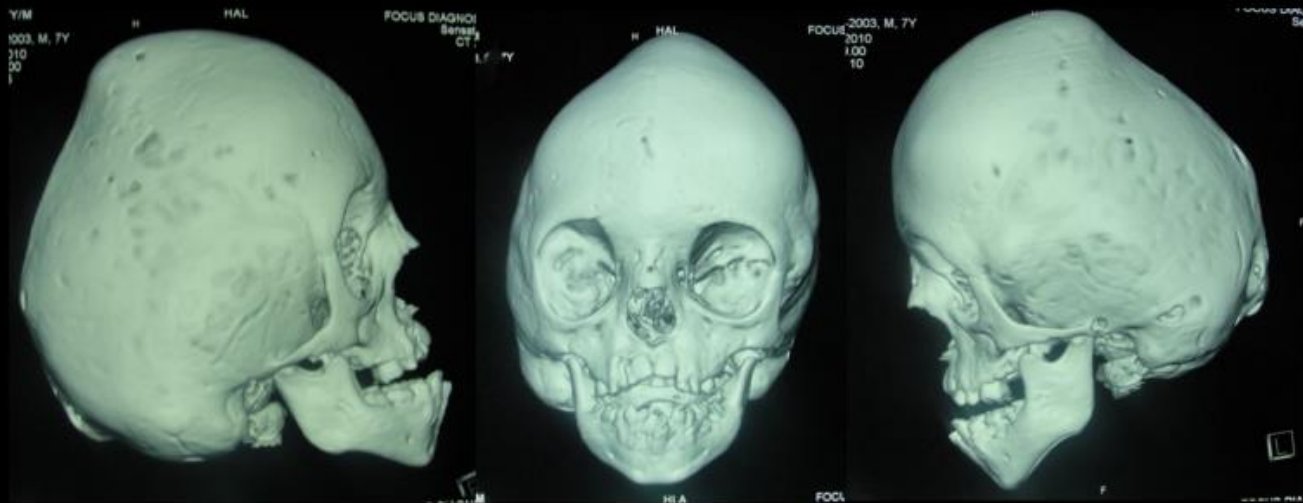
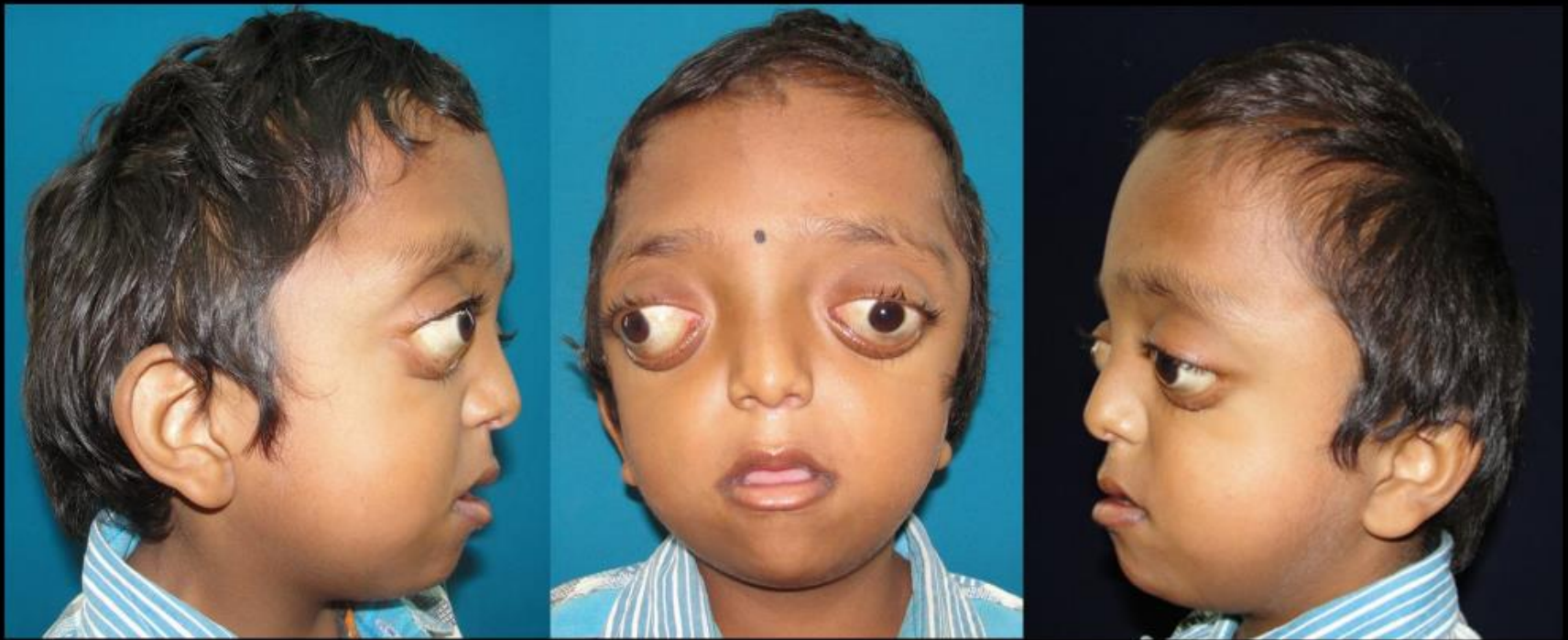
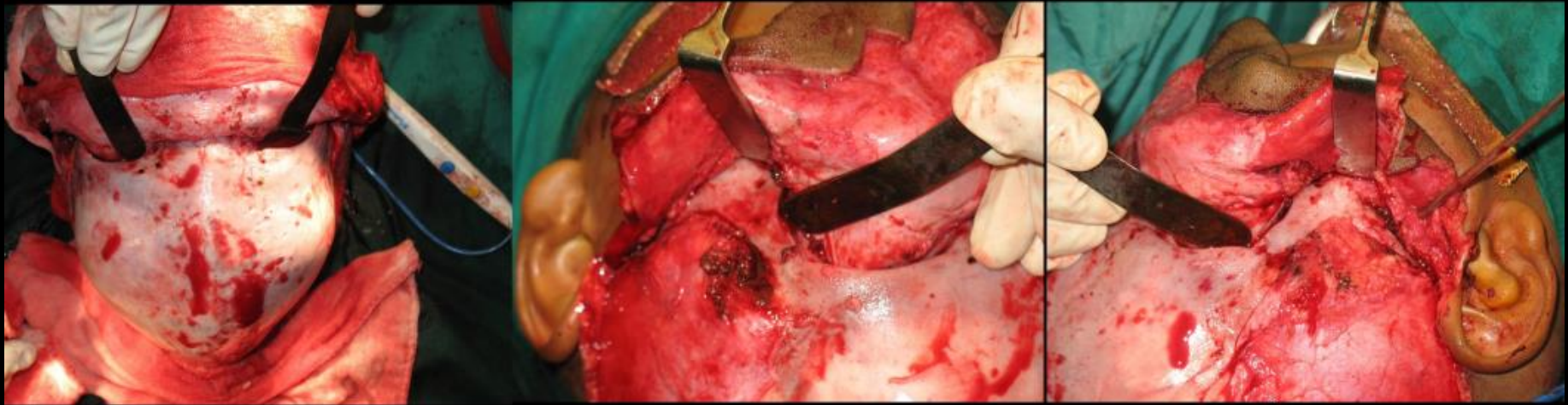
LATEST POST OP



CROUZAN SYNDROME

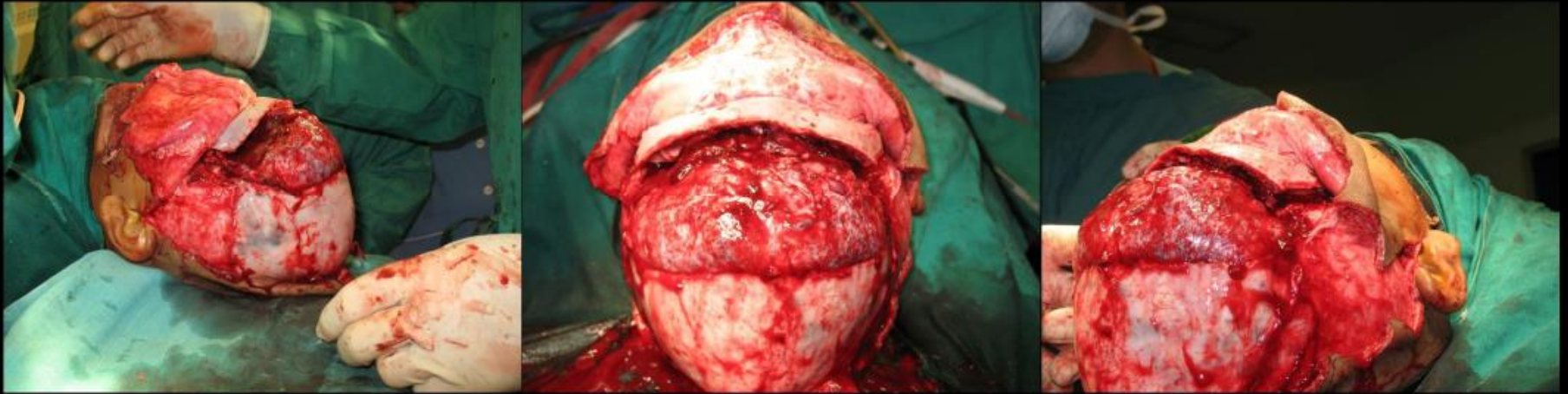





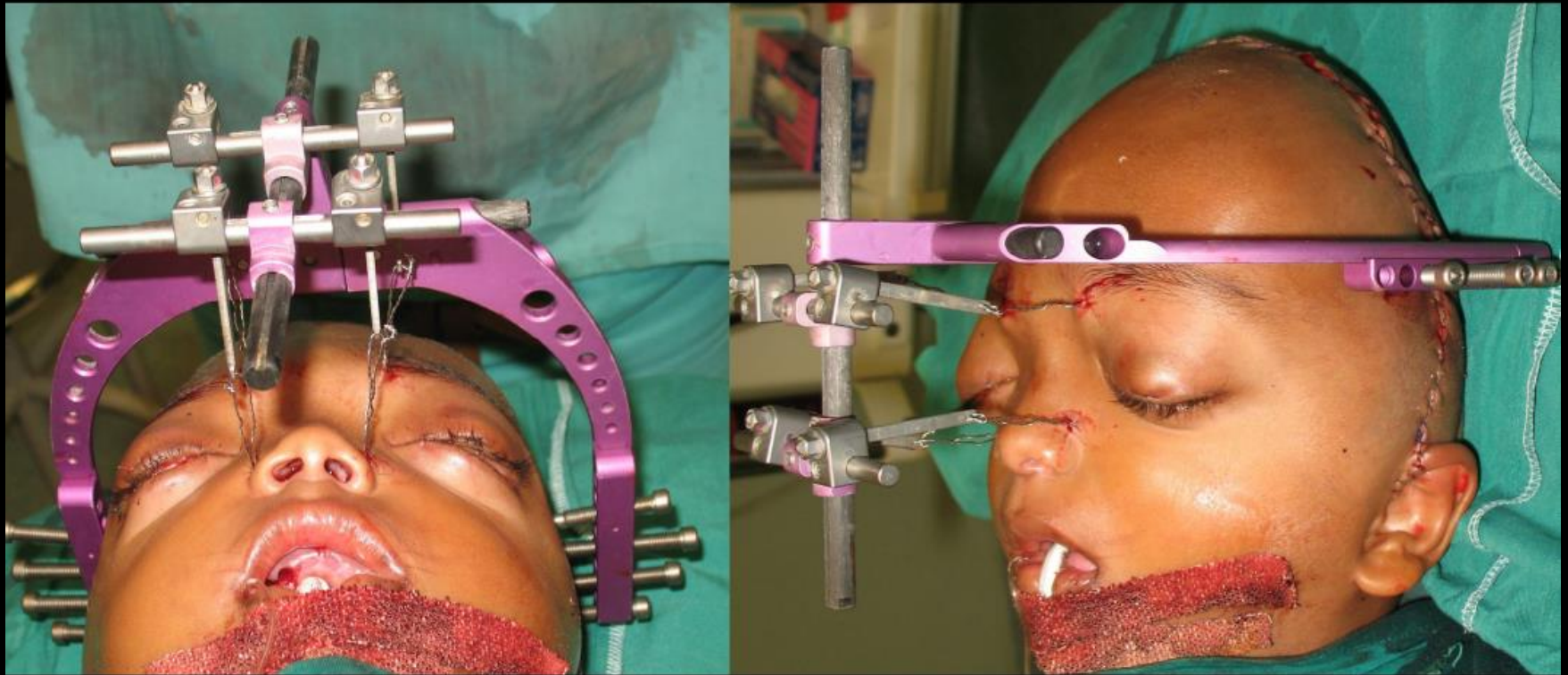- The exposure the same as that is done for facial bipartition





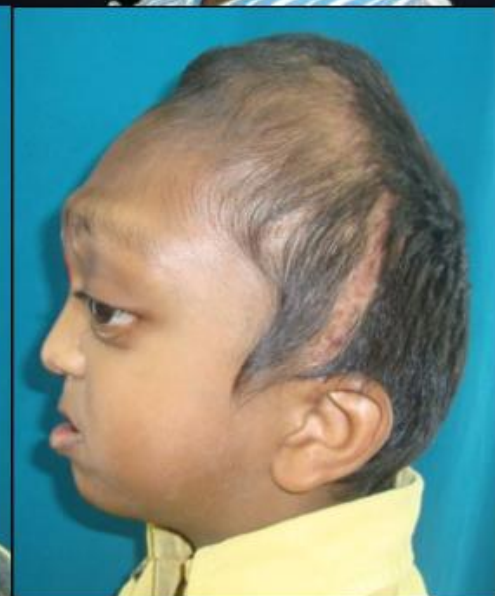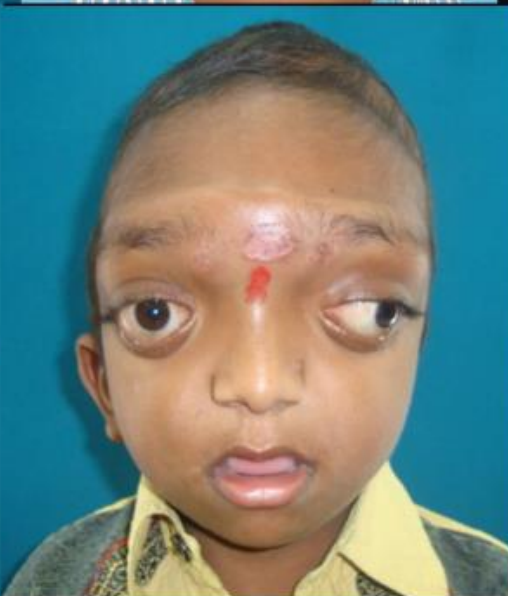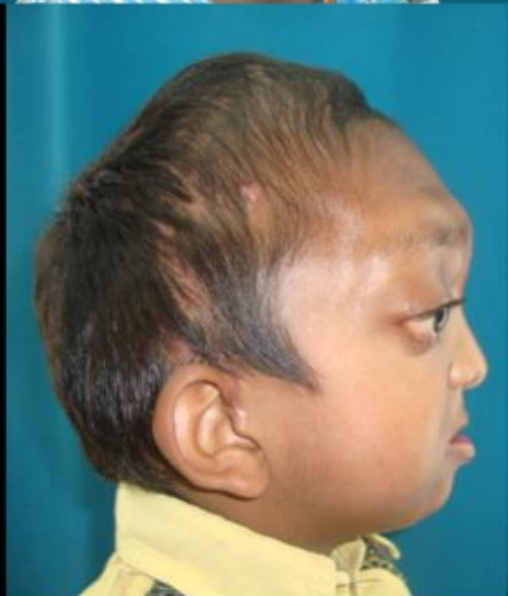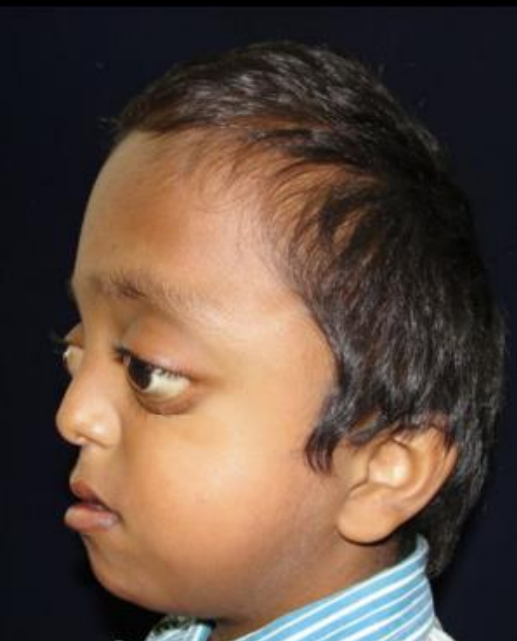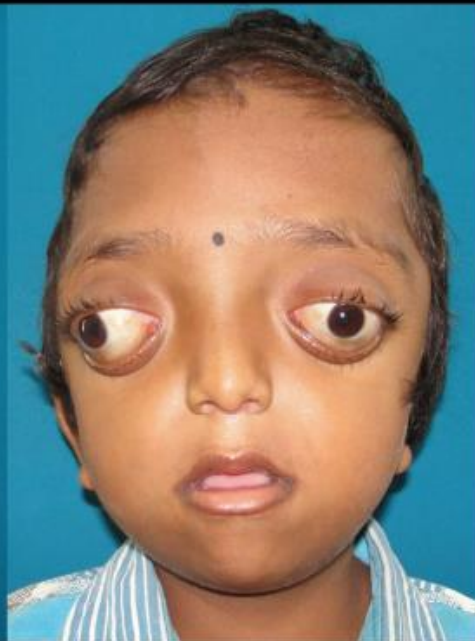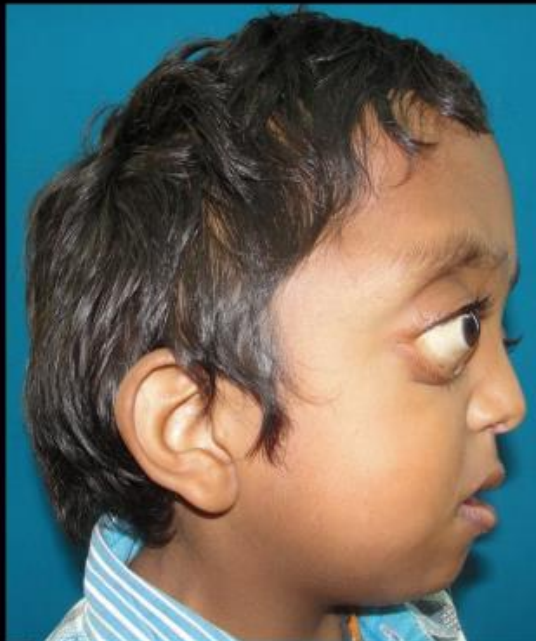- The lateral osteotomies are same as those done for facial bipartition.
- No medial cuts are given ensuring that the osteotomised complex is moved antero-posteriorly as a single block





- Distractor in place
- Distraction was preferred because of the amount of movement required, the dead space the movement would have resulted in and poor quality of bone already present.



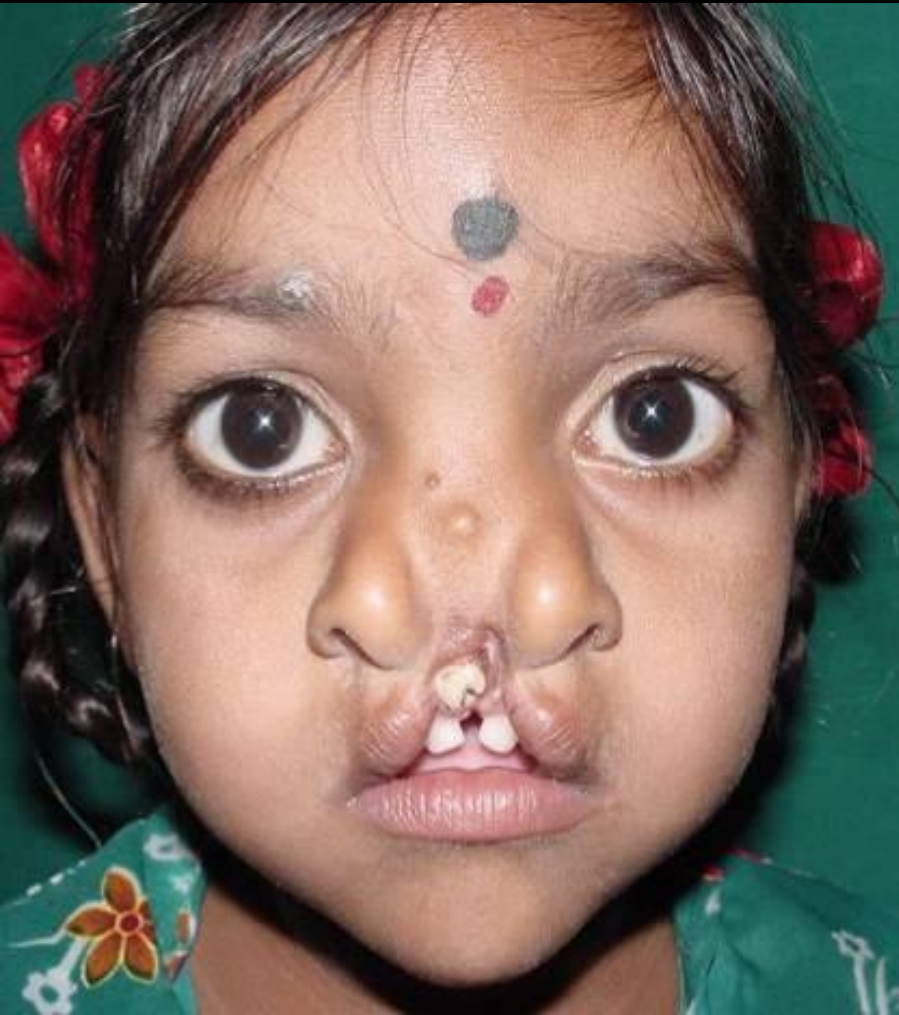

COMPLICATION POST OPERATIVELY:

- Wound infection
- Intraoperative bleeding
- Postoperative
hematoma (subgaleal, subdural)
- Intraoperative/postoperative
hyperthermia
- Dural tear
- Cerebrospinal fluid leak
- Meningitis
- Postoperative mortality: 2.6%
- Postoperative morbidity: 12%



Bring the Smile Back



Thank You