CRANIOFACIAL SURGERY

What?Where?When?Who? And How?

Prof. Dr. Dr. Srinivas Gosla Reddy
MBBS, MDS, FRCS (Edin.), FDSRCS (Edin), FDSRCS (Eng), PhD

Dr. Rajgopal R. Reddy MBBS, BDS, FDSRCPS (Glasg) PhD
Dr. Ashish Fanan MDS
Dr. Avni Pandey MDS
Dr Madhav Thumati, MDS

GSR Institute of Craniofacial Surgery,
Hyderabad, India.

Craniofacial Surgery

What?

Where? When? Who? And How?

Craniofacial Anomalies

Abnormalities of the Head and Neck region

Congenital

With clefting

- Cleft lip and palate
- Craniofacial clefts

Without clefting

- Treacher Collins syndrome
- Cruzons syndrome
- Aperts syndrome

Acquired

Trauma

Neoplasms

- Benign
- Malignant

Craniofacial Surgery

Where?

What?.....When? Who? And How?

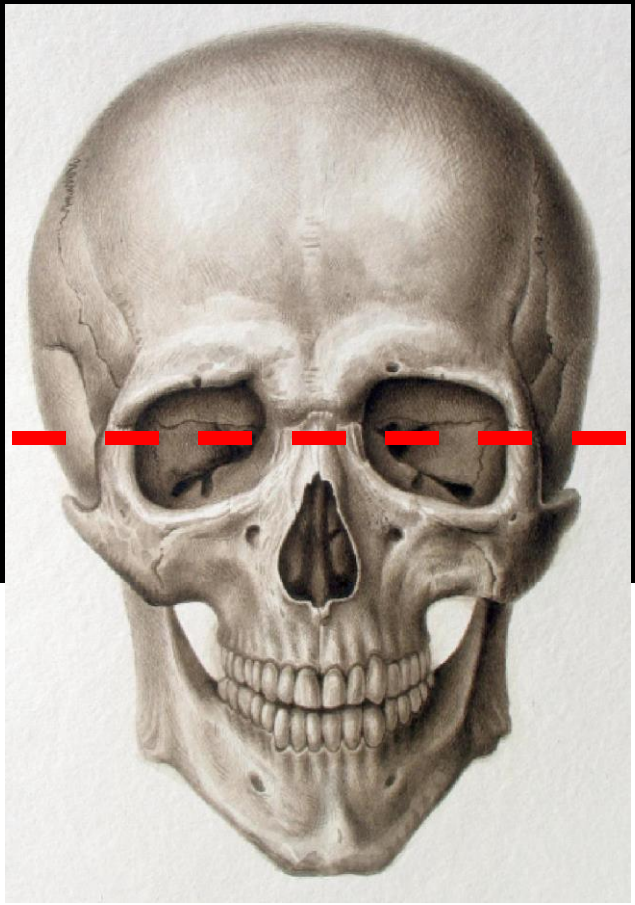

MAXILLOFACIAL SURGERY

maxillofacial and craniofacial

www.craniofacialinstitute.org

Craniofacial Anomalies

- Craniosynostosis

Plagiocephaly/Trigonocephaly/Scaphocephaly/Brachycephaly

- Craniofacial Dysostosis

Crouzon Syndrome/Apert Syndrome/Pfeiffer Syndrome/Cloverleaf skull

- Craniofacial Syndromes and Anomalies

Treacher Collins Syndrome/Hemifacial Microsomia/Binder Syndrome/Pierre Robin Sequence/Craniofrontonasal Dysplasia/Craniofacial Clefts

- Cleft Lip and Palate
- Benign and Malignant Head and Neck Tumors

Encephaloceles/Dermoid cysts/Hemangiomas/Vascular Malformations/Fibrous Dysplasia/Sarcoma and other malignancies

- Craniomaxillofacial Trauma
- Non-syndromic Orthognathic Deformities

Classification Craniofacial Synostosis and Dysostosis

Tessier divided the craniofacial framework into five levels
Classified Synostosis and Dysostosis topographically and anatomically into six groups

Tessier's classification	**Levels of malformation**
Class 1: isolated cranial vault dysmorphism	Level A
Class 2: syndromic orbitocranial dysmorphism	Level B
Class 3: asymmetric orbitocranial dysmorphism	Level B and C
Class 4: Saethre-Chotzen group	Level A-C
Class 5: Crouzon group	Level A-D
Class 6: Apert group	Level A-E

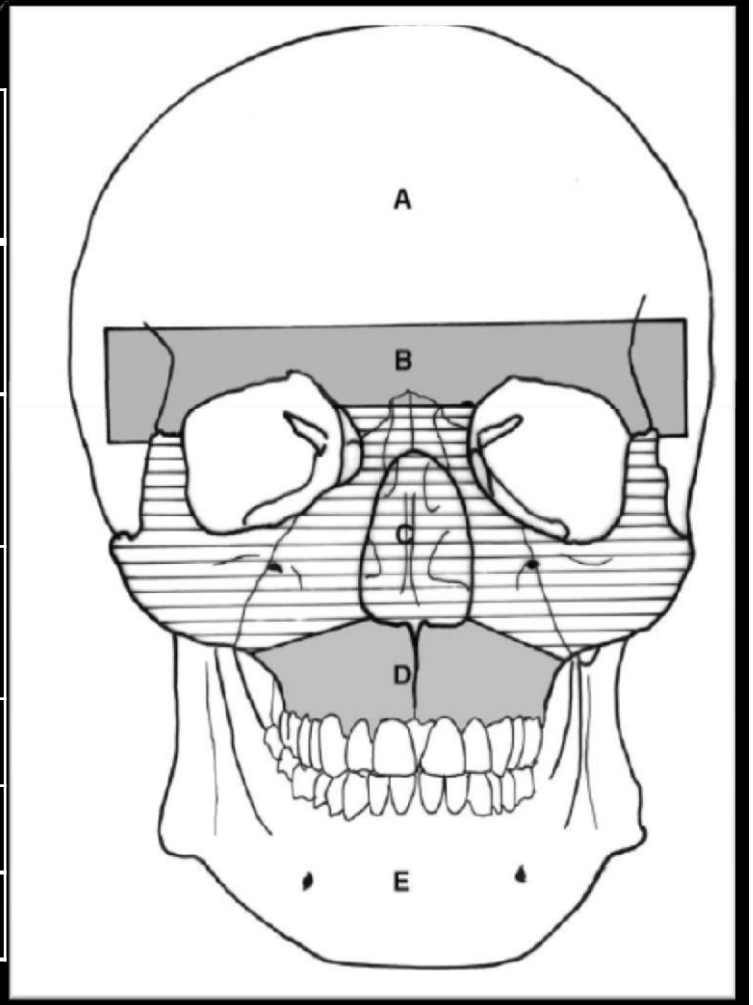

Craniosynostosis

Plagiocephaly/Trigonocephaly/Scaphocephaly/Brachycephaly

Premature fusion of cranial sutures

Plagio~	=	Oblique shaped	=	Unilateral coronal or lambdoid suture synostosis
Trigon~	=	Triangular shaped	=	Metopic suture synostosis
Scapho~	=	Boat shaped	=	Sagittal suture synostosis
Brachy~	=	Flat shaped	=	Coronal suture synostosis

Irregular shaped head → CT Scan Skull → Suture synostosis

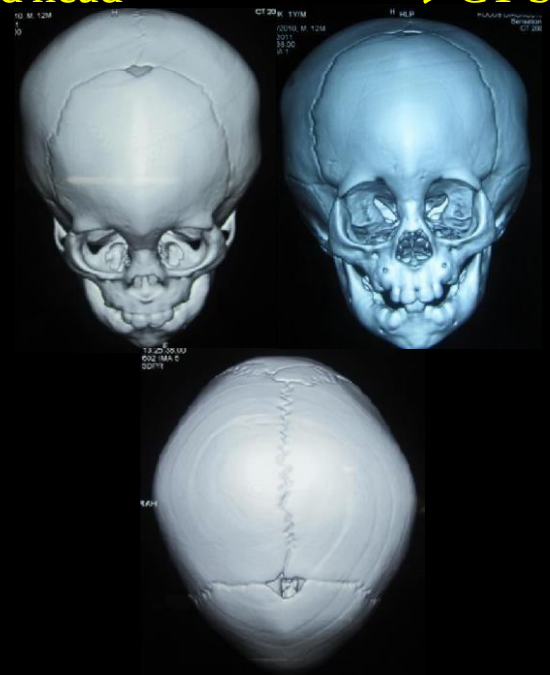

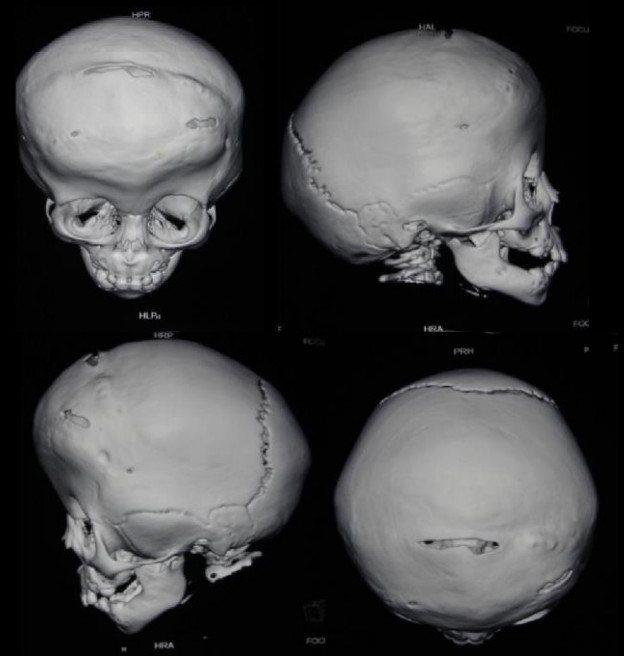

www.craniofacialinstitute.org

Craniofacial Dysostosis

Crouzon Syndrome/Pfeiffer Syndrome/Cloverleaf skull

Crouzon Syndrome

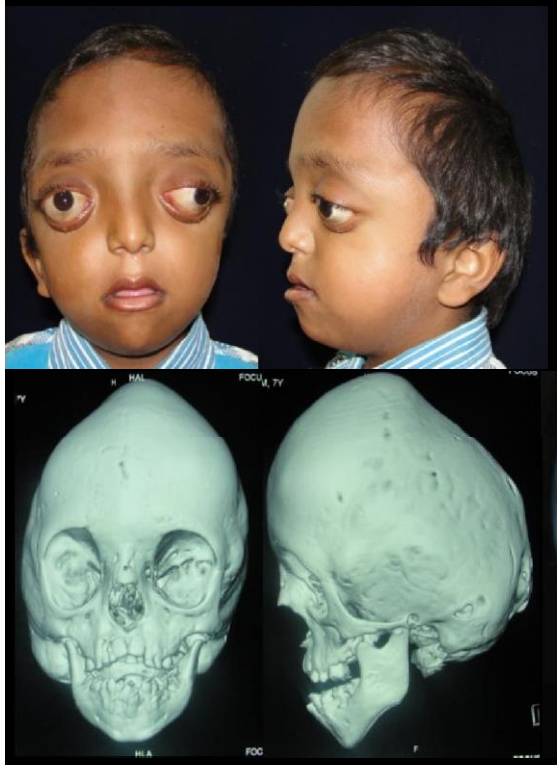

- Craniosynostosis
- Exophthalmos
- Hypertelorism
- Stabismus
- Hypoplastic maxilla

Pfeiffer Syndrome

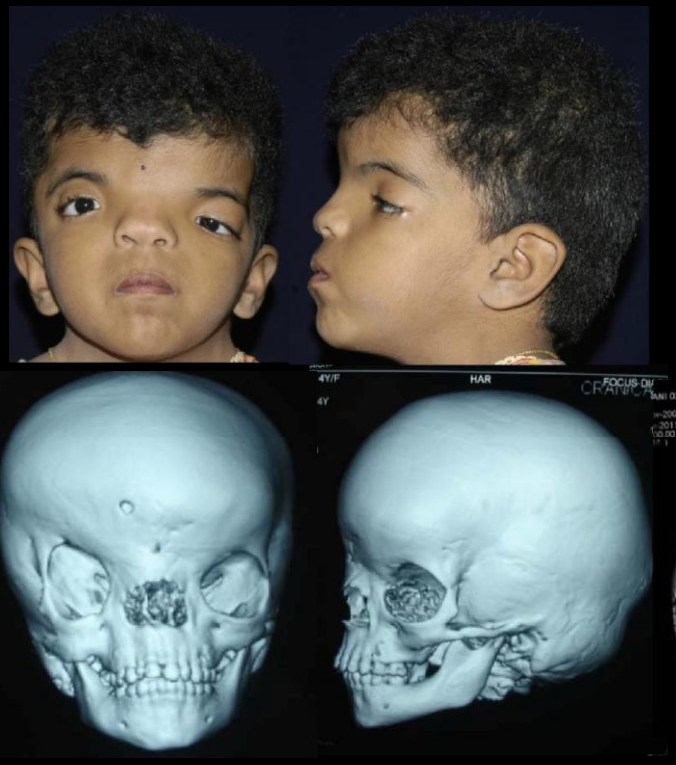

- Craniosynostosis
- Hypertelorism
- Retruded maxilla
- Stubby fingers and toes

Cloverleaf skull

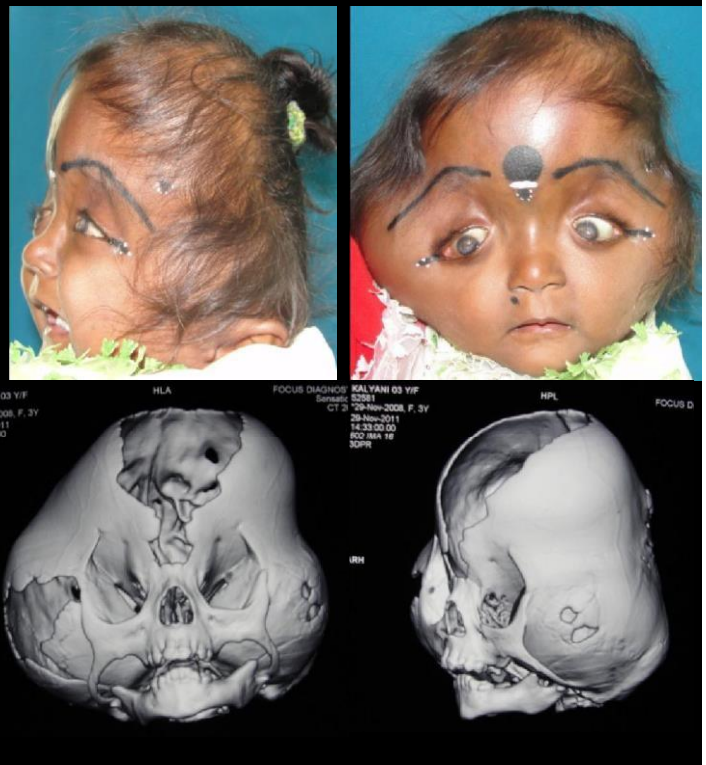

- Severe craniosynostosis
- Cloverleaf shape of skull

www.craniofacialinstitute.org

Craniofacial Syndromes and Anomalies

Treacher Collins Syndrome/Binder Syndrome

Treacher Collins Syndrome

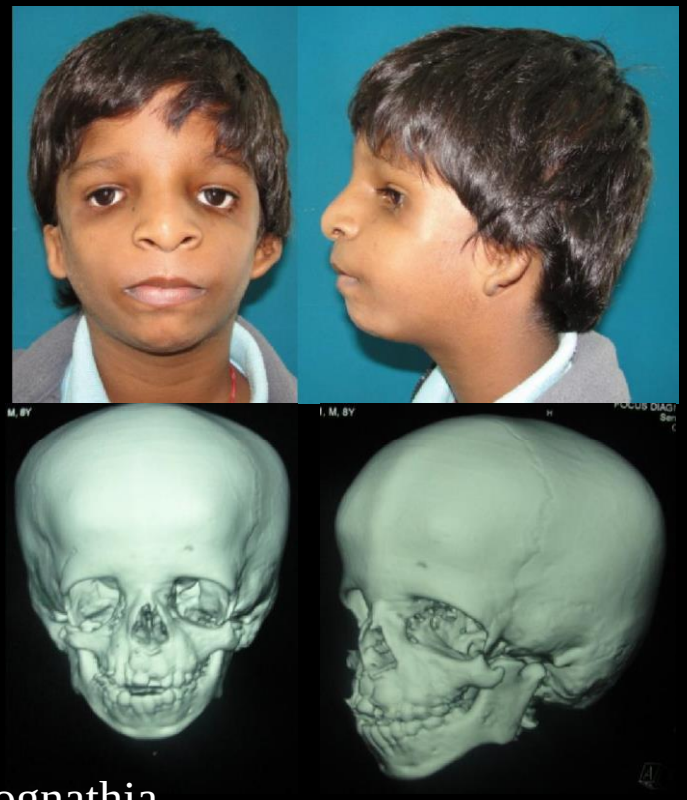

- Micrognathia,
- Underdeveloped zygoma,
- Drooping of lateral lower eyelids
- Malformed or absent ears with conductive hearing loss

Binder Syndrome

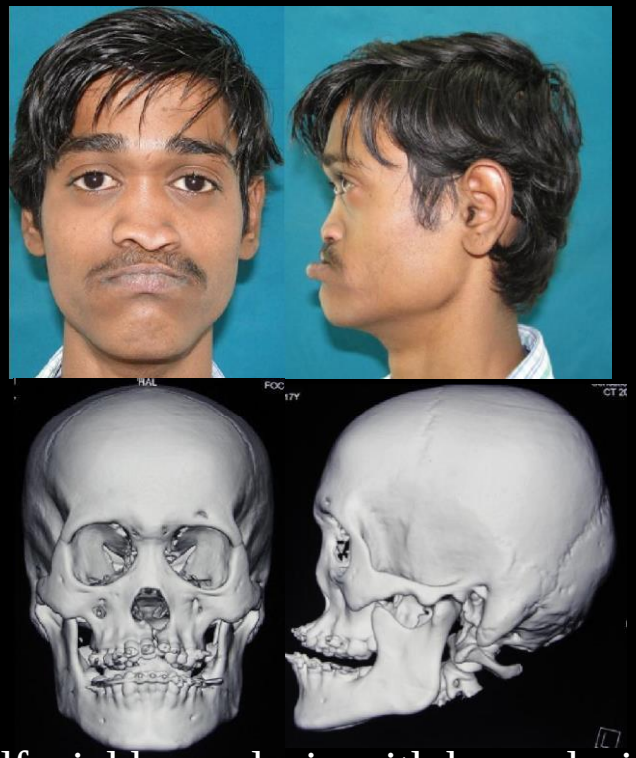

- Midfacial hypoplasia with hypoplasia of cartilaginous nasal septum and premaxilla
- Complete absence of anterior nasal spine
- Class III skeletal and dental profile

Craniofacial Syndromes and Anomalies

Hemifacial Microsomia

Type I

Type II a

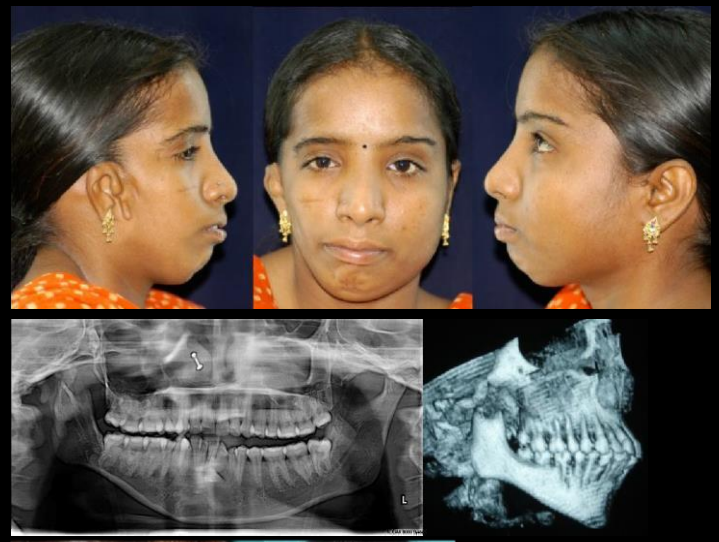

Type II b

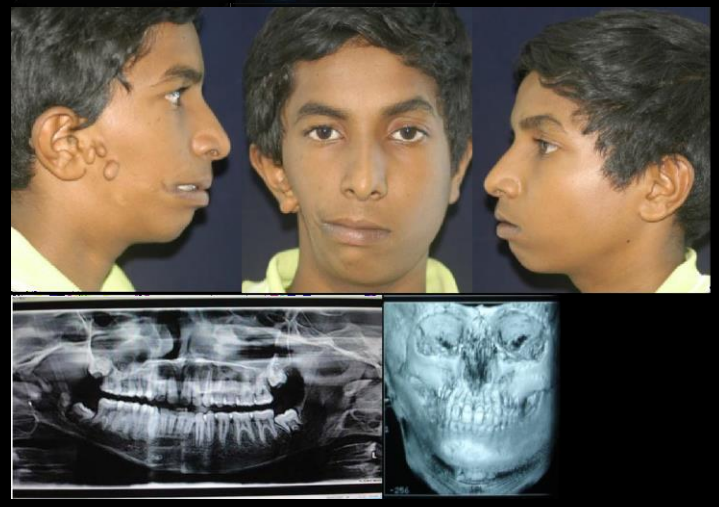

Type III

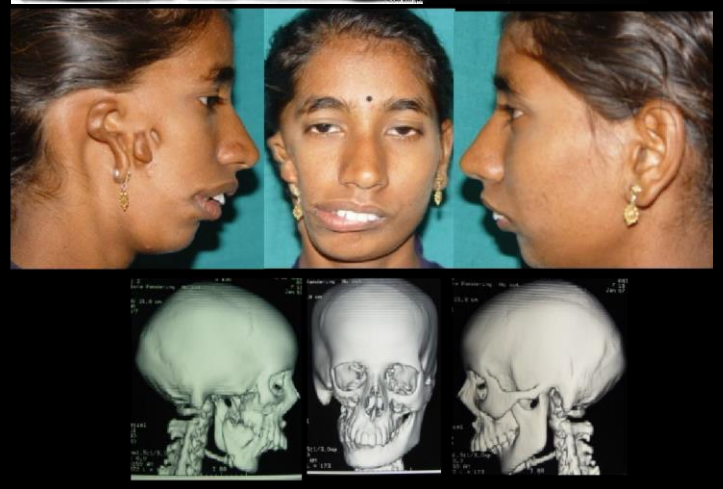

- Affects the development of the lower half of the face,
- Most commonly the ears, the mouth and the mandible

Craniofacial Syndromes and Anomalies

Pierre Robin Sequence

Pierre Robin Sequence

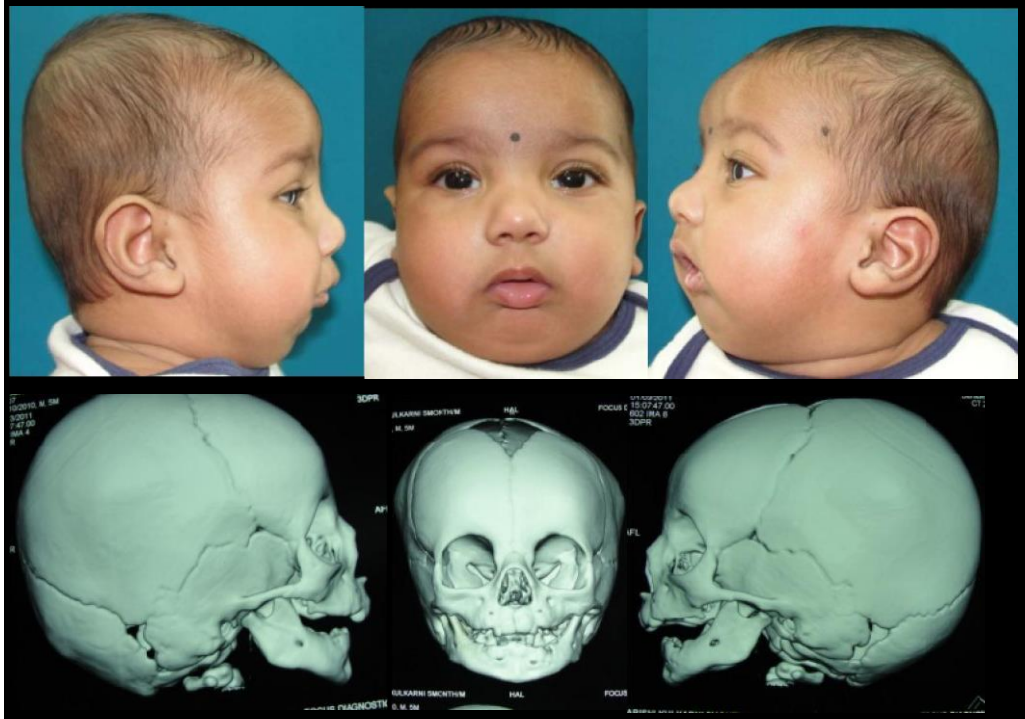

3 main features

- cleft palate,
- micrognathia
  (a small jaw)
- glossoptosis
  (airway obstruction caused by backwards displacement of the tongue base)

Craniofacial Syndromes and Anomalies

Craniofrontonasal Dysplasia

Hypertelorism

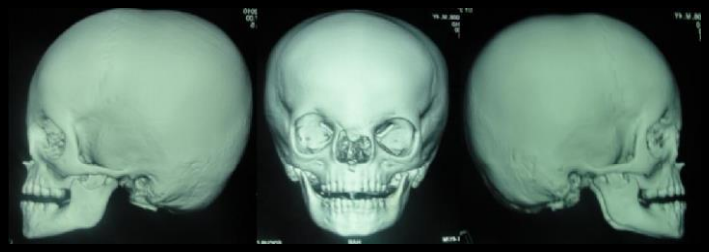

- Lateralization of the total orbital complex with increase in the interorbital distance and intercanthal width
- Increase in the distance between the lateral orbital walls and the interorbital distance to denote true hypertelorism
- May be symmetric, asymmetric or unilateral

Cranial Vault Defects

Dandy Walker Syndrome

Craniofacial Syndromes and Anomalies

Craniofacial Clefts

Tessier #0
facial cleft

Tessier #2
facial cleft

Tessier #3
facial cleft

Tessier #4
facial cleft

Tessier #5
facial cleft

Tessier #7
facial cleft

Bilateral Tessier
#3, #4, #30
Facial Cleft

Tessier 0-14
Facial Cleft
Orbital Hypertelorism

www.craniofacialinstitute.org

Cleft Lip

Incomplete unilateral cleft lip

Complete Unilateral cleft lip

Incomplete bilateral cleft lip

Complete bilateral cleft lip

Cleft Palate

Cleft of hard and soft palate associated with cleft lip

Unilateral cleft palate

Bilateral cleft palate

Isolated cleft palate

Submucous cleft palate

Craniofacial Tumors

Encephaloceles

Meningocephalocele

Meningocele

neural tube defect

sac-like protrusions of the brain and the membranes that cover it through openings in the skull.

caused by failure of the neural tube to close completely during fetal development.

Seen between the

forehead and nose, or

on the back side of the skull

Craniofacial Tumors

Hemangiomas/Vascular Malformations

Vascular Malformations

Capillary

Venous

Lymphatic

Arterio-venous

Hemangioma

- Vascular Malformations
- Congenital vascular lesions
- Continue to grow throughout life

Growth caused by

- Progressive ectasia of existing vessels
- Usually caused by trauma, sepsis or hormonal changes

- Hemangiomas
- Acquired vascular lesions
- Period of growth followed by involution

Growth caused by

- Rapid proliferation by hyperplasia of endothelial cells
- Followed by spontaneous involution

Craniofacial Tumors

Plexiform Neurofibroma and benign tumors

www.craniofacialinstitute.org

Craniofacial Tumors

Sarcoma and other malignancies

Craniomaxillofacial Trauma

Non-syndromic Orthognathic Deformities

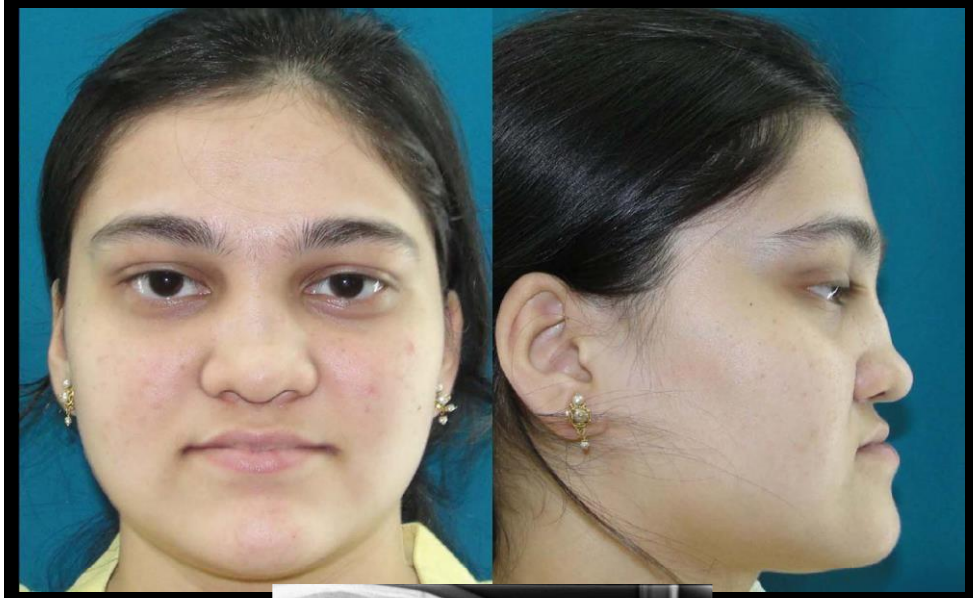

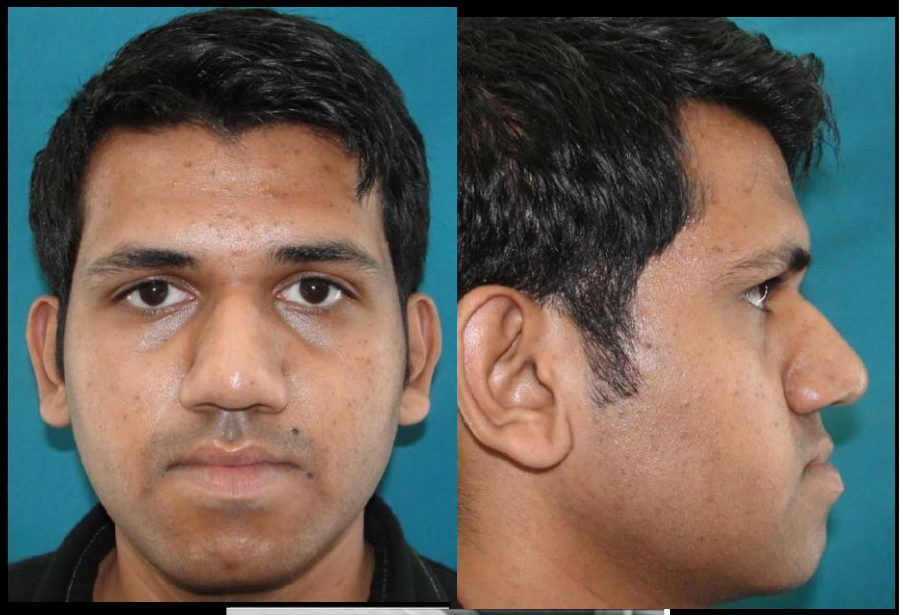

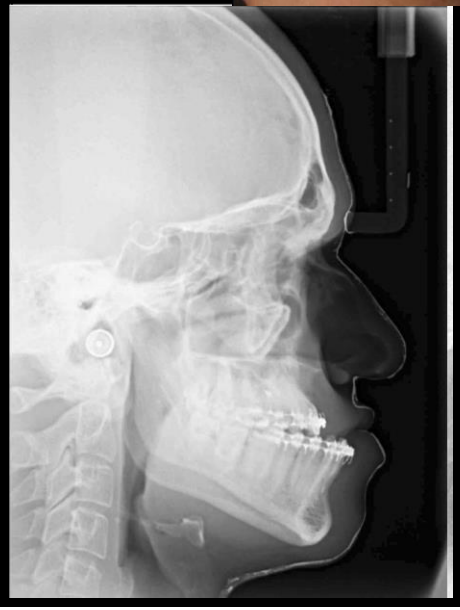

Craniofacial Surgery

When?

What? Where?…. Who? And How?

Craniofacial Anomalies

Abnormalities of the Head and Neck region

Congenital

Soft Tissue:	3-12 months
Bone:	
Skull Reshaping:	Infancy
Orbital Rim Advancement:	6-24 months
Ant. Cranial Vault Recon.:	6-24 months
Post. Cranial Vault Recon.:	6-24months
Midface deformity:	5-7 years
Jaw Deformity:	13-18 years

Acquired

Immediate

Craniofacial Surgery

Who?

What? Where? When?....And How?

Craniofacial Division or Center

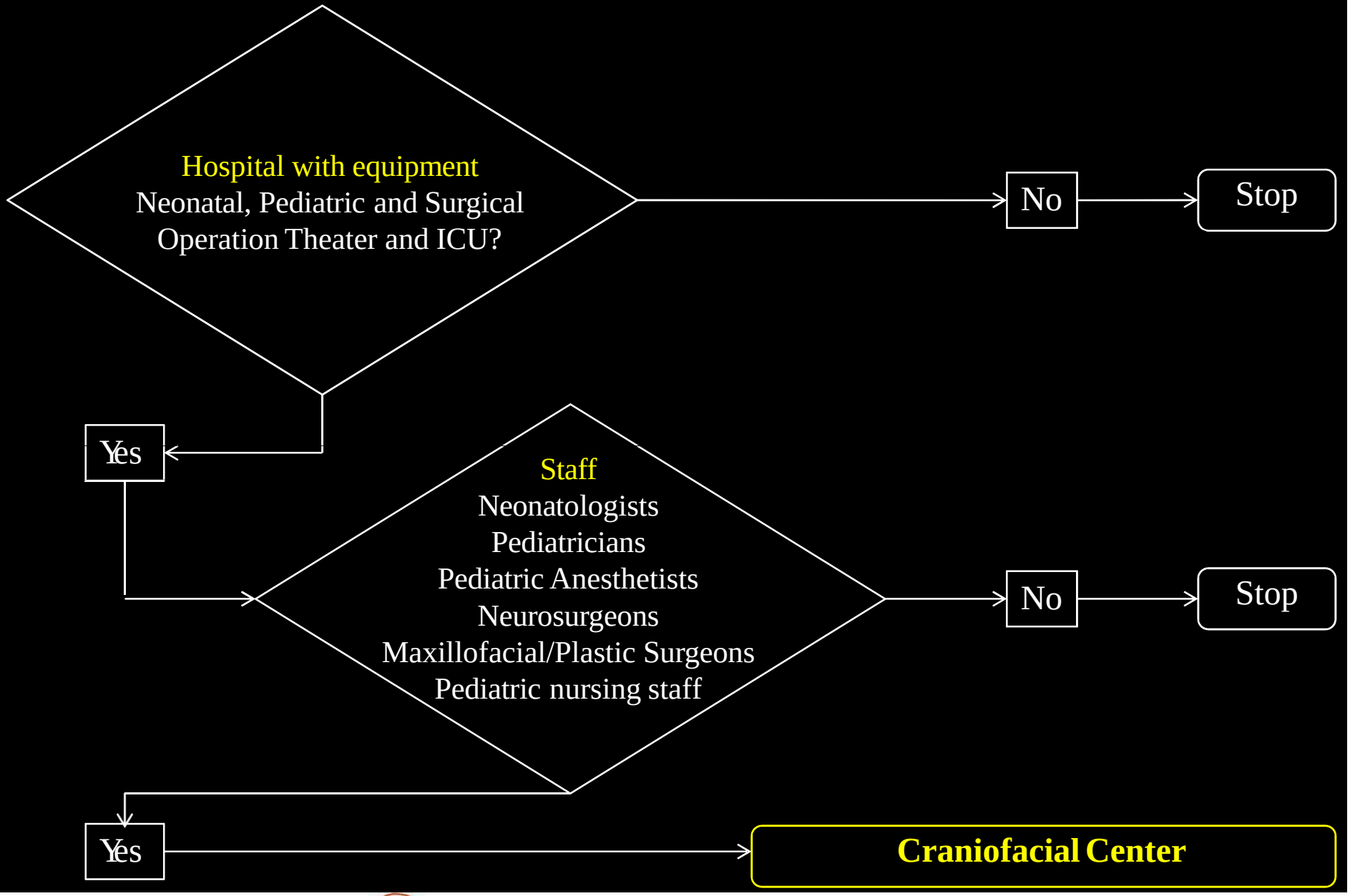

www.craniofacialinstitute.org

Craniofacial Surgery

And How?

What? Where? When? Who?....

Craniofacial Treatment

Pediatric Anesthetists, Neurosurgeons,

Maxillofacial/Plastic Surgeons
Pediatric nursing staff
In
Pediatric and Surgical
Operation Theater and ICU

Bicoronal Incision

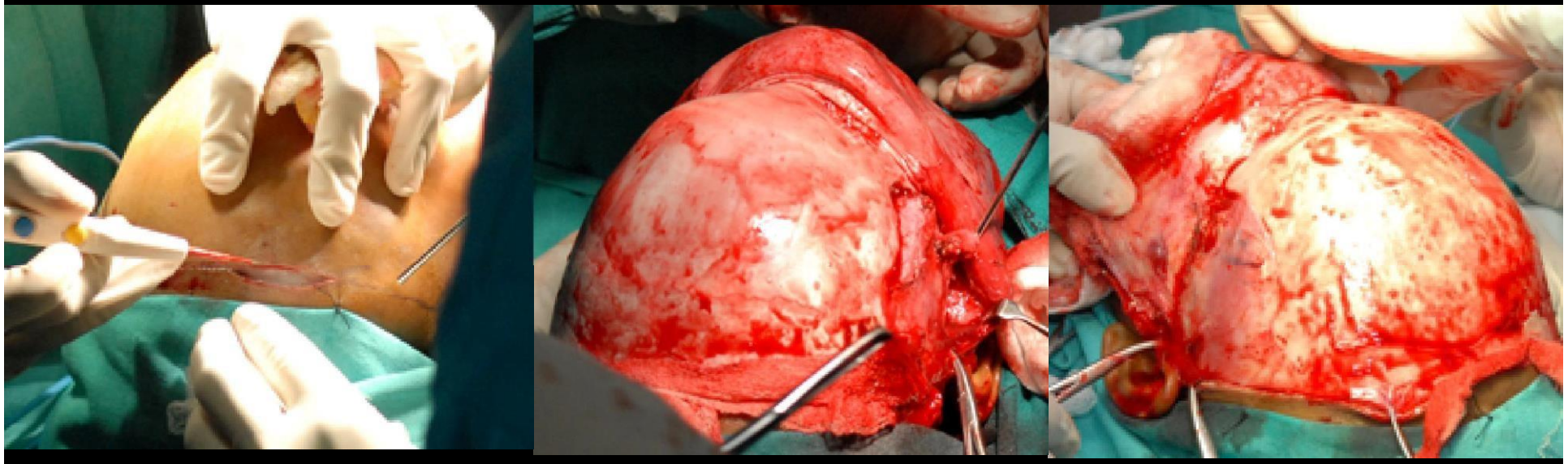

The skin incision for approaching the cranium, supraorbital area and the zygomatic area consists of bicoronal incision with the dissection as far forward and anterior as possible.

Craniosynostosis

Plagiocephaly/Trigonocephaly/Scaphocephaly/Brachycephaly

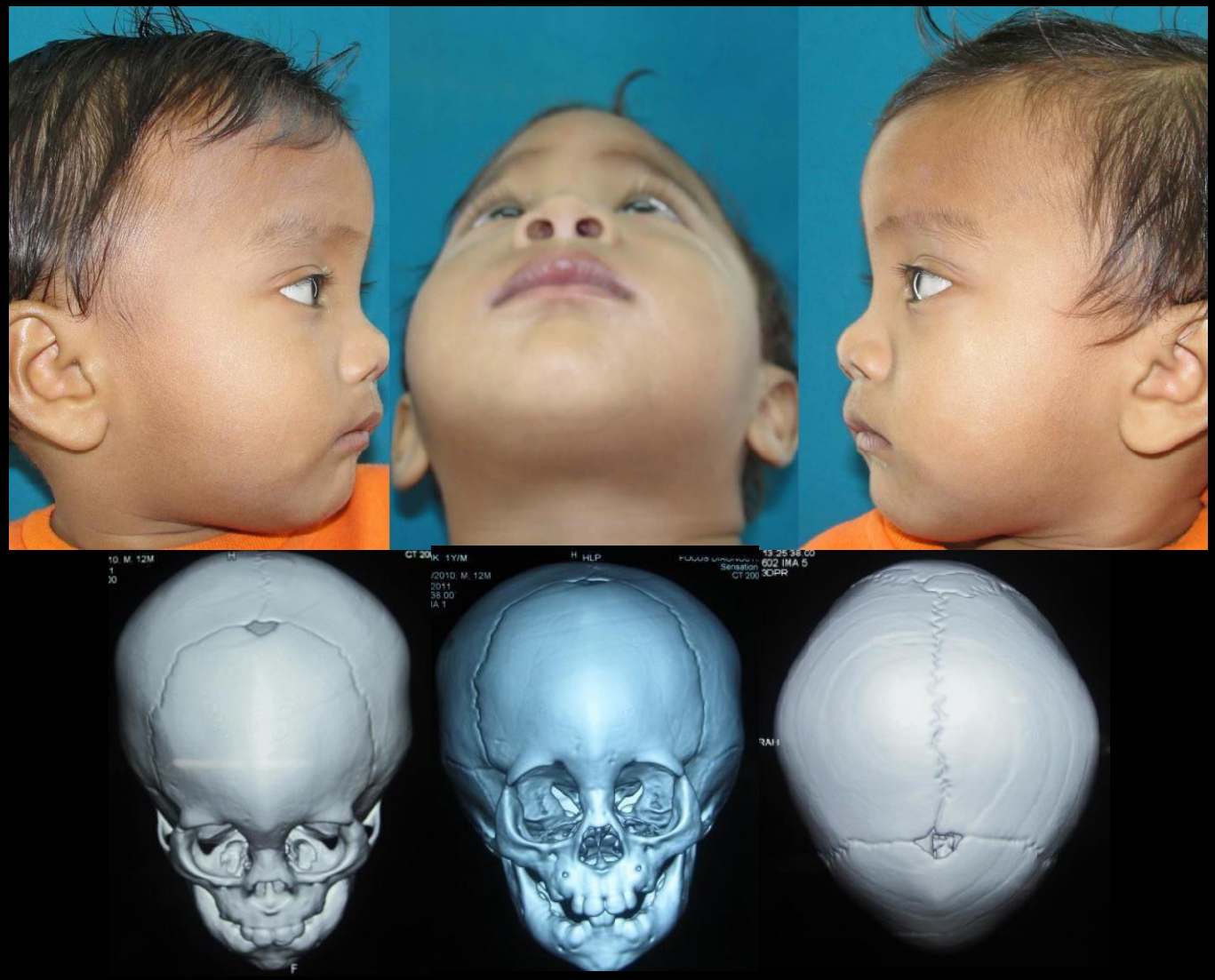

www.craniofacialinstitute.org

Craniosynostosis

Plagiocephaly/Trigonocephaly/Scaphocephaly/Brachycephaly

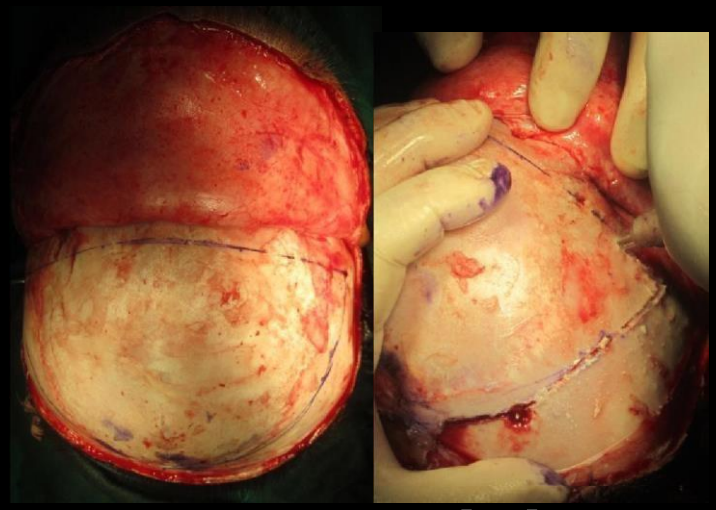

Raising Frontal Flap

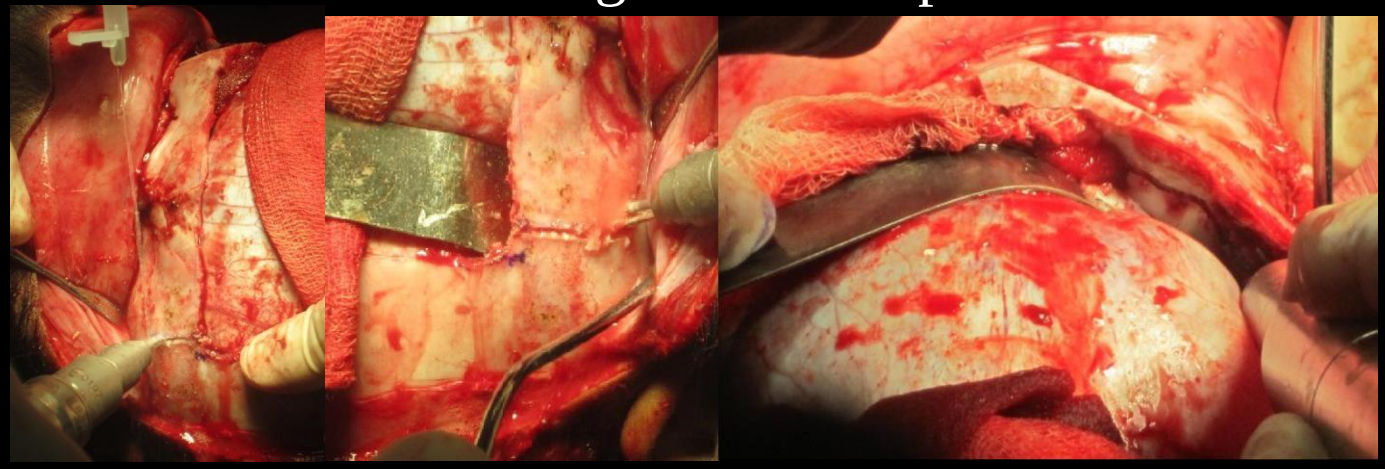

Harvesting supraorbital band

Craniosynostosis

Plagiocephaly/Trigonocephaly/Scaphocephaly/Brachycephaly



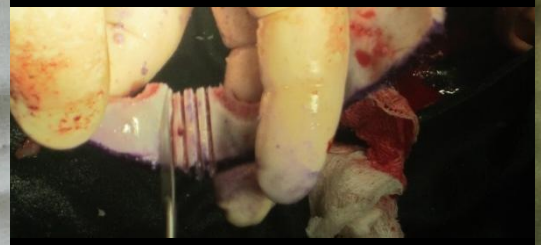


Superior Orbital rim advancement and fixation

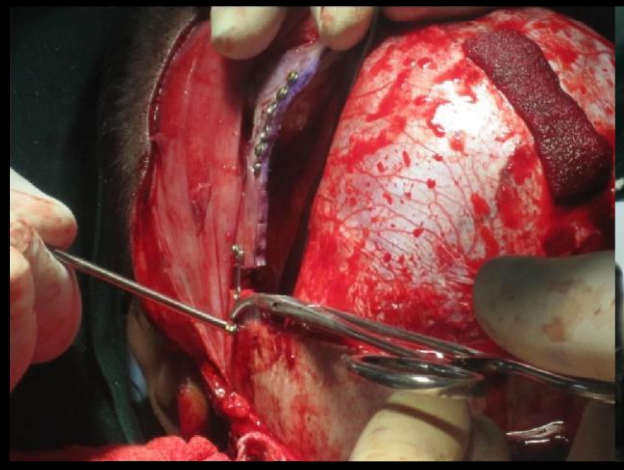

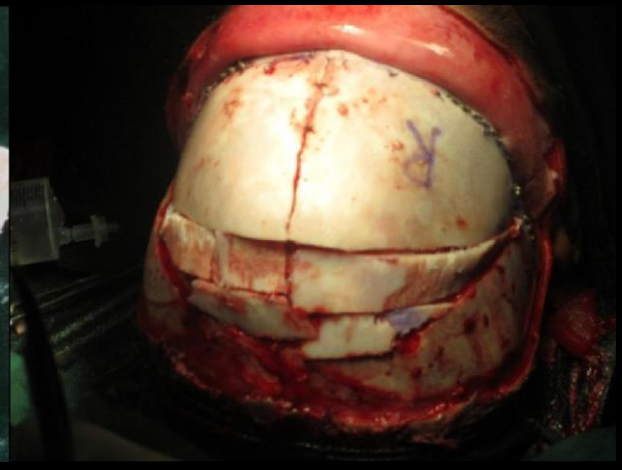

Fixation

Craniosynostosis

Plagiocephaly/Trigonocephaly/Scaphocephaly/Brachycephaly

www.craniofacialinstitute.org

Craniosynostosis

Plagiocephaly/Trigonocephaly/Scaphocephaly/Brachycephaly

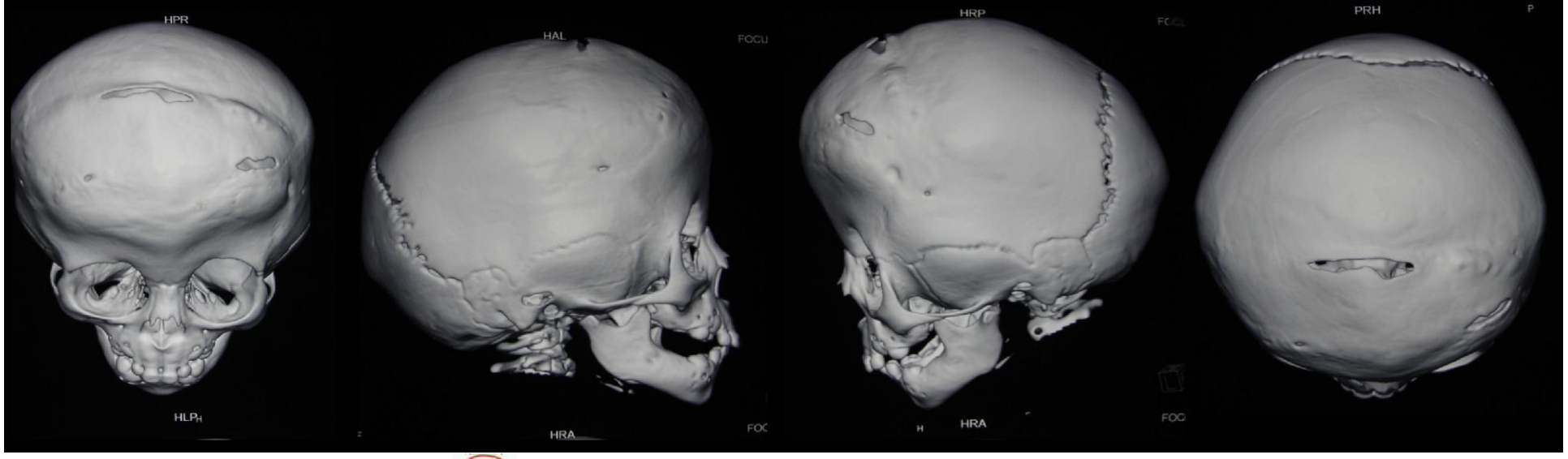

www.craniofacialinstitute.org

Craniosynostosis

Plagiocephaly/Trigonocephaly/Scaphocephaly/Brachycephaly

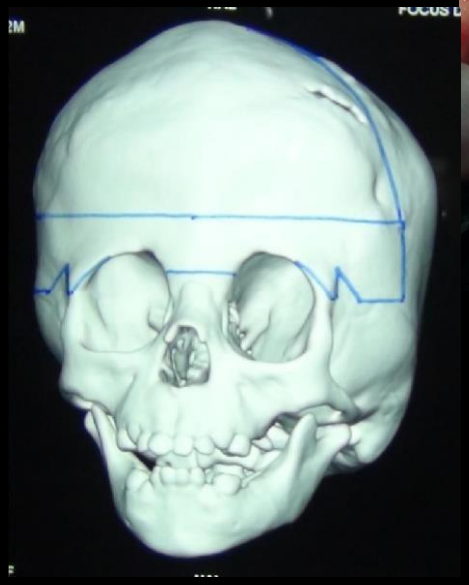

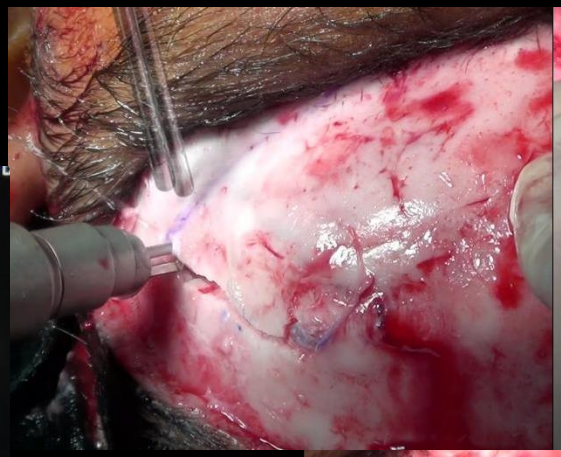

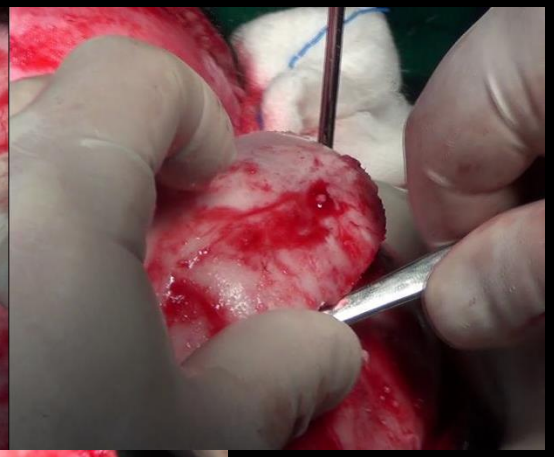

Raising Frontal Flap

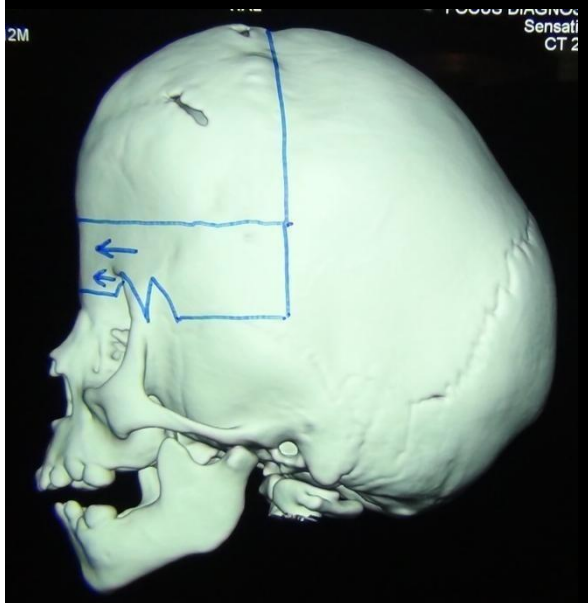

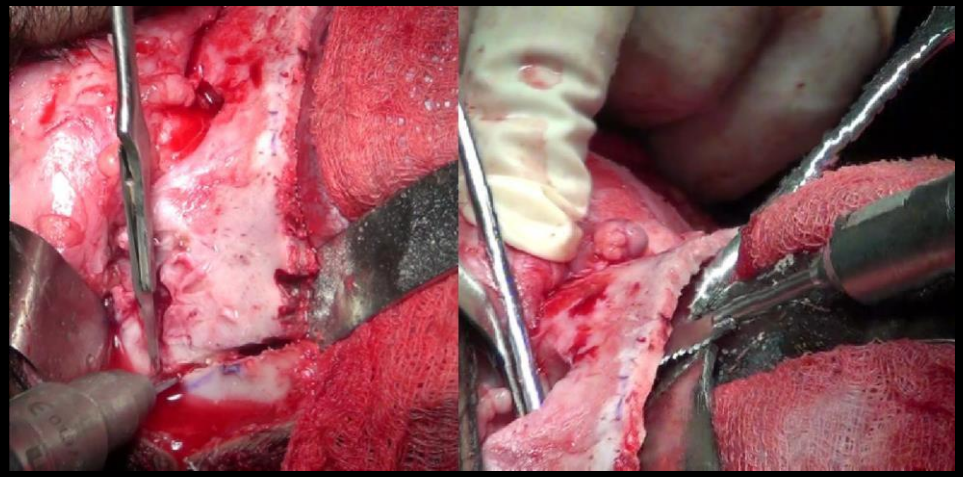

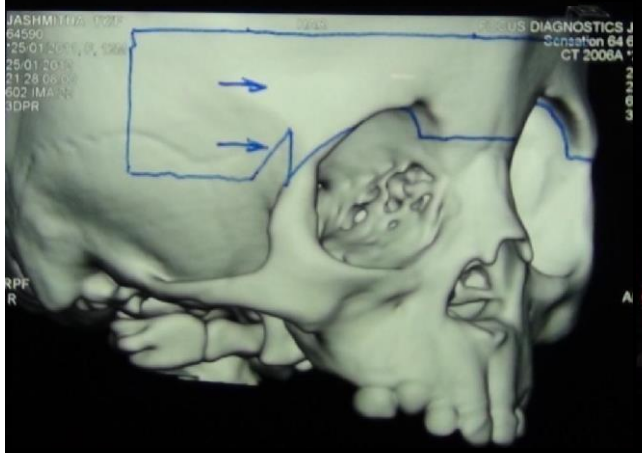

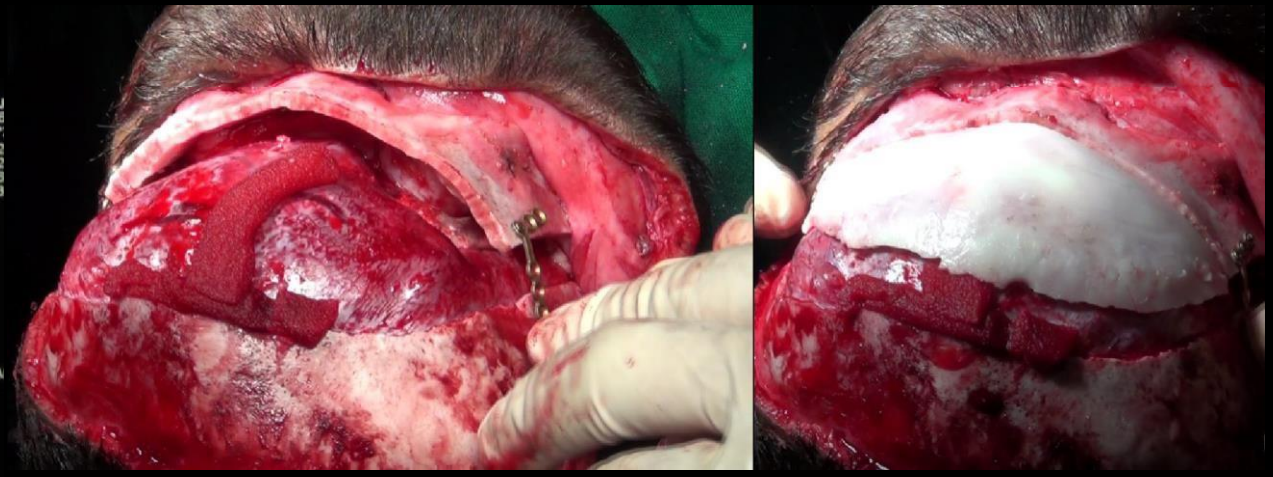

Superior Orbital rim advancement and fixation

Craniosynostosis

Plagiocephaly/Trigonocephaly/Scaphocephaly/Brachycephaly

www.craniofacialinstitute.org

CRANIOSYNOSTOSIS (TURRICEPHALY)
POSTERIOR CRANIAL VAULT DISTRACTION

INCISION MARKING

OSTEOTOMY

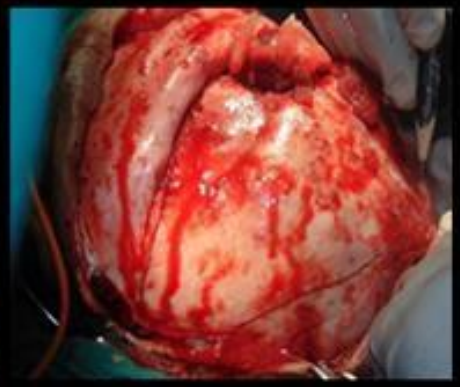

DISTRACTOR PLACEMENT

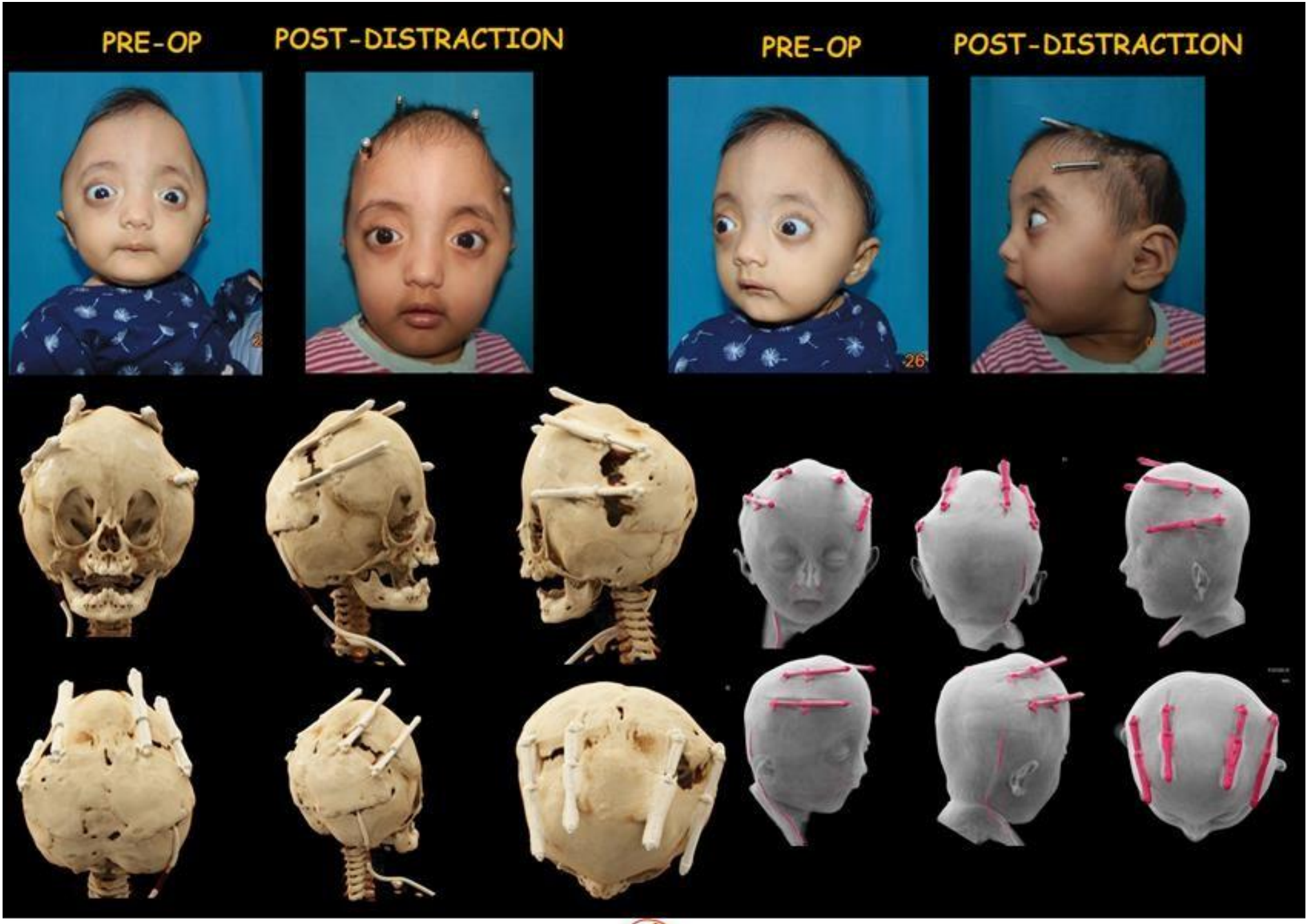
PRE-OP
POST-DISTRACTION
PRE-OP
POST-DISTRACTION

PRE-OP

POST DISTRACTOR REMOVAL

PRE-OP

POST DISTRACTOR REMOVAL

LATEST POST OP

Craniofacial Dysostosis

Pfeiffer Syndrome

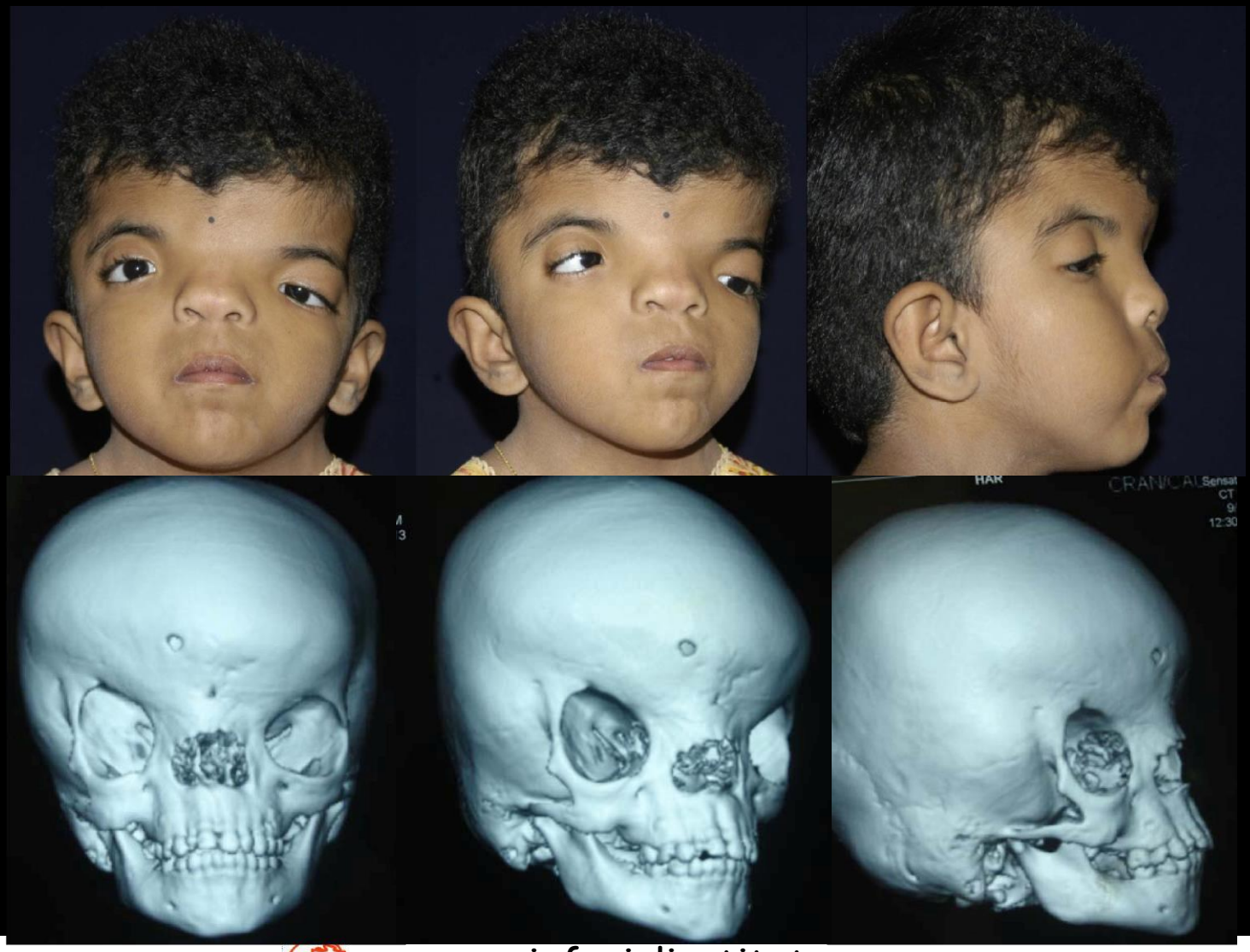

www.craniofacialinstitute.org

Craniofacial Dysostosis

Pfeiffer Syndrome

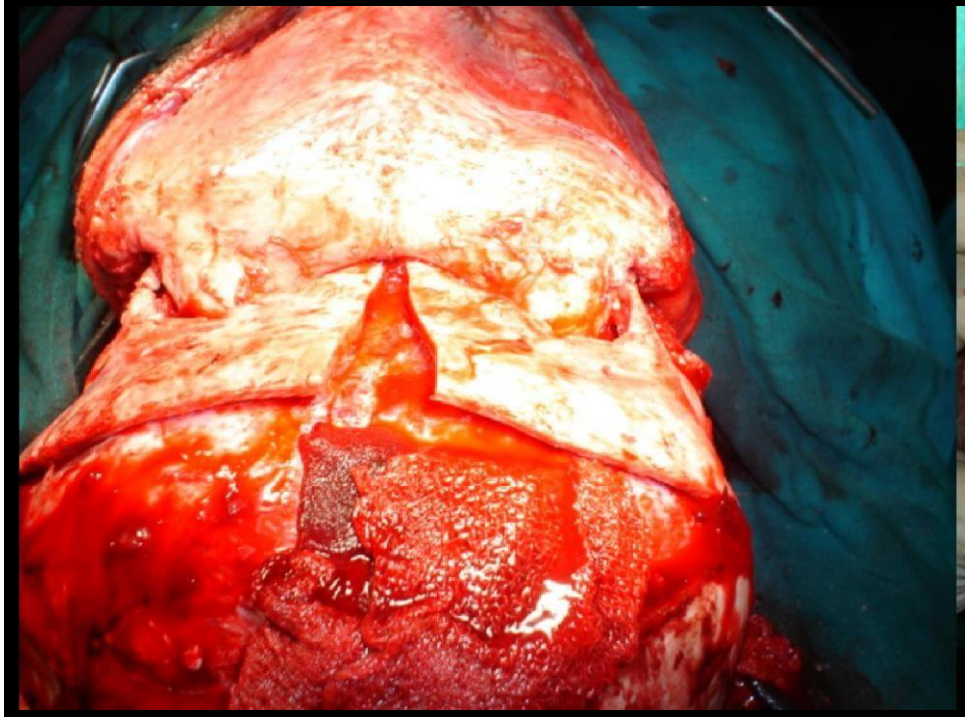

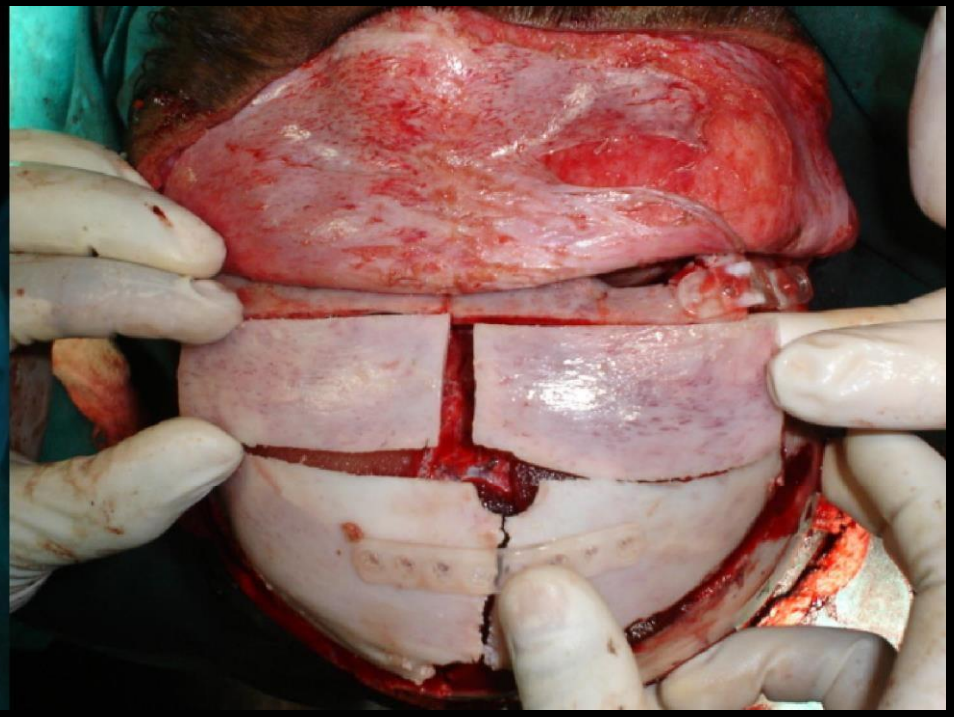

Facial Bipartition

A monobloc osteotomy with the orbits and midface in one unit is done. When the defects are amenable, the monobloc is partitioned at the midline

Craniofacial Dysostosis

Pfeiffer Syndrome

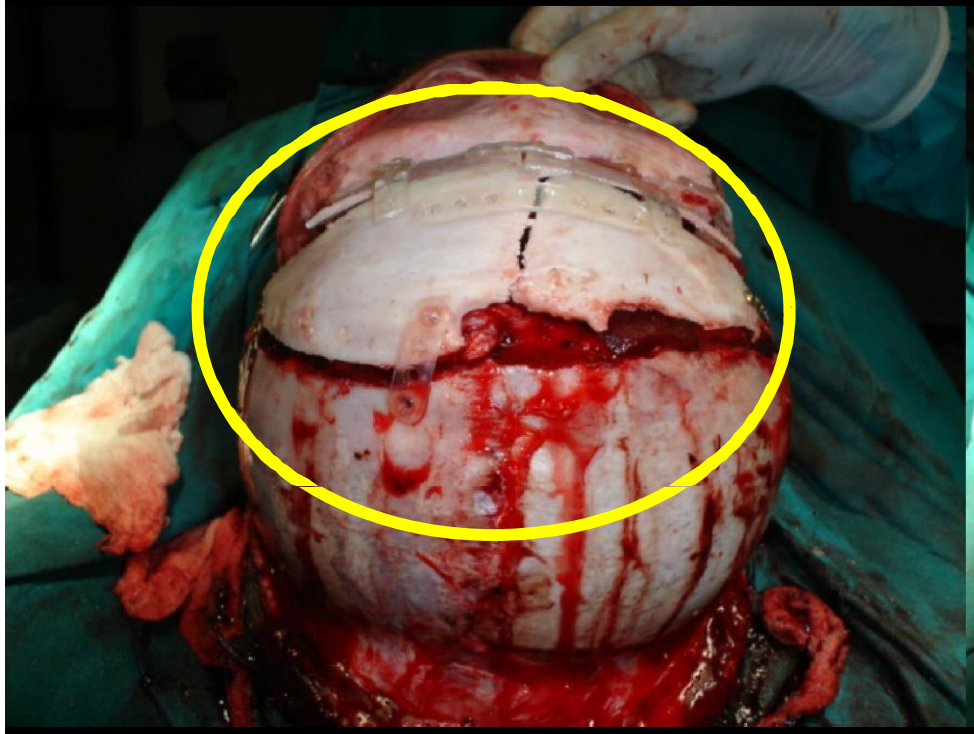

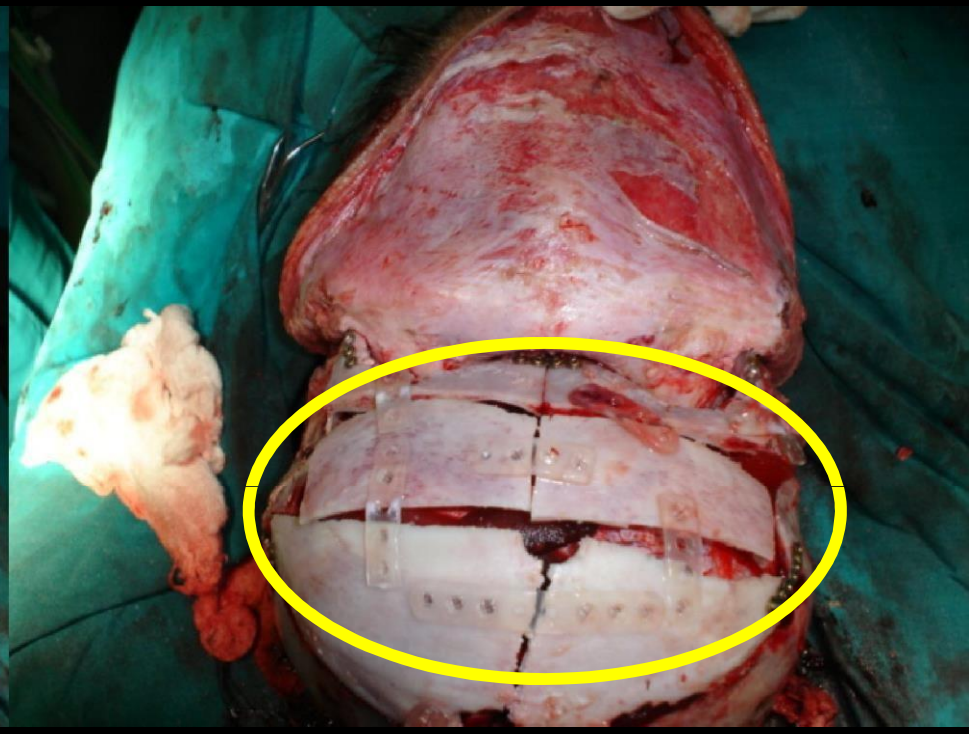

Fixation

In children fixation is done with bioresorbable bone plates

Craniofacial Dysostosis

Pfeiffer Syndrome

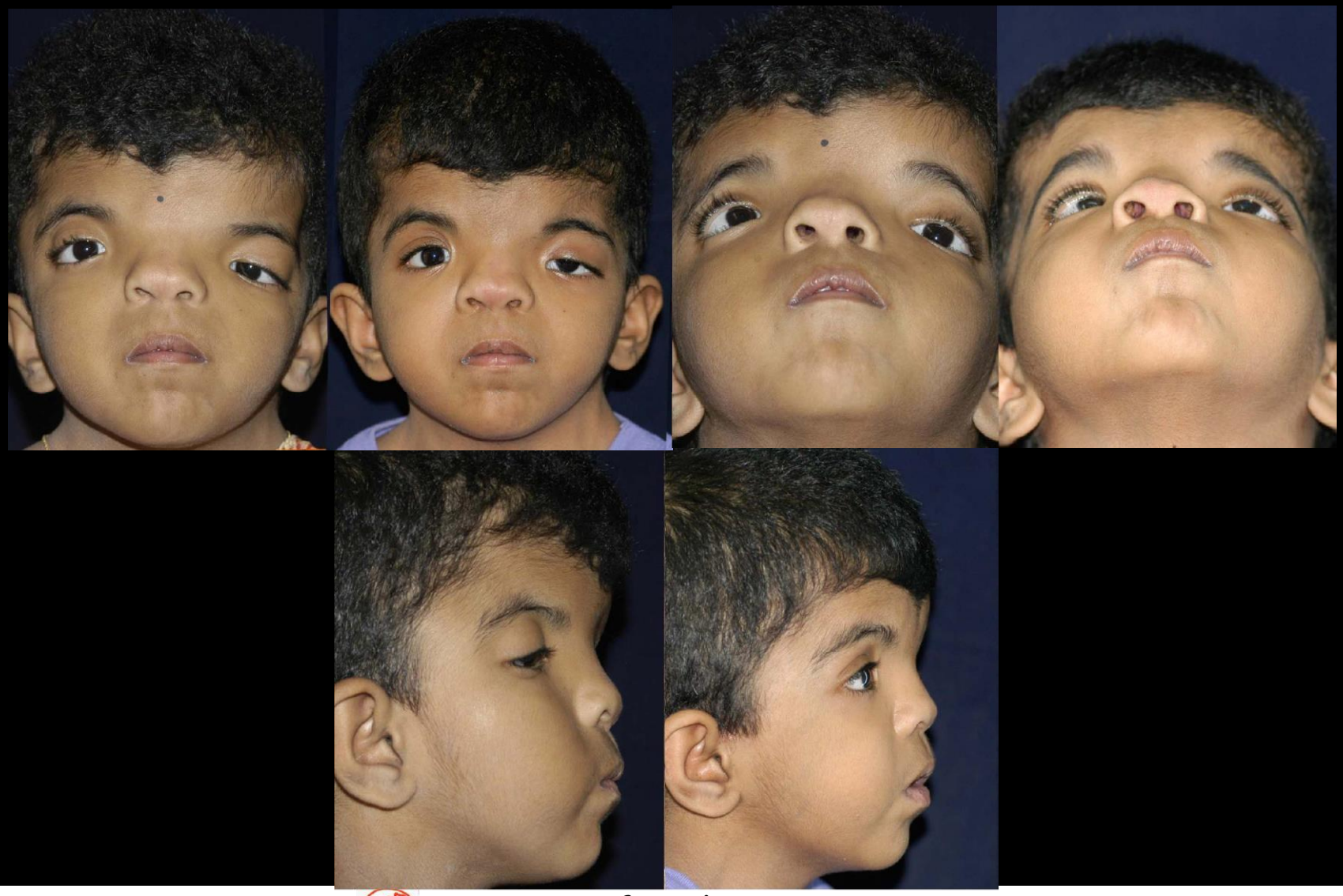

www.craniofacialinstitute.org

Craniofacial Dysostosis

Crouzon Syndrome

www.craniofacialinstitute.org

Craniofacial Syndromes and Anomalies

Treacher Collins Syndrome

Treacher Collins Syndrome

Craniofacial Syndromes and Anomalies

Treacher Collins Syndrome

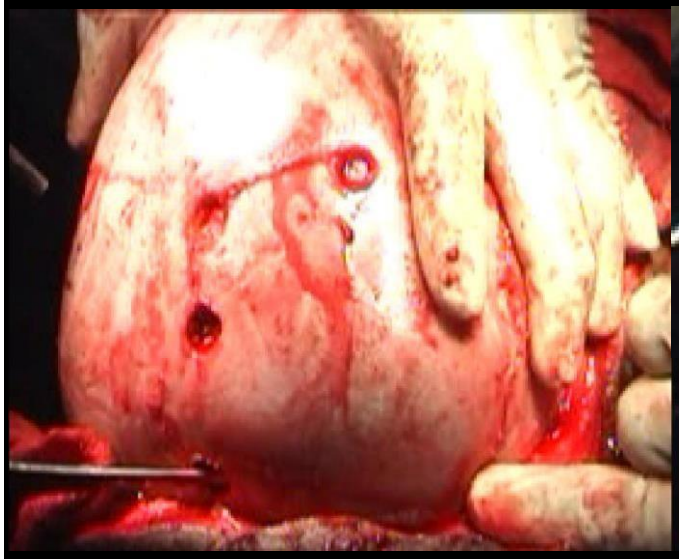

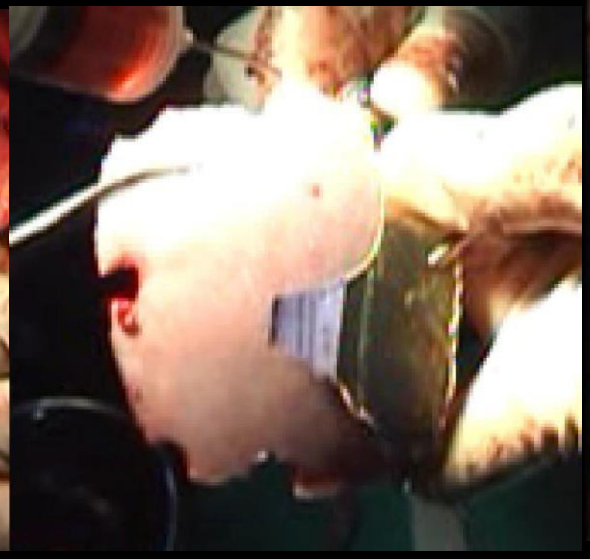

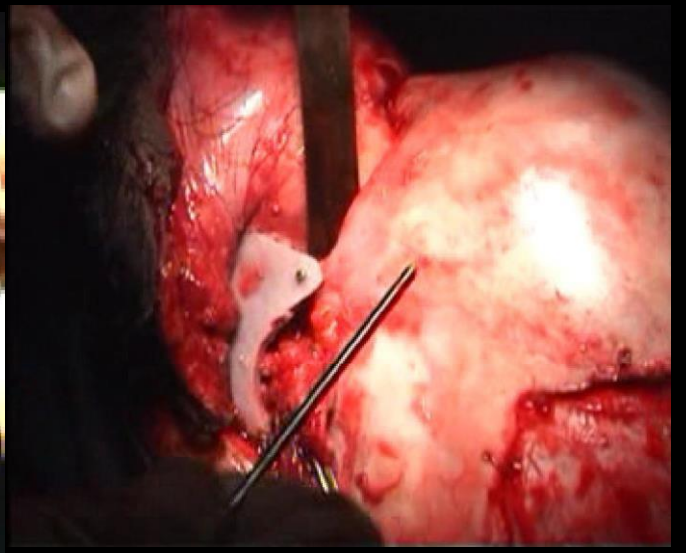

Full thickness calvarial bone grafts
Bilateral lateral canthopexy

Craniofacial Syndromes and Anomalies

Treacher Collins Syndrome

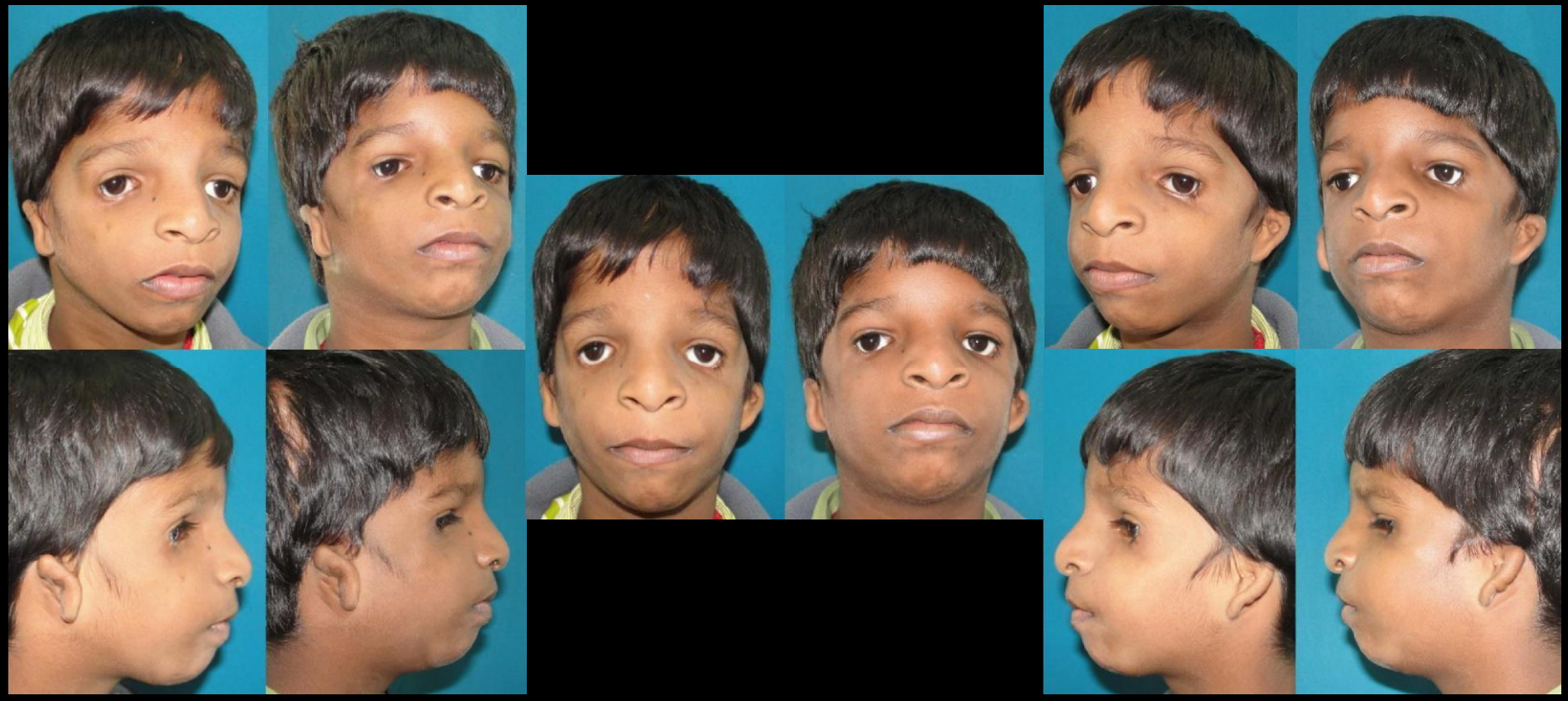

Craniofacial Syndromes and Anomalies

Binder Syndrome

Binder Syndrome

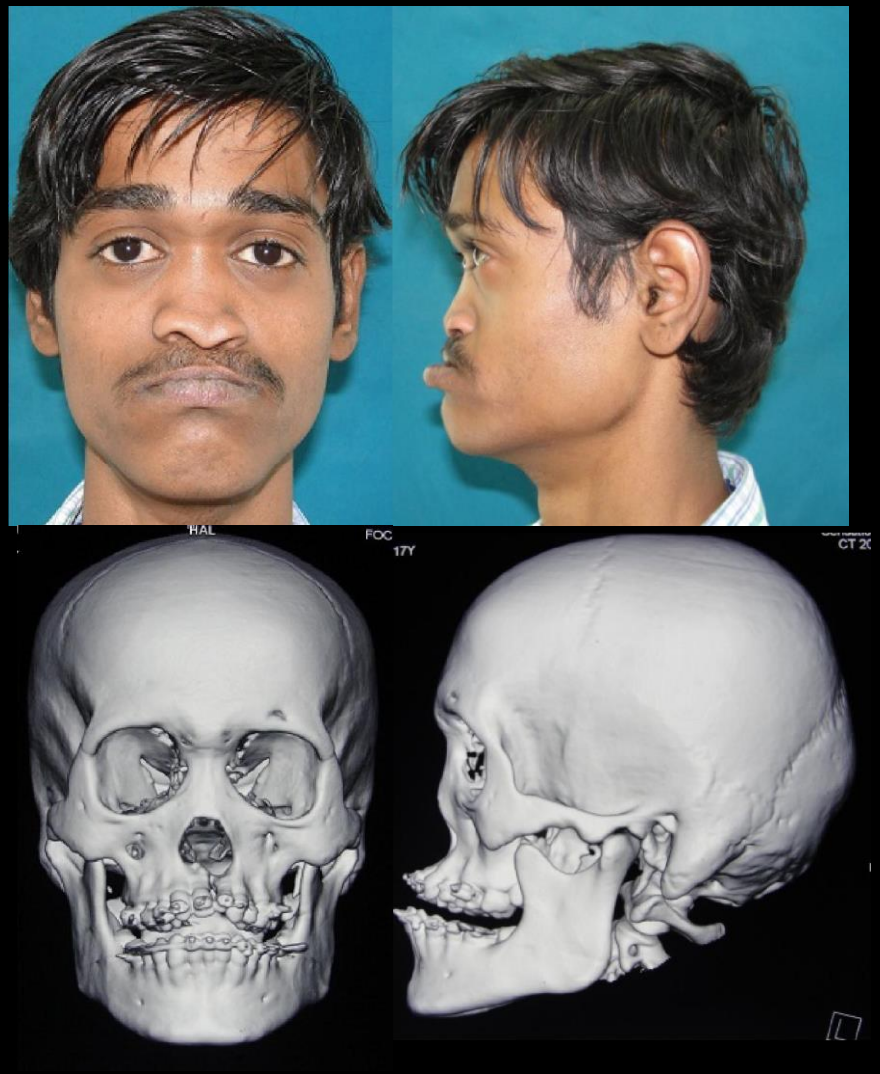

Performing a LeFort III Osteotomy

Frontozygomatic suture osteotomy and dysjunction of zygomatic arch is done

Orbital osteotomy along the lateral aspect of the internal orbit is done

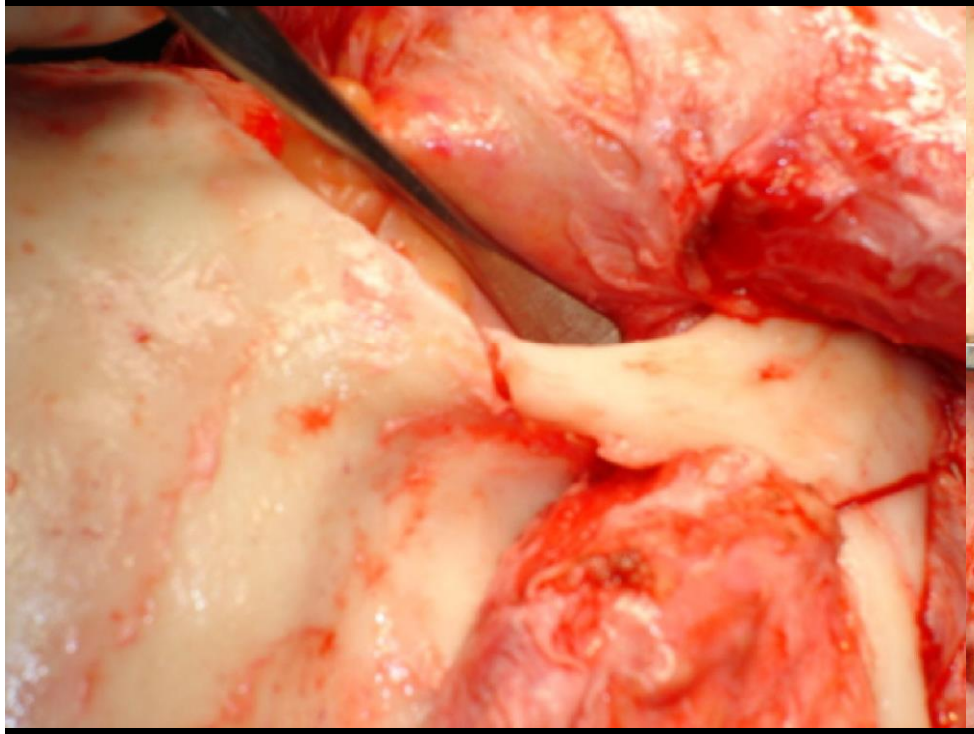

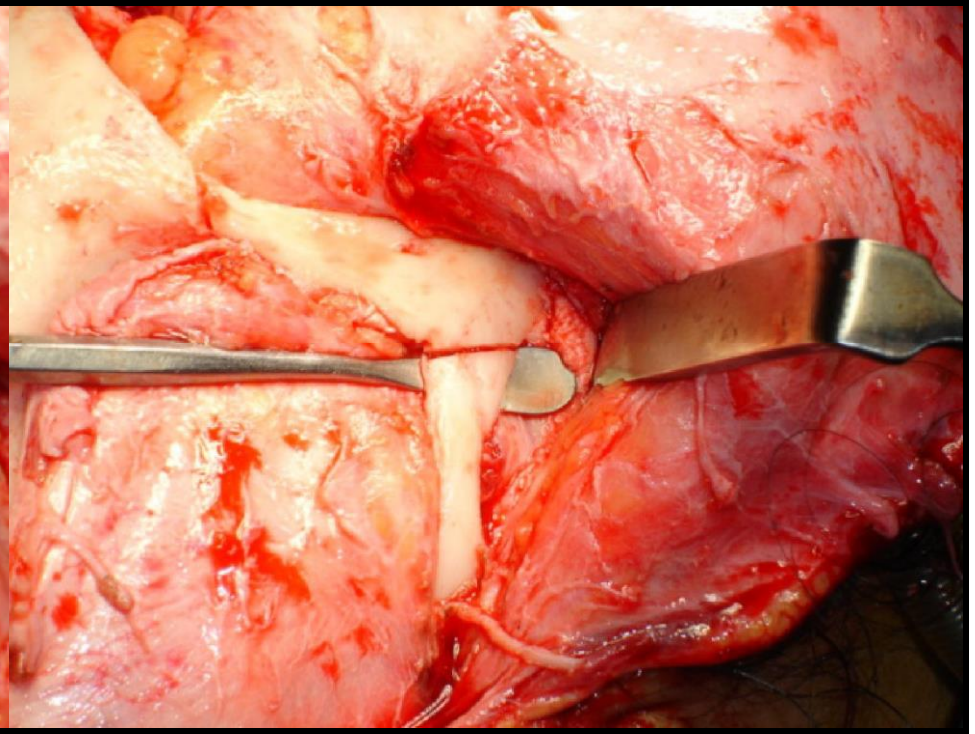

Performing a LeFort III Osteotomy

The osteotomy is continued along the sphenozygomatic suture line to the inferior orbital fissure.

The osteotomy then extends medially across the floor of the orbit up the medial wall of the orbit

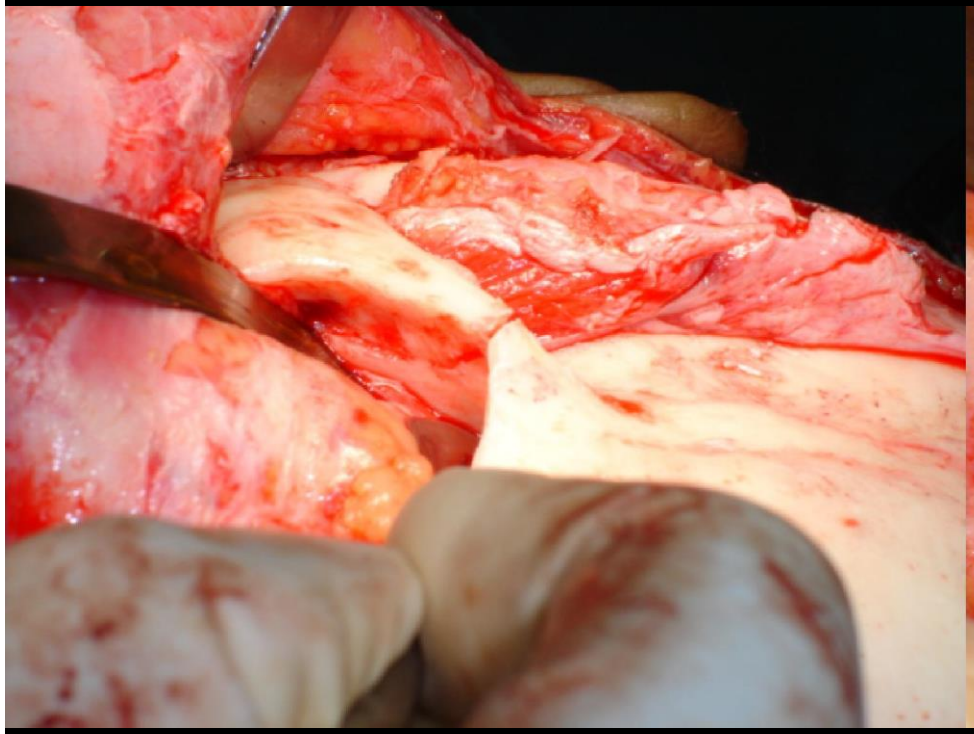

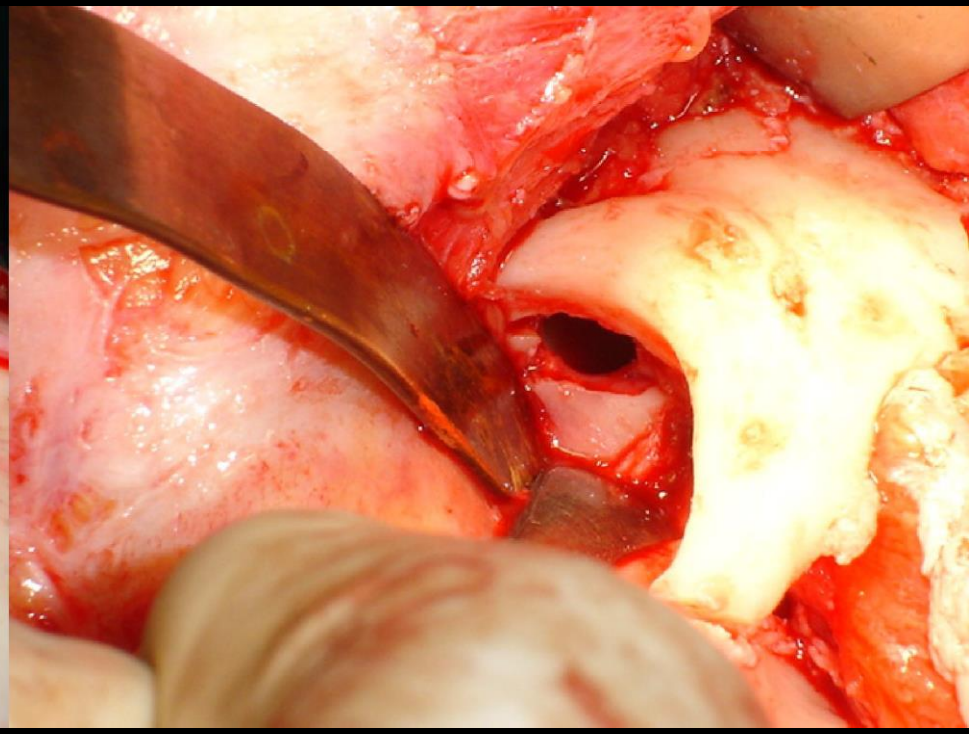

Performing a LeFort III Osteotomy

The osteotomy ends on the dorsum of the nose

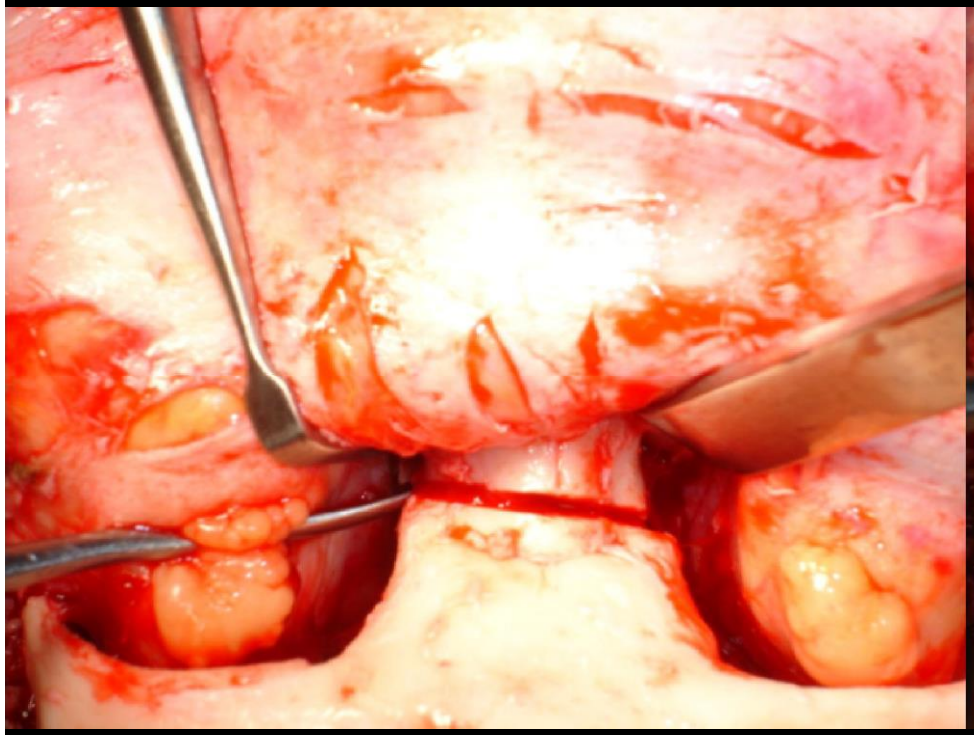

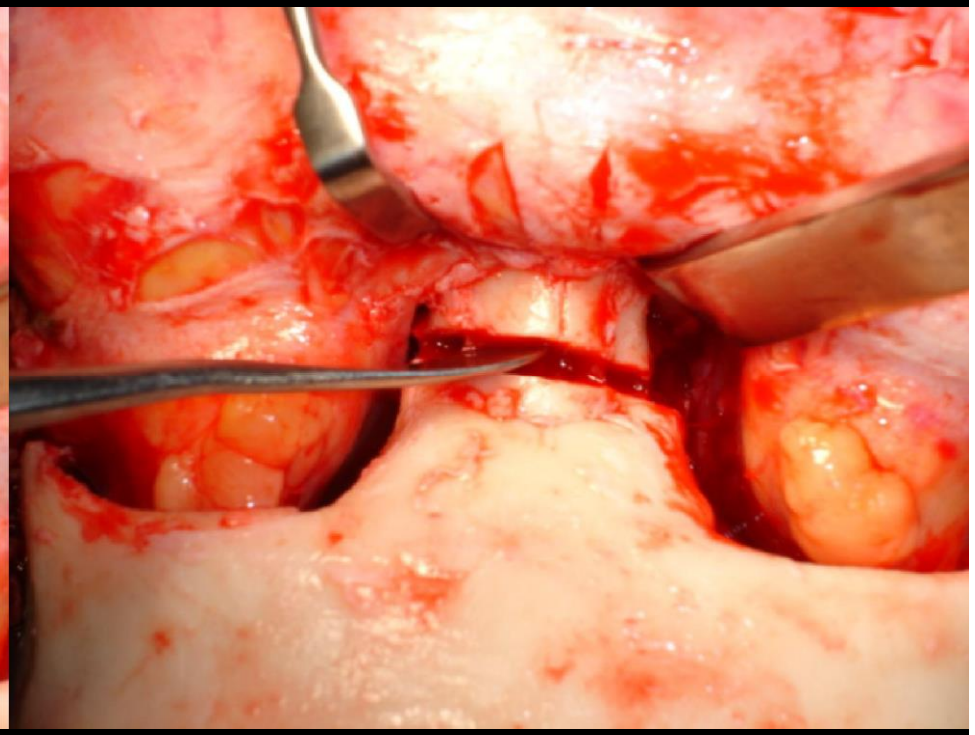

Performing a LeFort III Osteotomy

Calvarial bone graft is harveted

Fixation after performing a LeFort III Osteotomy

Fixation is done with 1.5 mm low profile plates at the nasal and frontozygomatic areas with interposition of bone grafts

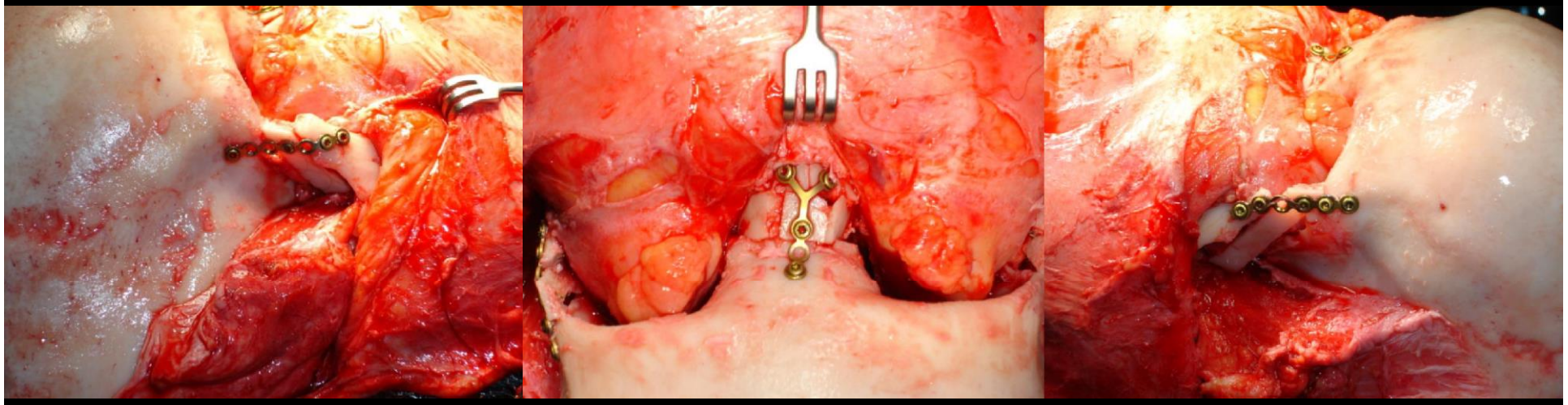

Craniofacial Syndromes and Anomalies

Binder Syndrome

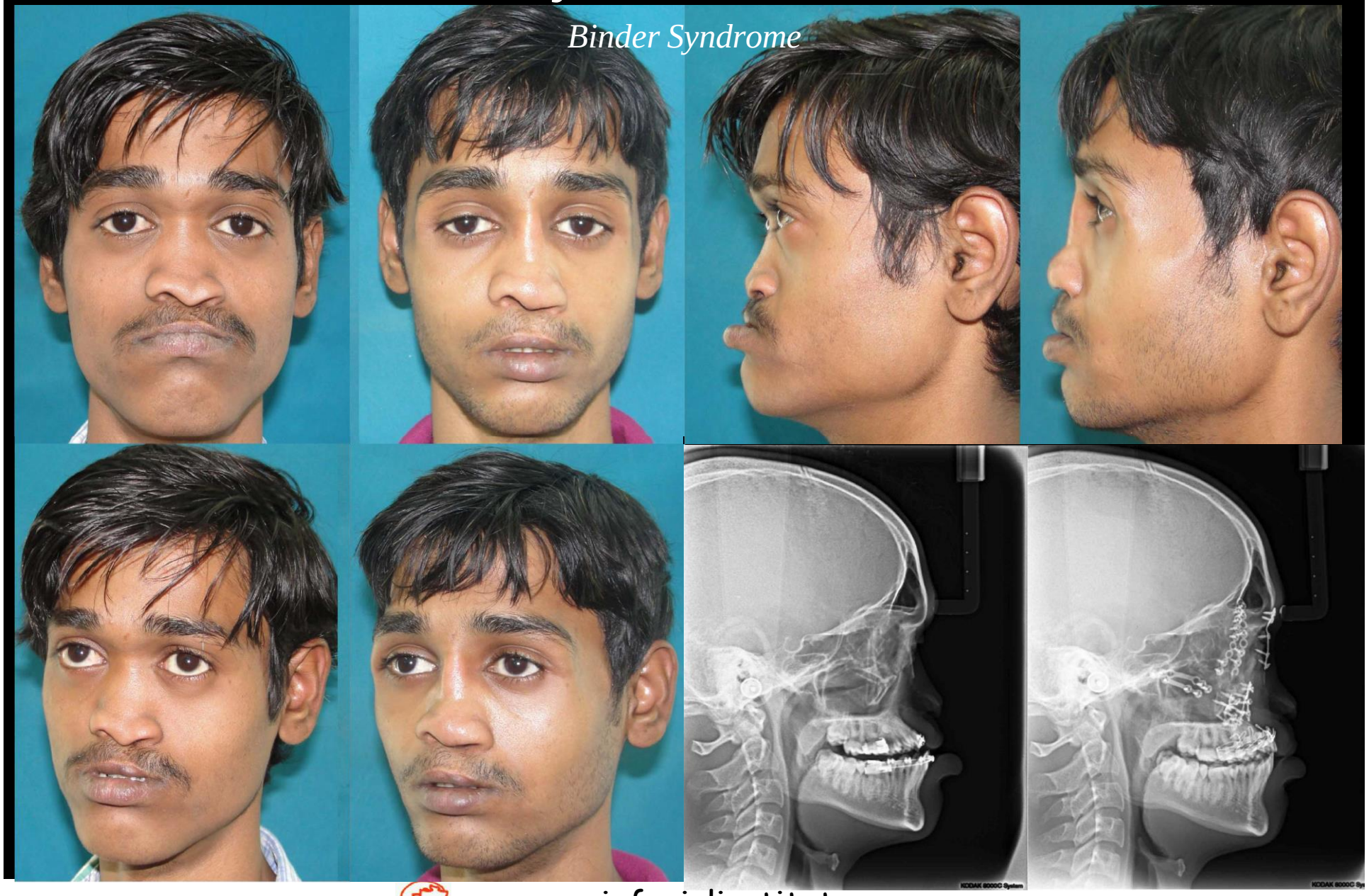

www.craniofacialinstitute.org

Craniofacial Syndromes and Anomalies

Hemifacial Microsomia

Type I

Type II a

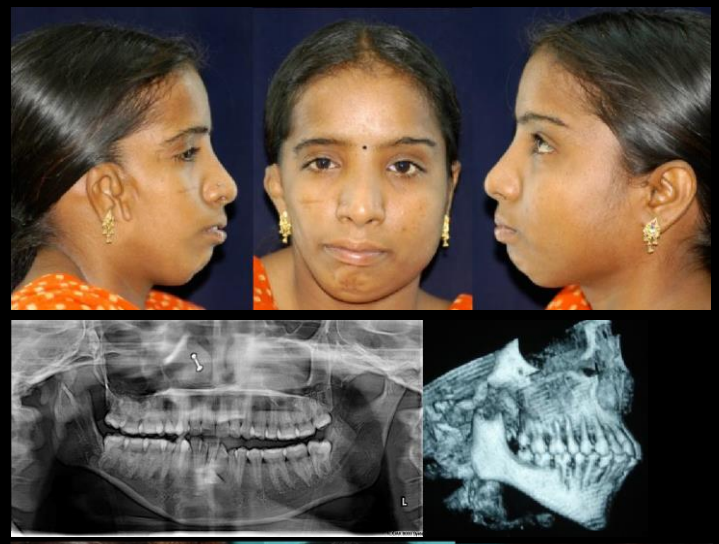

Type II b

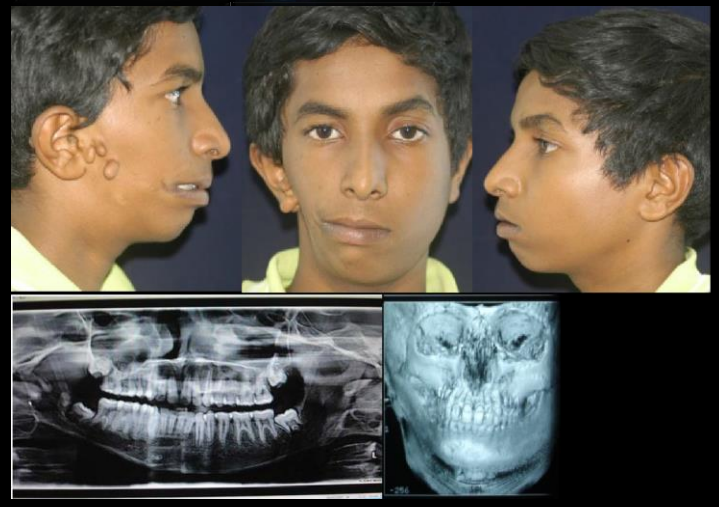

Type III

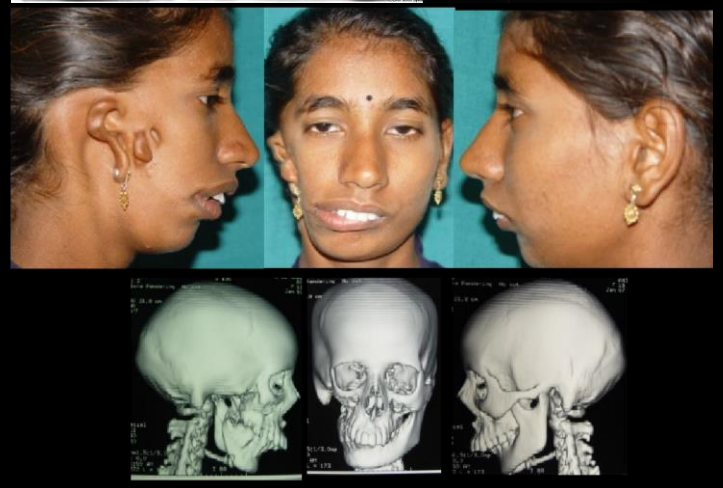

Type I HFM

Genioplasty

Type I HFM

Type I HFM

Surgery Stage I

Soft tissue closure

Type I HFM

Surgery Stage II

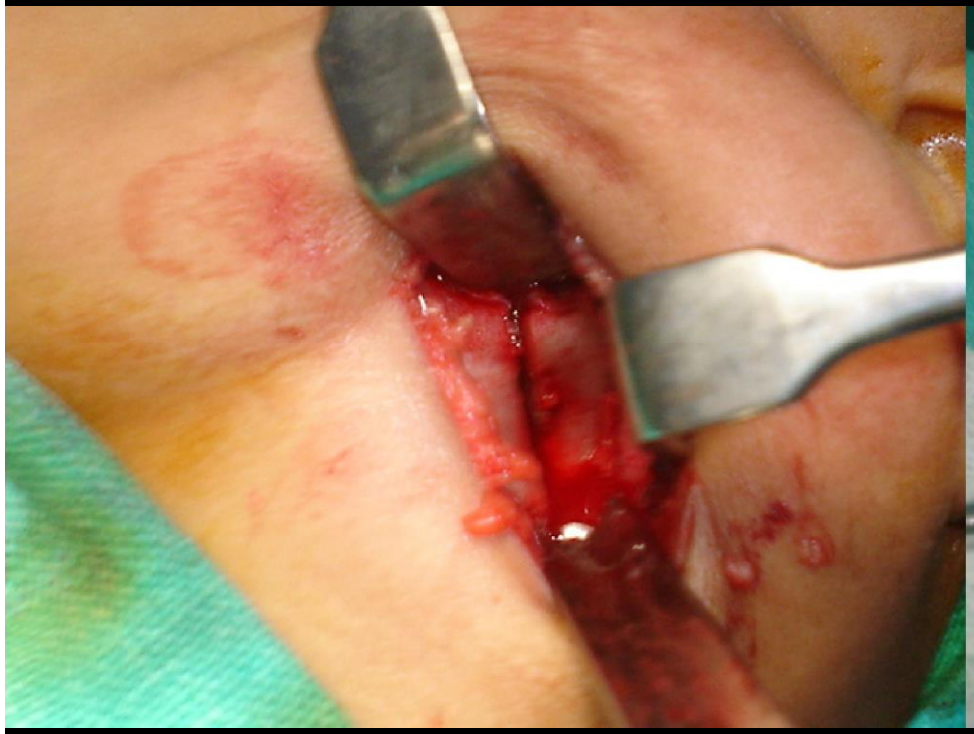

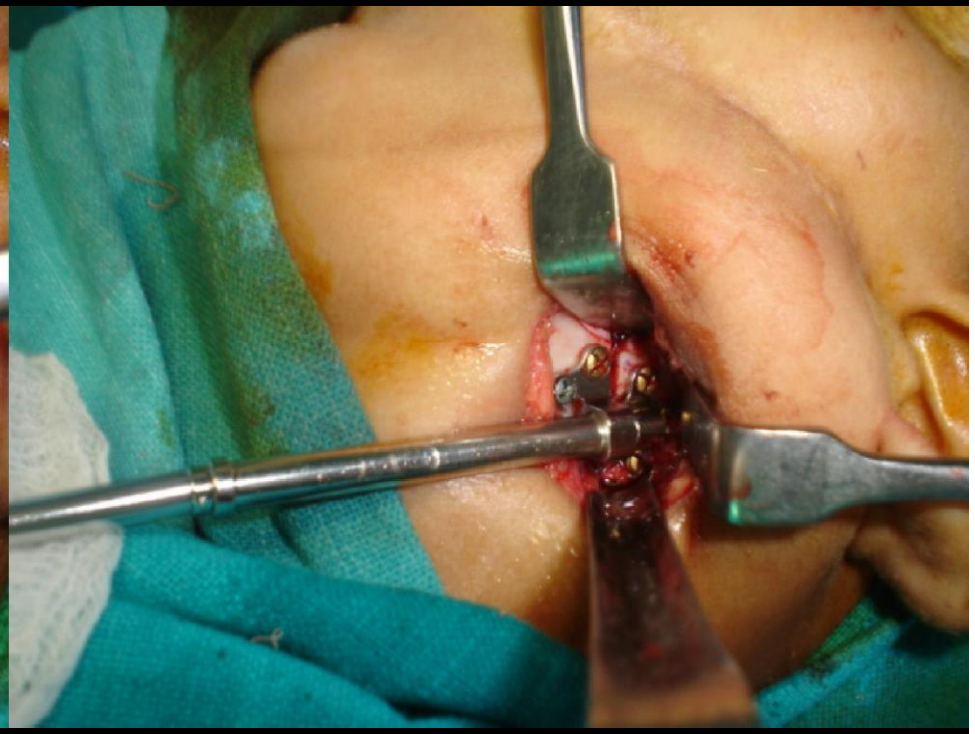

Distraction

Type I HFM

Surgery Stage II

Type II b HFM

www.craniofacialinstitute.org

Type II b HFM

Surgery

Type II b HFM

Surgery

Type III HFM

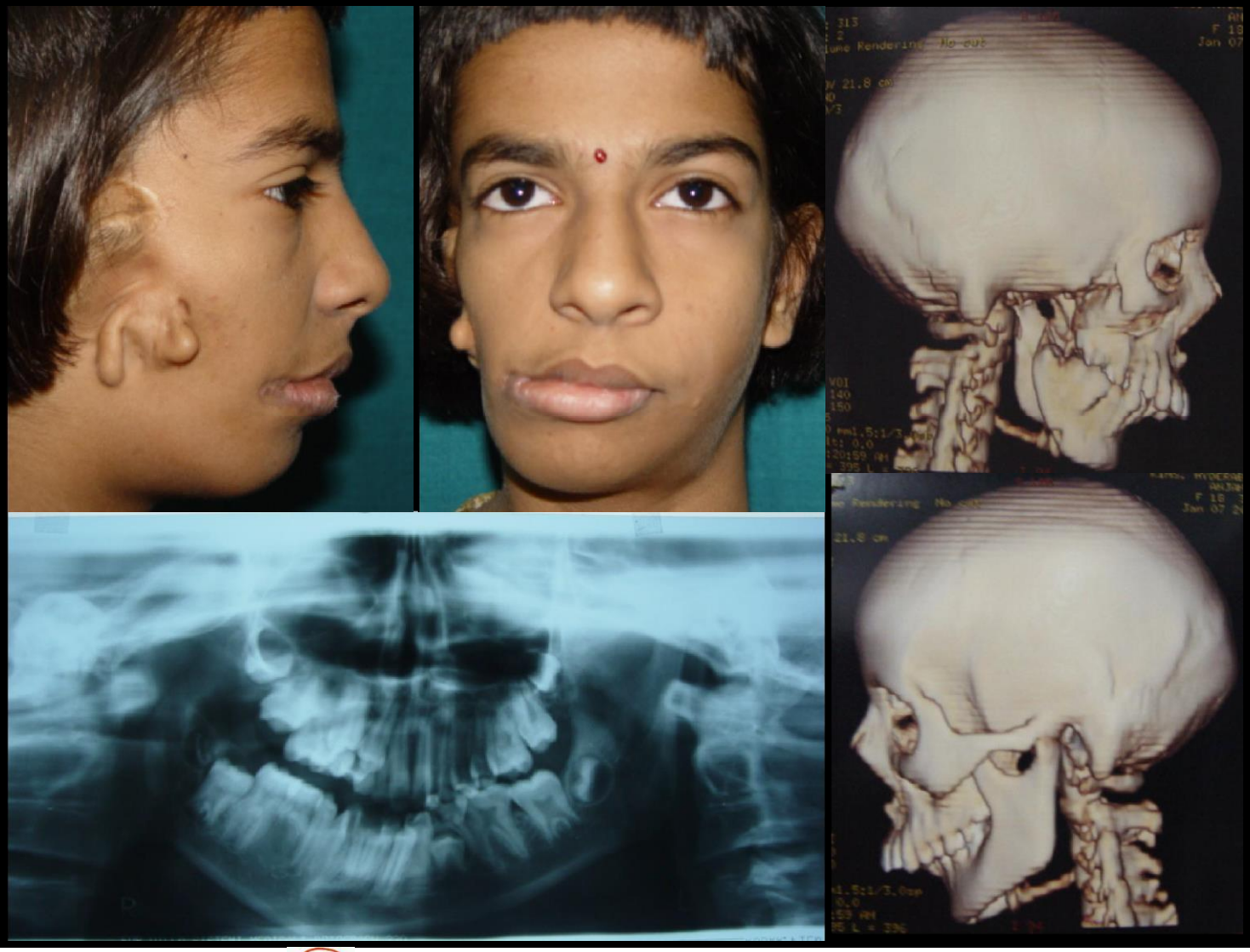

Type II b HFM

Surgery

www.craniofacialinstitute.org

Type II b HFM

Surgery

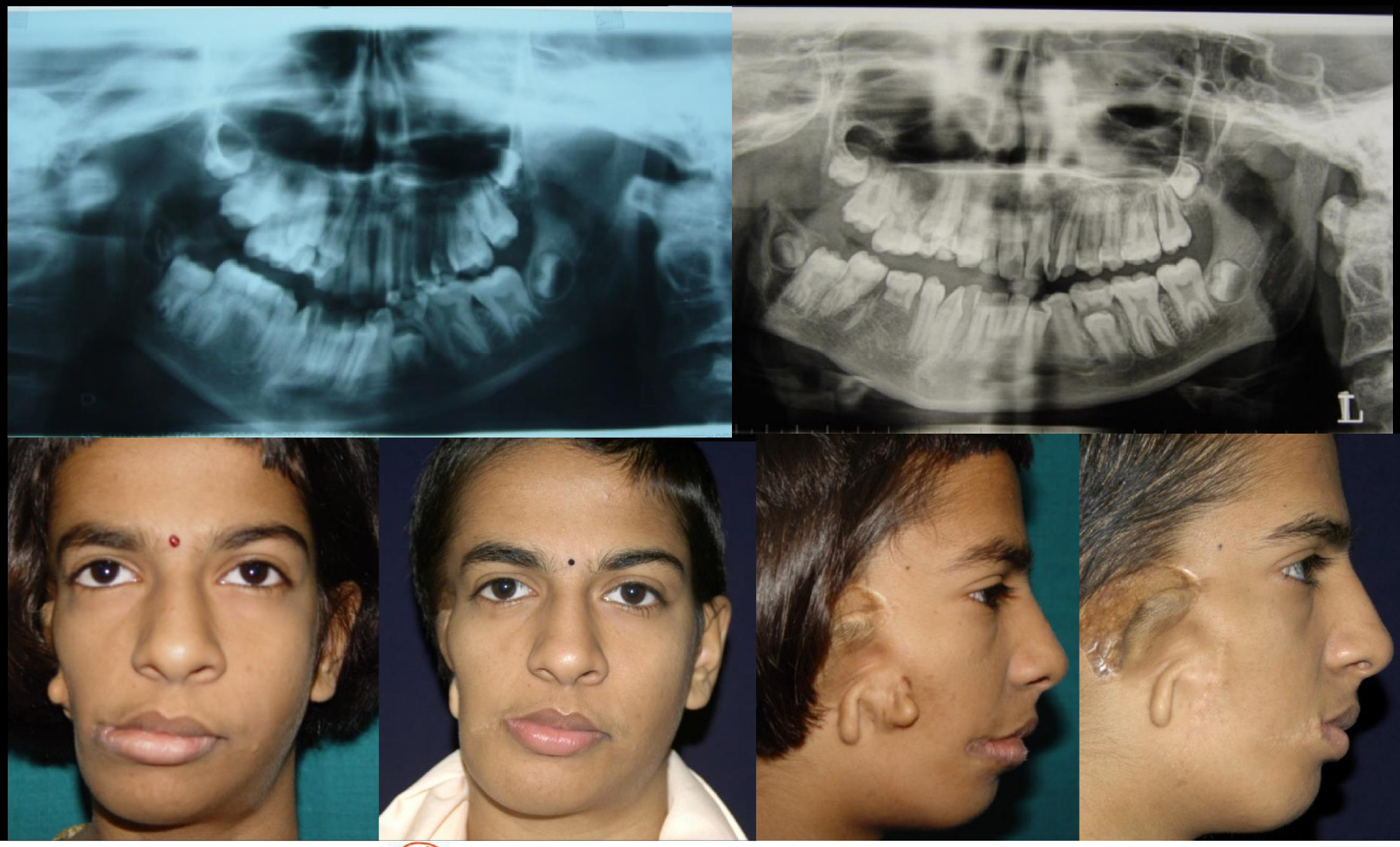

www.craniofacialinstitute.org

Craniofacial Syndromes and Anomalies

Pierre Robin Sequence/Craniofrontonasal Dysplasia

Pierre Robin Sequence

www.craniofacialinstitute.org

Craniofacial Syndromes and Anomalies

Pierre Robin Sequence/Craniofrontonasal Dysplasia

Craniofacial Syndromes and Anomalies

Pierre Robin Sequence/Craniofrontonasal Dysplasia

Pierre Robin Sequence

Craniofacial Syndromes and Anomalies

Pierre Robin Sequence/Craniofrontonasal Dysplasia

Hypertelorism

Naso-orbital Complex

Hypertelorism

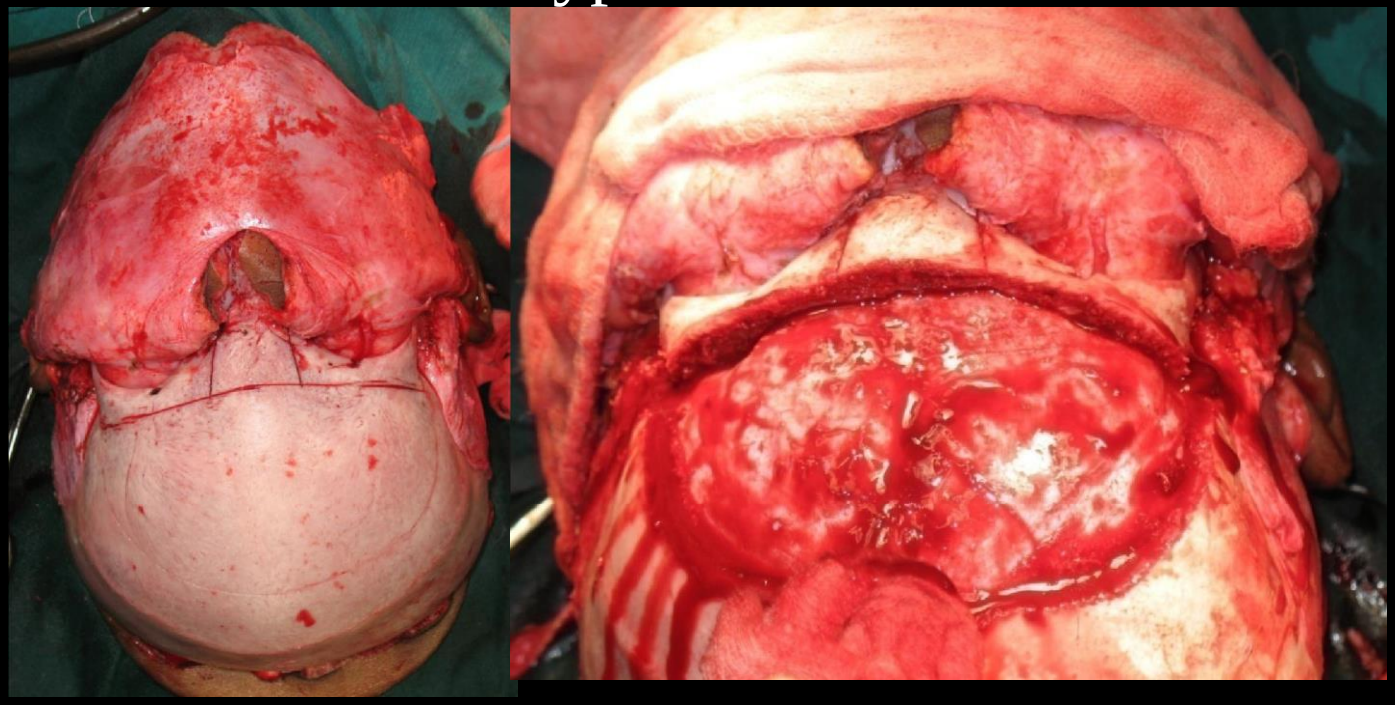

Transfrontal Craniotomy

This includes a transfrontal craniotomy with an intervening frontal bar, which is left intact.

The frontal bar results from parallel osteotomies that are atleast 1 cm from the supraorbital rims and permits orientation of the orbits once they have been mobilized

Naso-orbital Complex

Hypertelorism

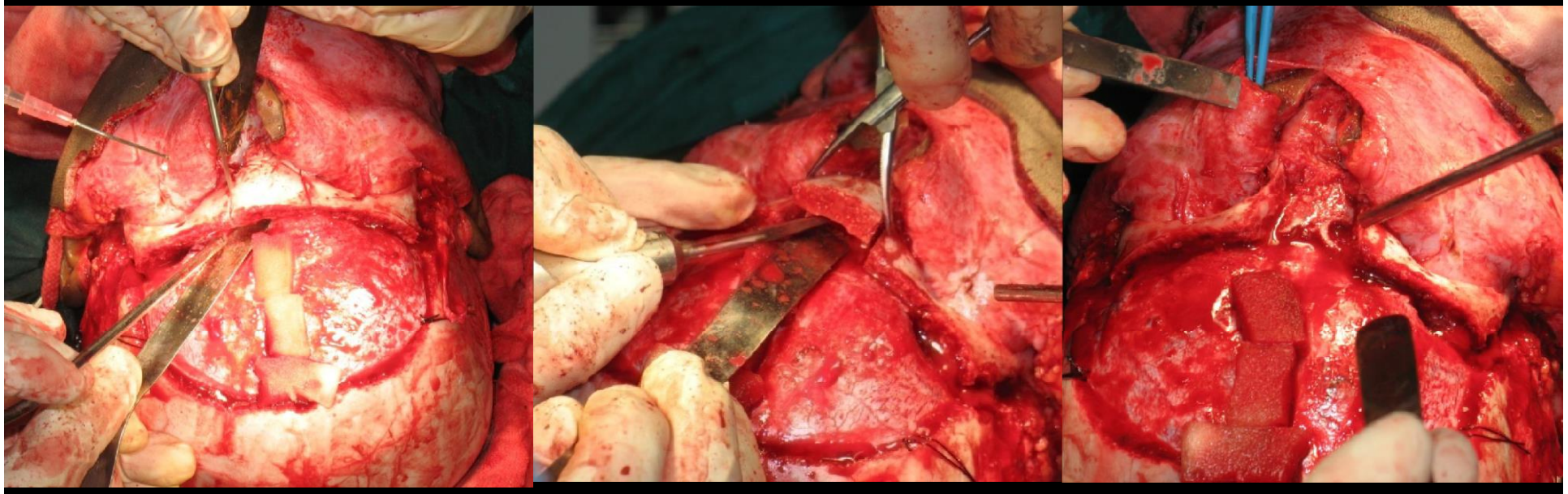

Orbital roof osteotomy

The bony cuts of the orbital roofs are performed with intracranial visualization

Orbital approximation

A central block of bone is removed between the orbits to allow their approximation in a medical direction.

Naso-orbital Complex
Hypertelorism

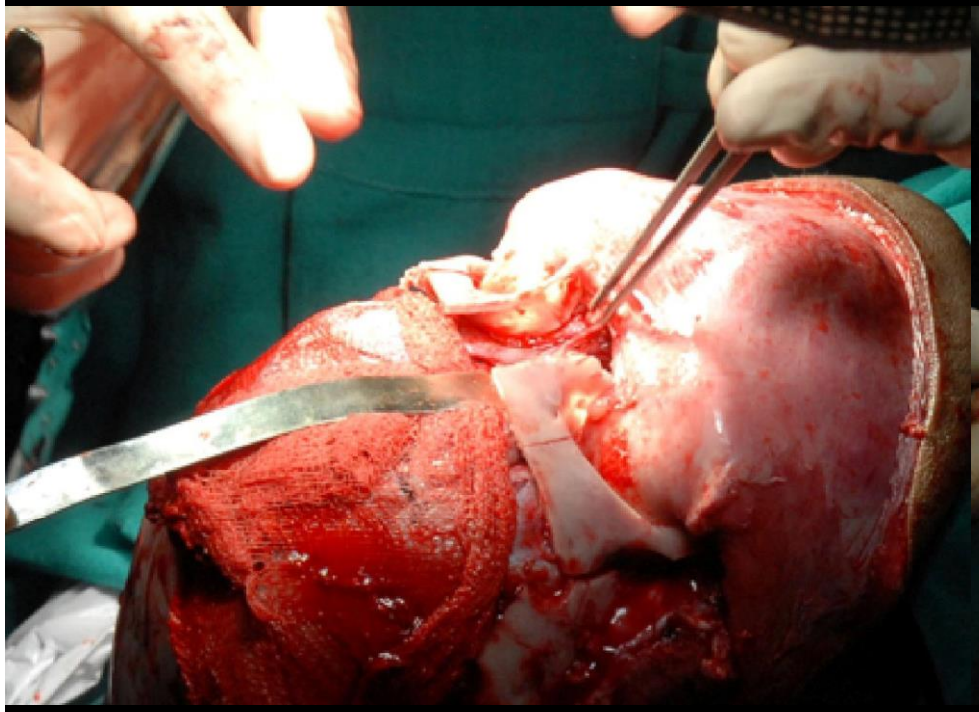

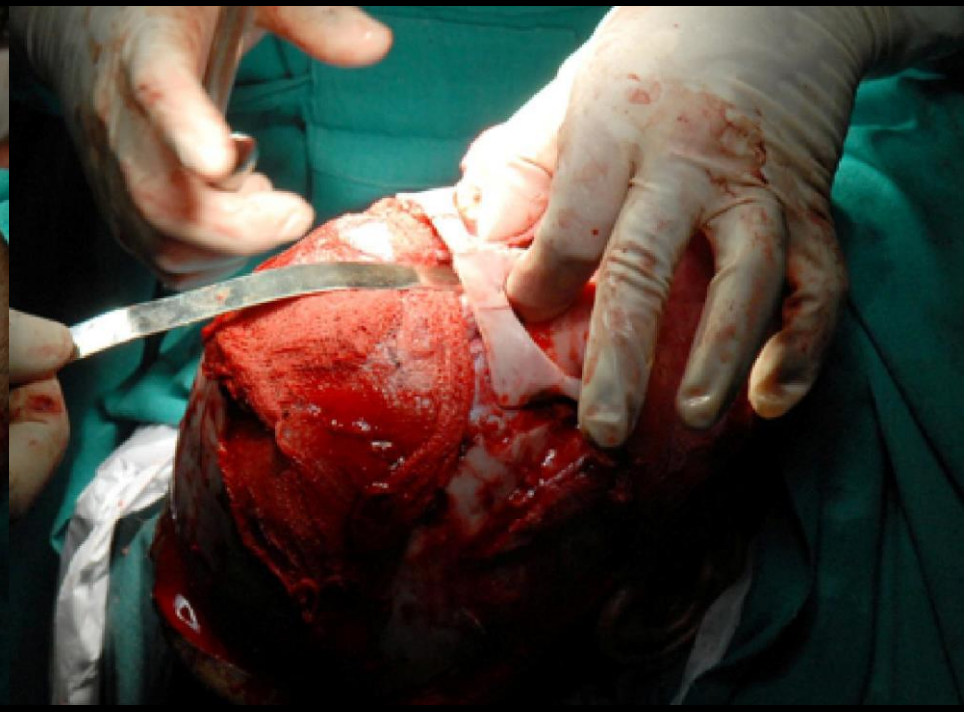

Finishing osteotomy

Finally, a wedge of bone is removed from either side of piriform fossa so that the nasal airways are not constricted when the orbits are moved medially.

If the osteotomies have been performed to their full depth, the orbits can be approximated by finger pressure alone

Naso-orbital Complex

Hypertelorism

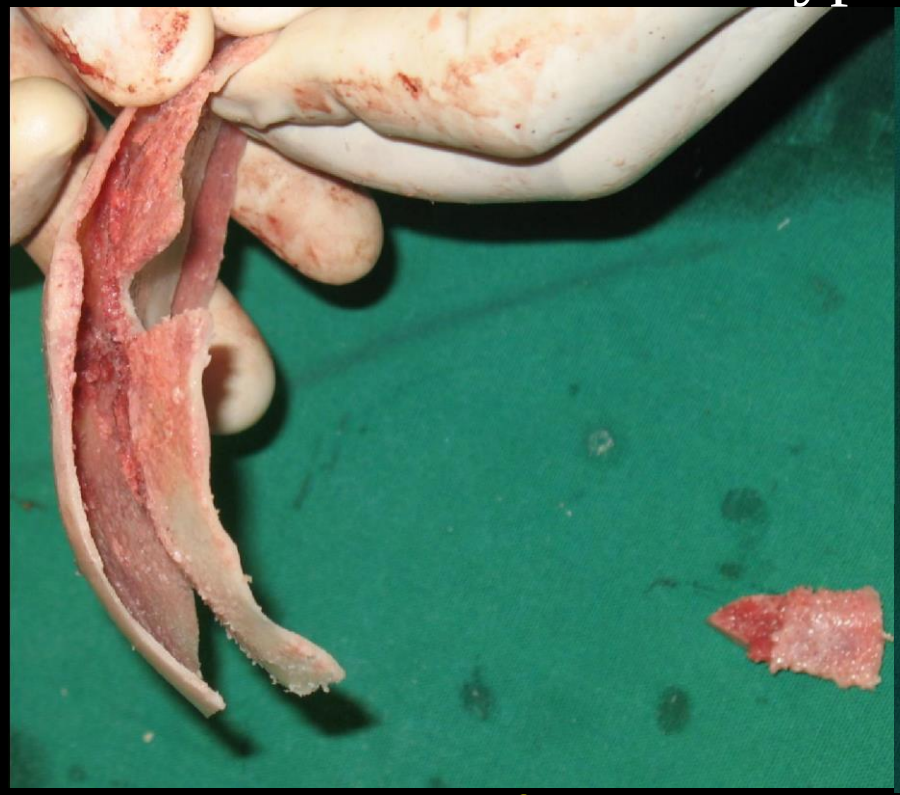

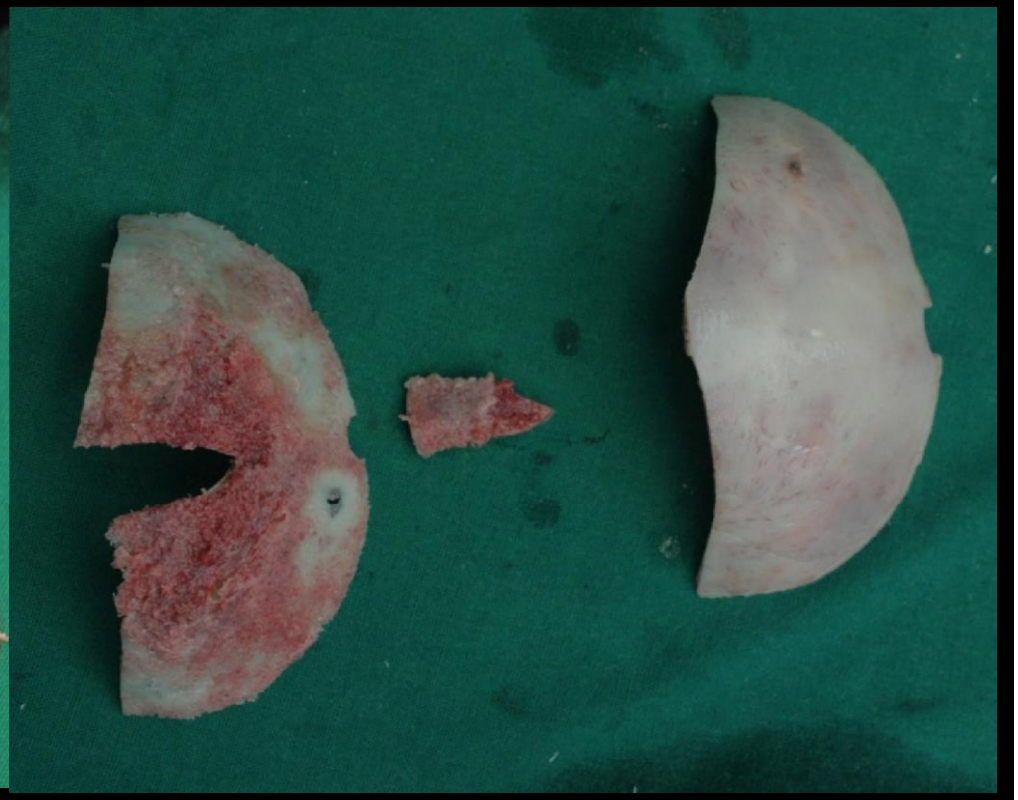

Fixation and bone grafting

Bone graft material harvested from the calvarium can be split into into the two cortices and one cortex can be used to graft bone in the defects and the other can be used to close the original defect

Naso-orbital Complex

Hypertelorism

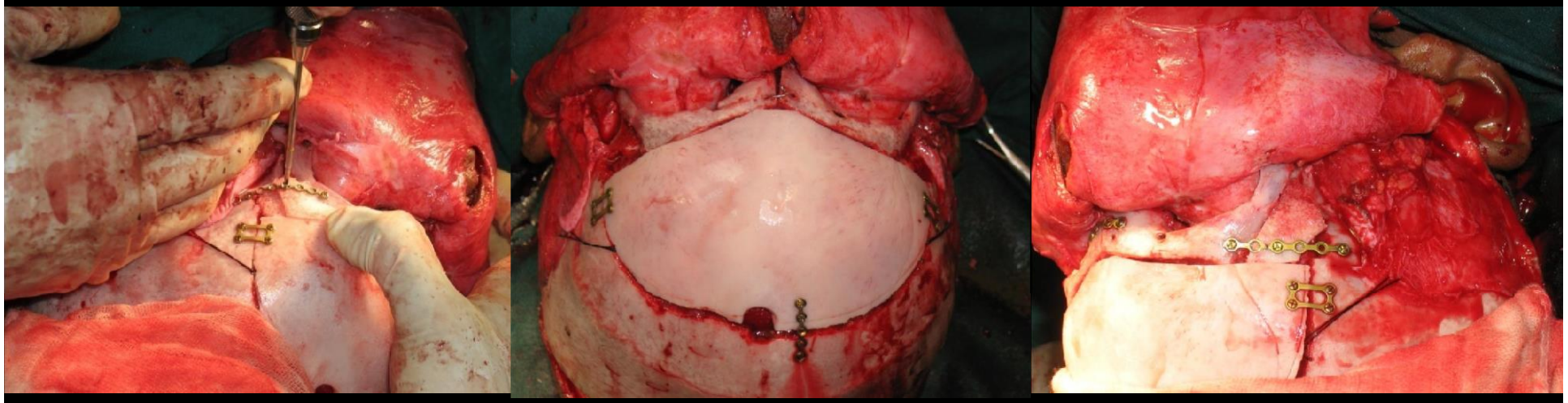

Fixation and bone grafting

The orbits are positioned and held in place with wires or micro-or miniplates.

Bone graft material harvested from the clavarium, iliac crest, or rib is then used to fill in the resulting gap defects at the lateral orbital walls and zygomatic areas

Treatment

Hypertelorism

Cranial Vault Defects

Dandy Walker Syndrome

Cranial Vault Defects

Dandy Walker Syndrome

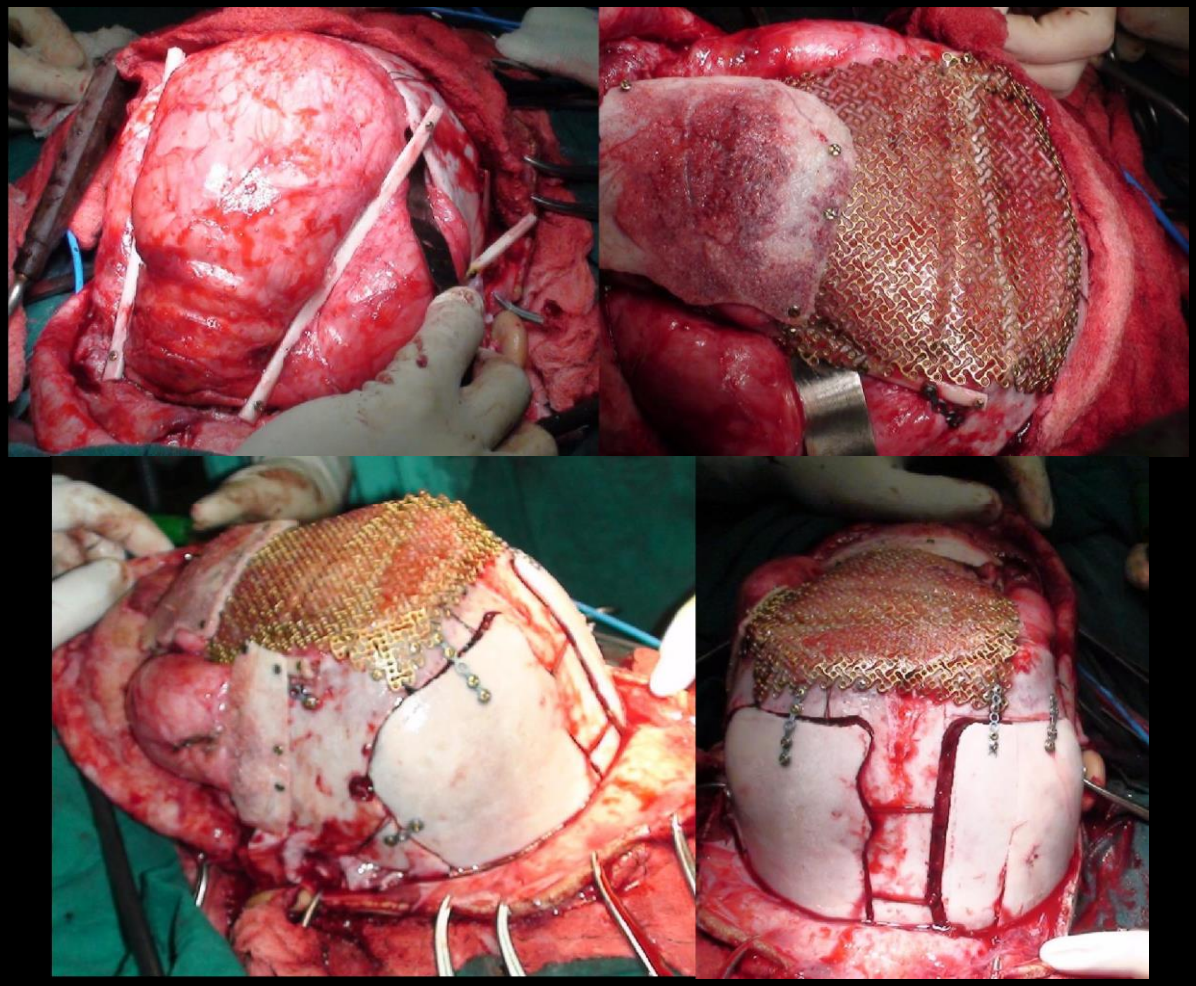

Reconstruction of posterior cranial vault with bilateral tibial bone, split calvarium and titanium mesh

Cranial Vault Defects

Dandy Walker Syndrome

Cranial Vault Defects

Dandy Walker Syndrome

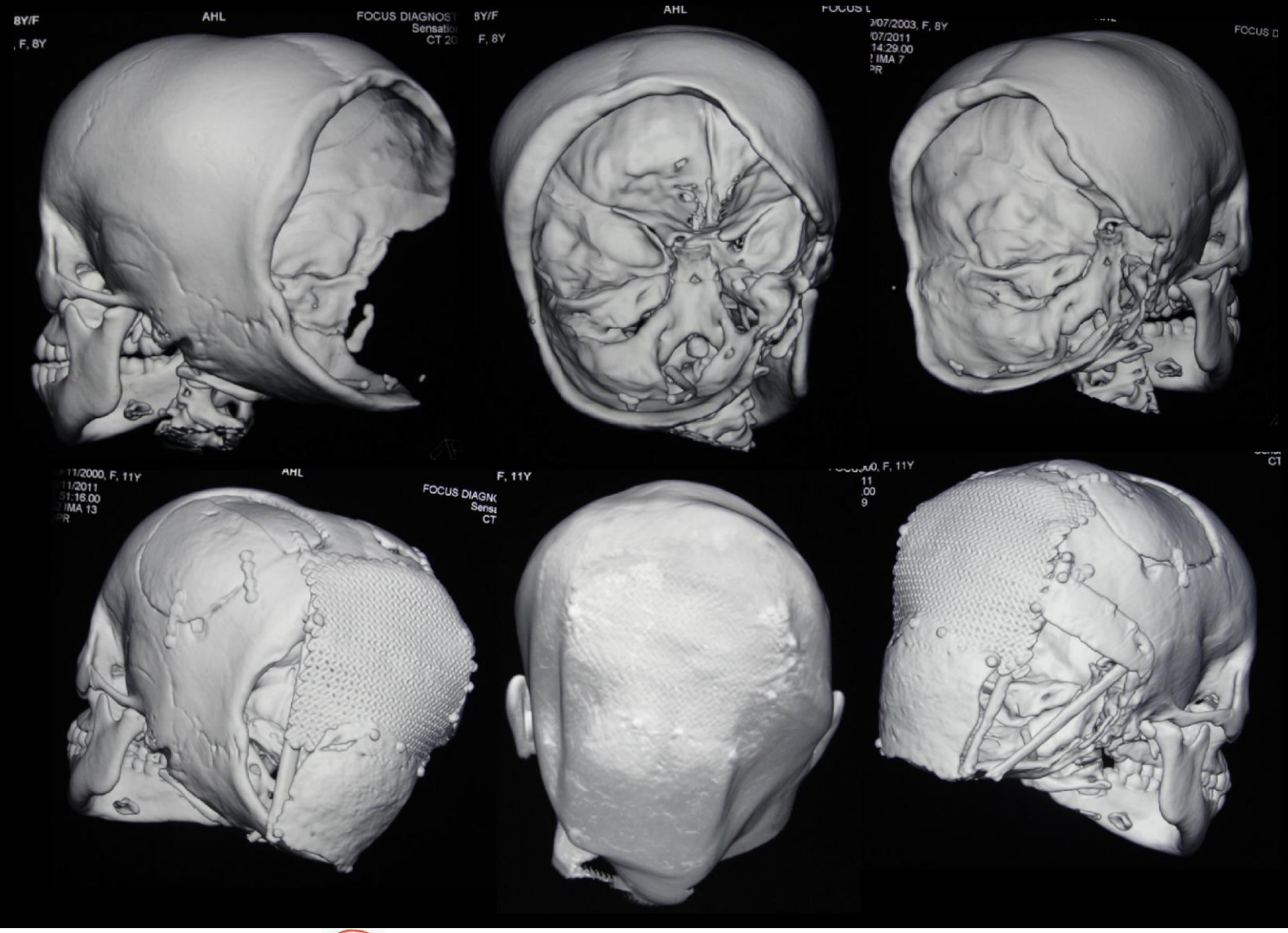

www.craniofacialinstitute.org

Craniofacial Syndromes and Anomalies

Craniofacial Clefts

Tessier #0 facial cleft

Craniofacial Syndromes and Anomalies

Craniofacial Clefts

Craniofacial Syndromes and Anomalies

Craniofacial Clefts

Unilateral Cleft Lip Repair

Incision design for unilateral cleft lip surgery

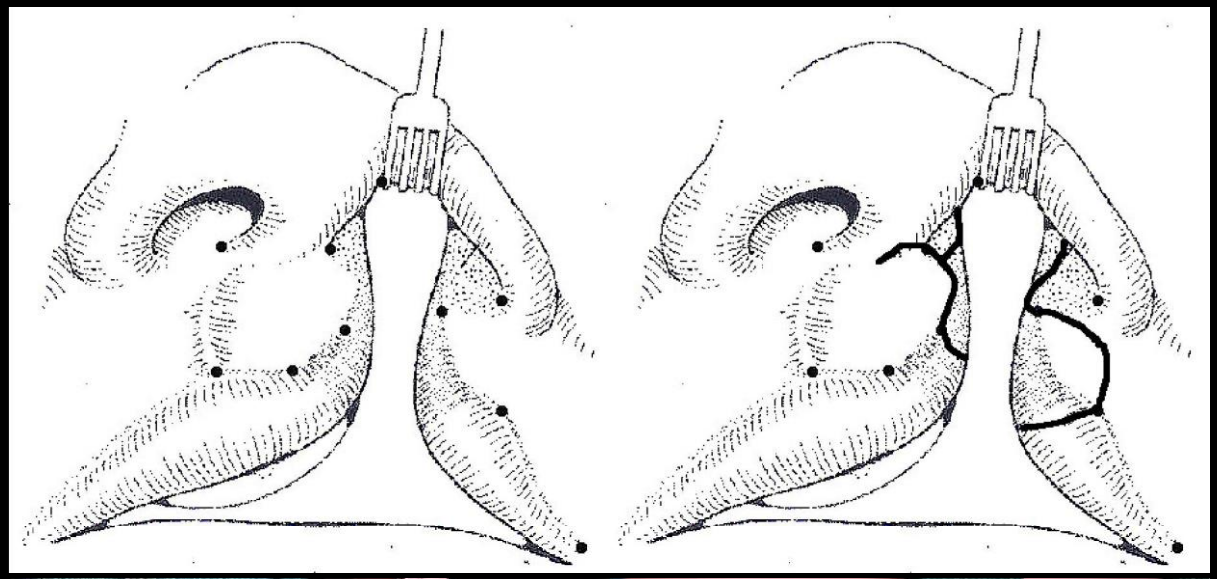

Source:

Afroze Incision for Functional Cheiloplasty, Technical Note

Gosla Srinivas Reddy et. al.; J. Craniofac. Surg. 20(8):1733-1736, September 2009.

Unilateral Cleft Lip Repair

4 years post operatively

Bilateral Cleft Lip Repair

Incision design for bilateral cleft lip surgery

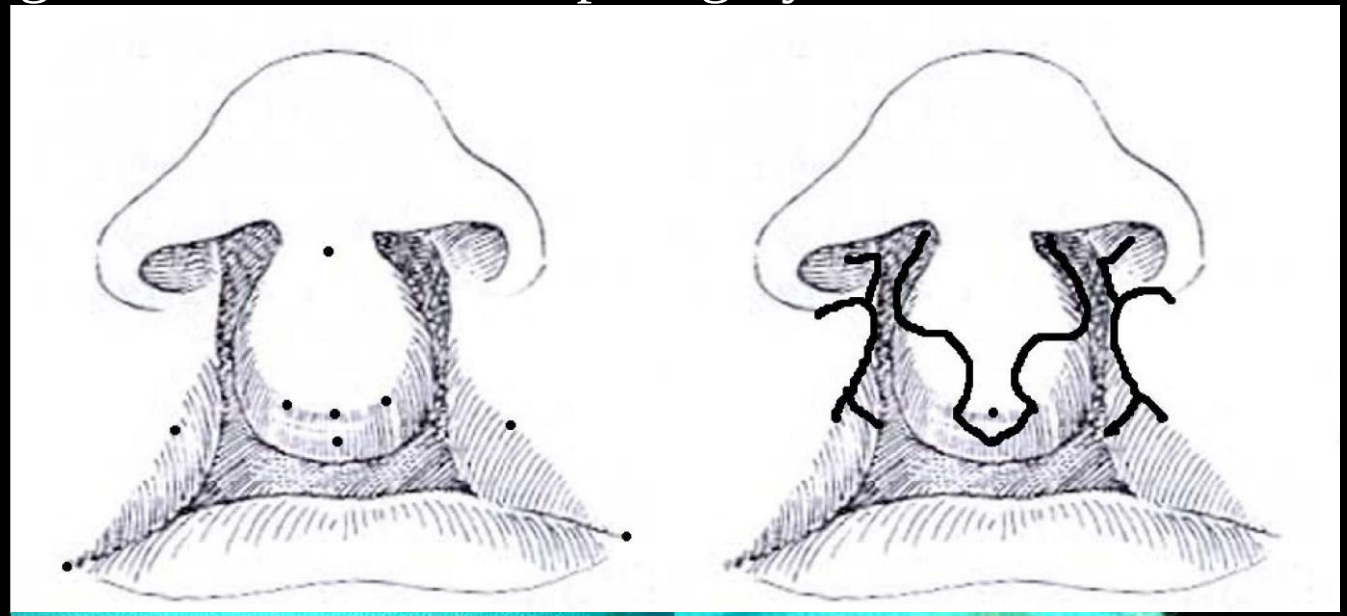

Bilateral Cleft Lip Repair

Preoperative | 5 days postoperatively | 18 months postoperatively | 3 years postoperatively

Cleft Palate Repair

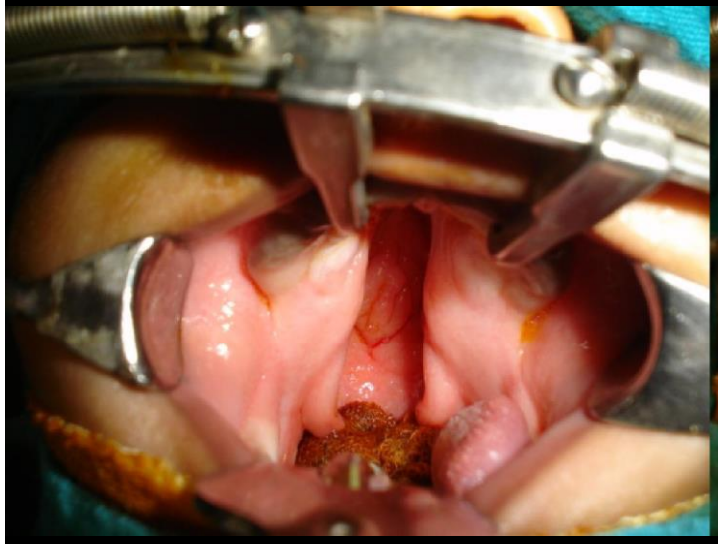

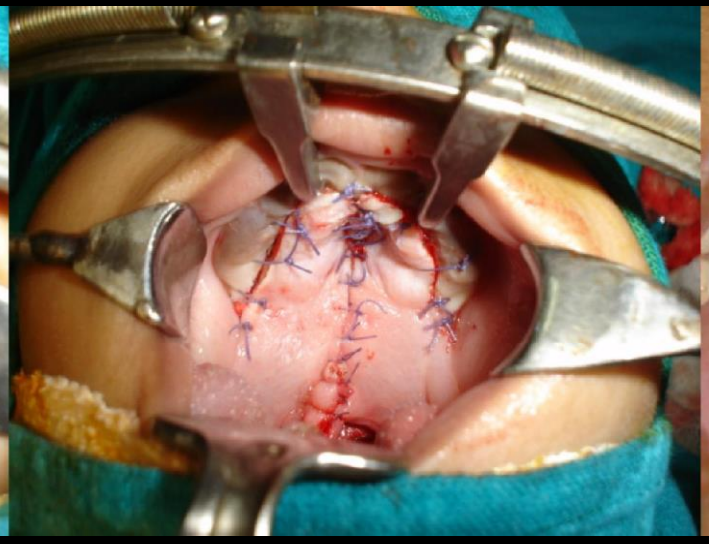

Complete Palate Repair

Follow up at age 8 years

Benign and Malignant Head and Neck Tumors

Encephaloceles

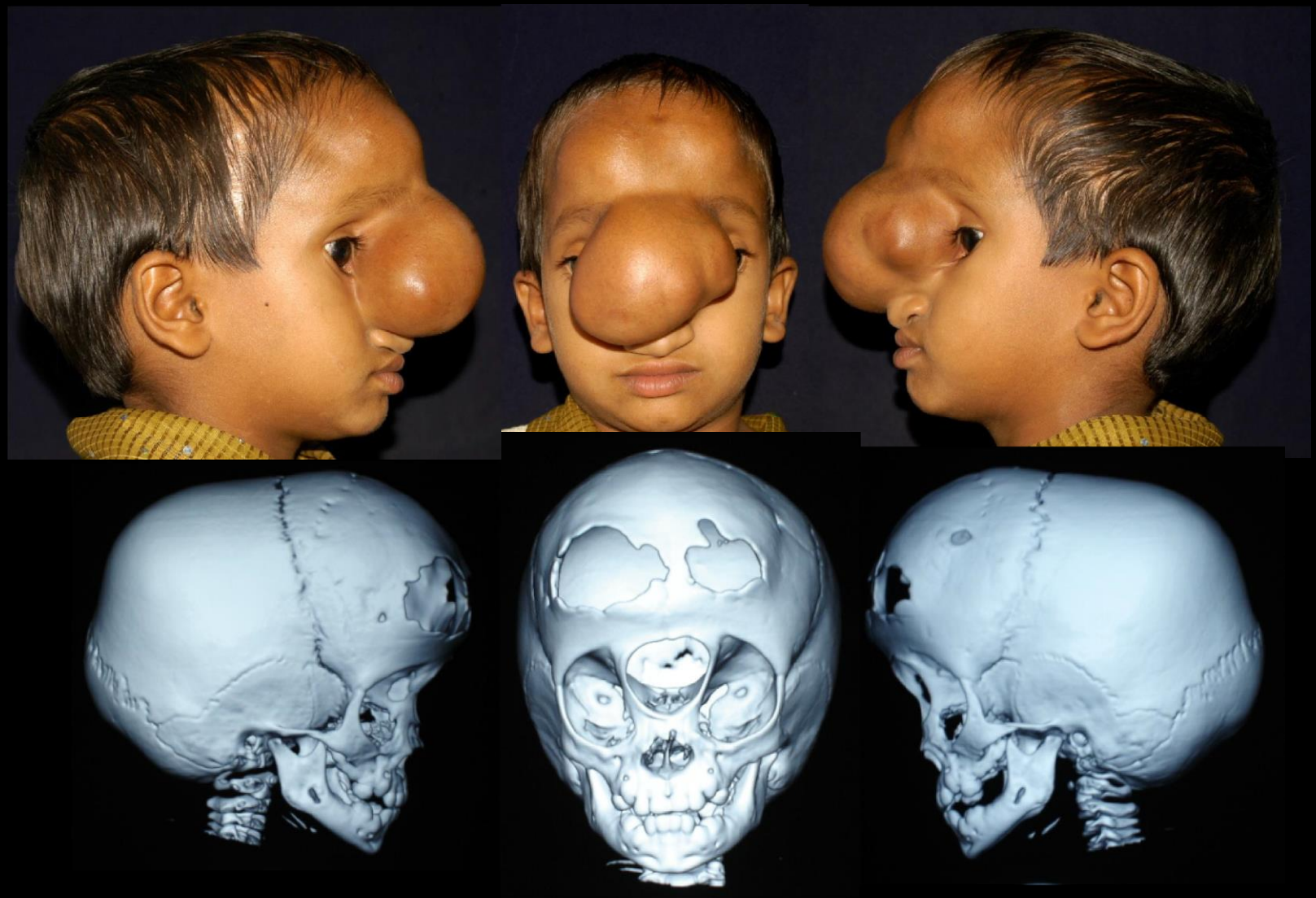

Treatment

Nasal encephalocele

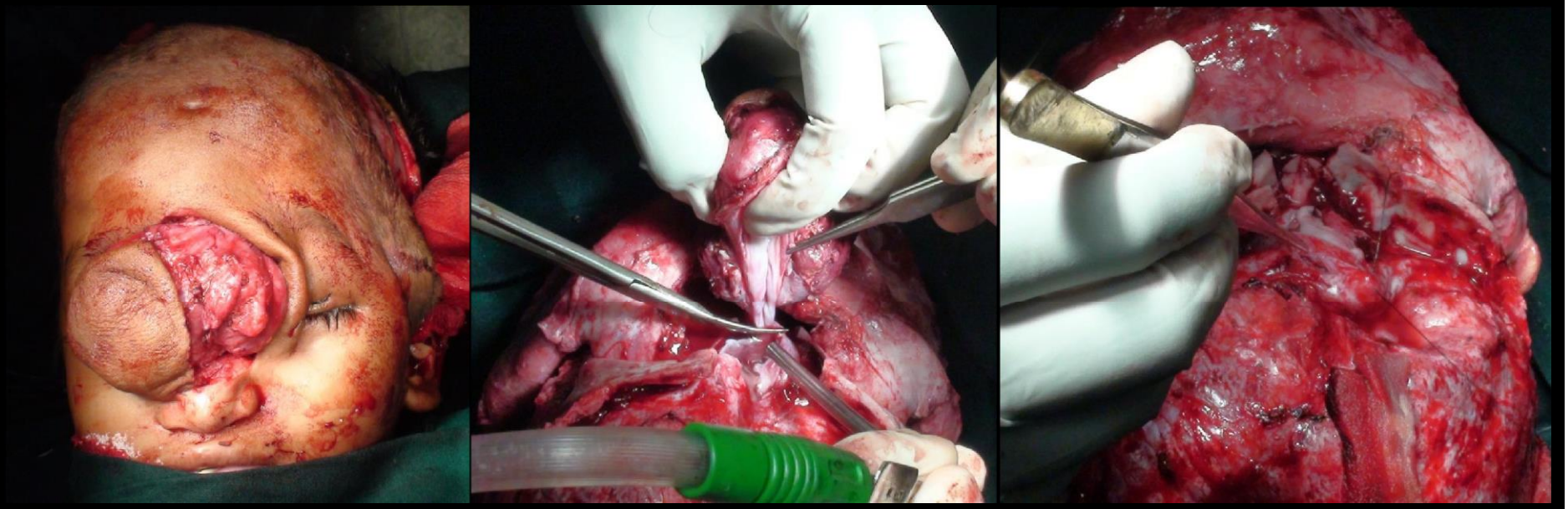

Encephalocele Resection

Treatment

Nasal encephalocele

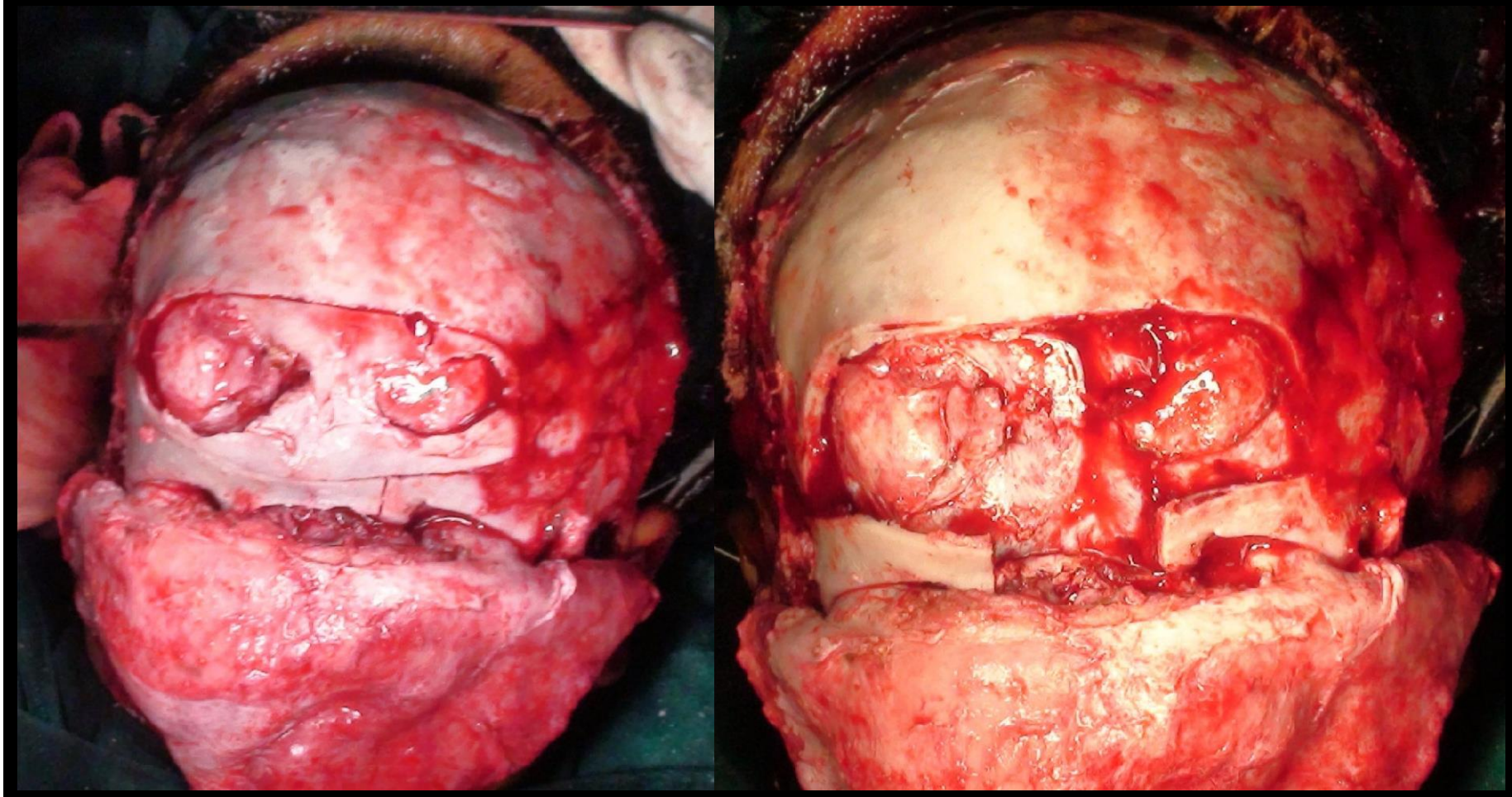

Transfrontal Craniotomy

Treatment

Nasal encephalocele

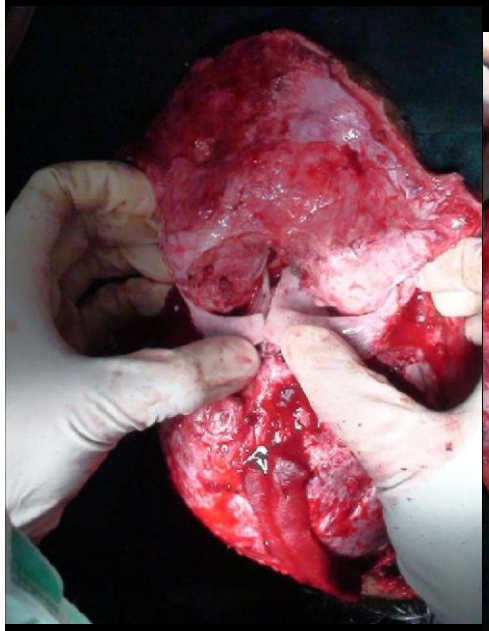

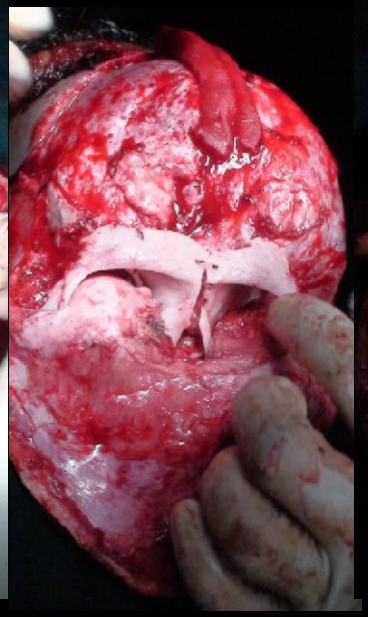

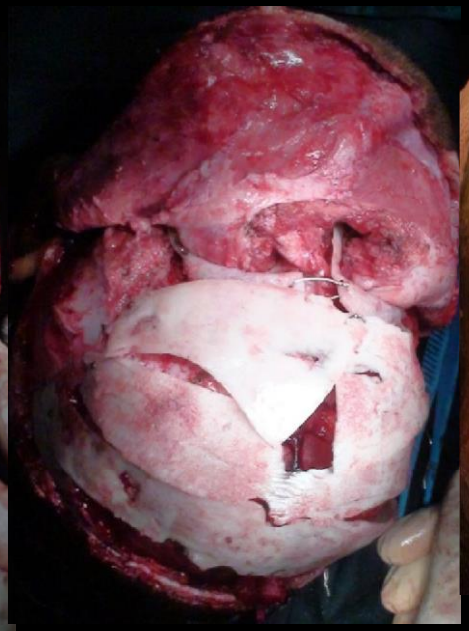

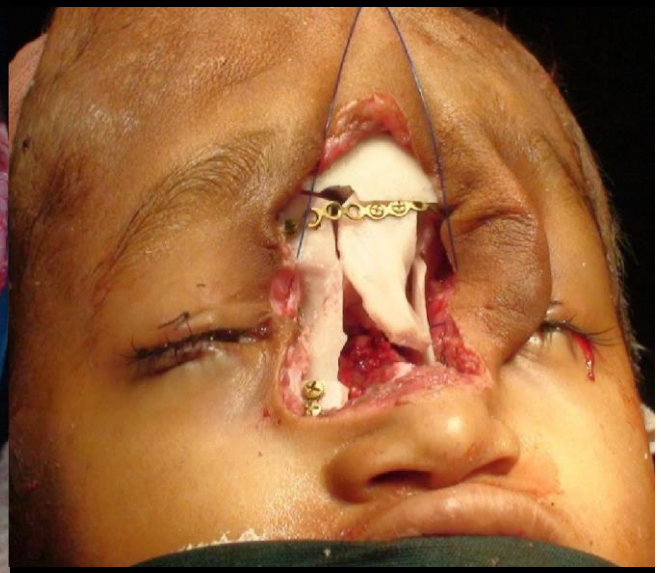

Finishing osteotomy, fixation and closure

Treatment

Nasal encephalocele

www.craniofacialinstitute.org

Benign and Malignant Head and Neck Tumors

Hemangiomas/Vascular Malformations

Vascular Malformations

Capillary

Venous

Lymphatic

Arterio-venous

Hemangioma

Sclerotherapy

- Syrup or Tablet Propranolol: 0.5 -1 mg/kg of body weight in two divided doses for 6 months under strict pediatric supervision

  (***Propranolol***, β-blocker, vascoconstrictor, regulating angiogenic pathways inducing apoptosis of vascularized endothelial cells)

- Injection Triamcinolone (Kenocort): One 20 mg /ml vial diluted in 2 ml saline and 1ml lignocaine injected intralesionally, once a month for six months.

  (***Triamcinolone***, corticosteroid suppresses vasculogenic capability of multipotent stem cells)

- Contractubex (10% aqueous onion extract, 50 U heparin per gram of gel,1% allantoin) gel and olive oil: massage on the lesion twice daily till the regression of the lesion.

Surgical Protocol

- Key is Accessibility

  Accessible = Surgery

  Inaccessible = Embolisation and surgery

- Ligation of all possible blood vessels in the vicinity of the lesion
- Aim of surgery
  - HARMONIC SCALPEL is used to radically excise all affected tissue as remnants of necrotic tissue can form a focus of a granuloma or further infection.
  - Reconstruct what ever possible
  - Post operative maintenance with steroidal injections intra-lesionally

Treatment…

High Flow A-V Malformation

Treatment…

Hemangioma

Treatment with full thickness skin graft harvested from right groin

PATHOLOGY

PRE OP

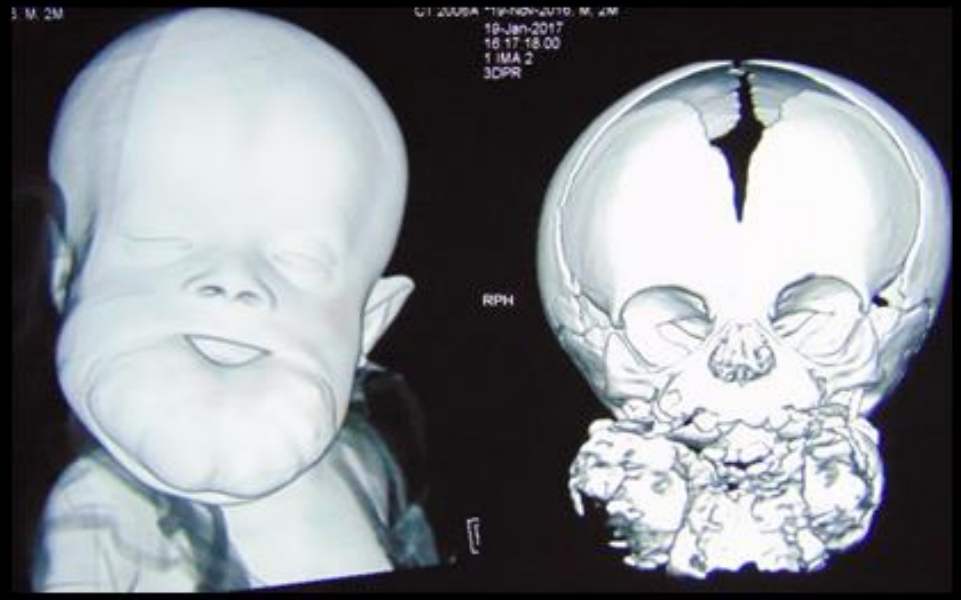

PRE OP SCANS

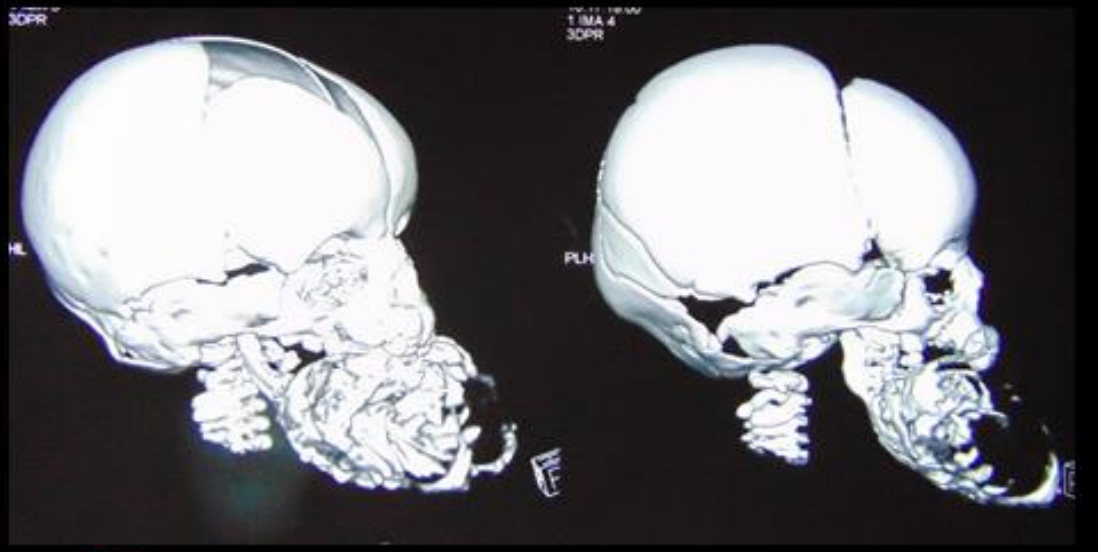

INTRAOP

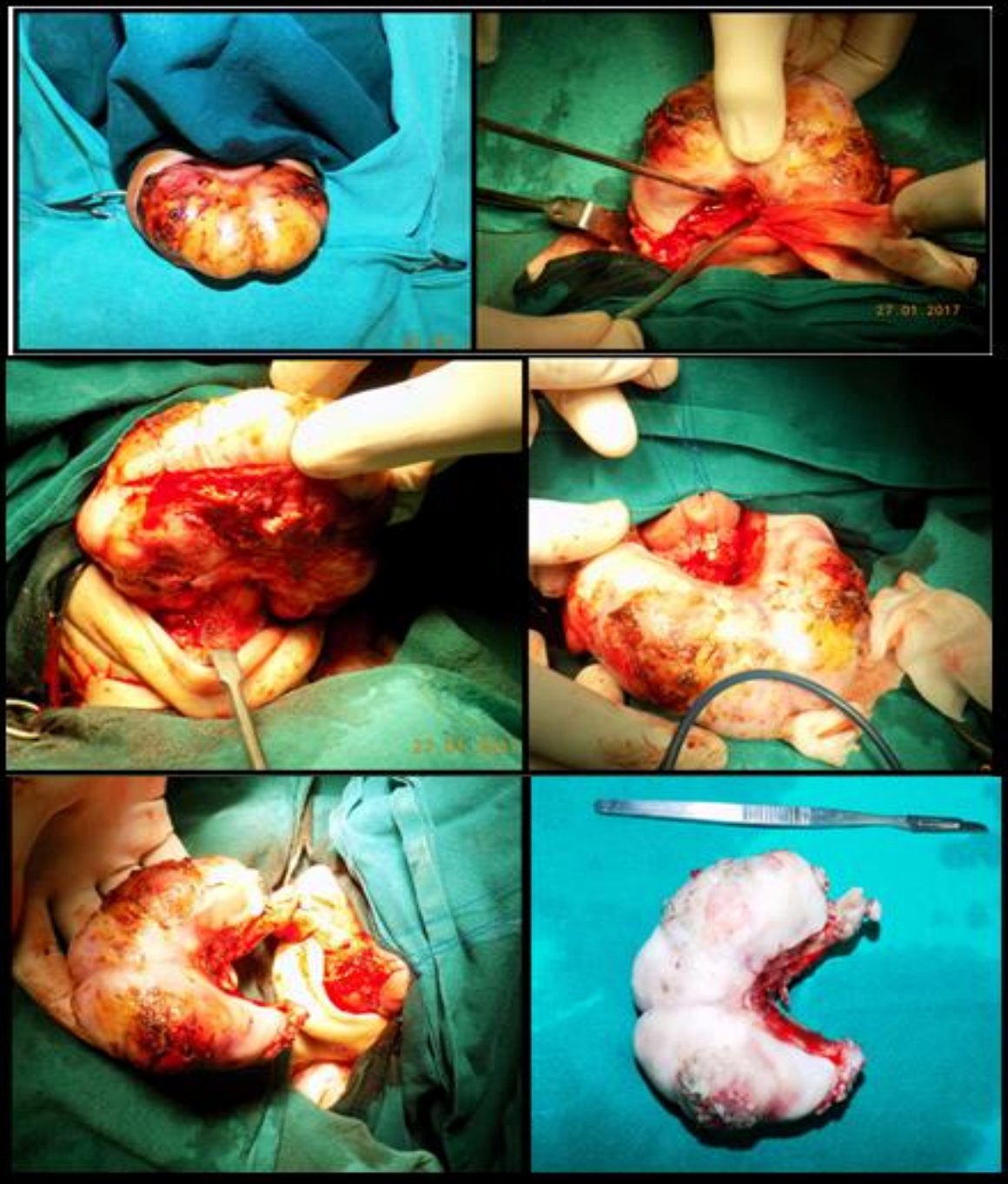

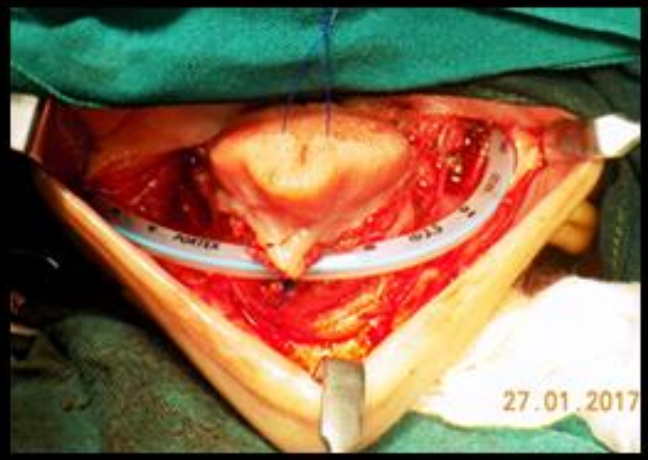

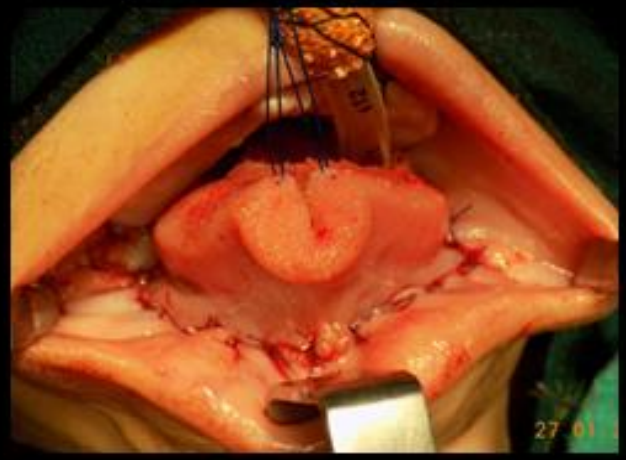

POST OP 7 DAYS

PRESENT POST OP

Craniofacial Tumors

Plexiform Neurofibroma and benign tumors

Craniofacial Tumors

Plexiform Neurofibroma and benign tumors

Craniofacial Tumors

Sarcoma and other malignancies

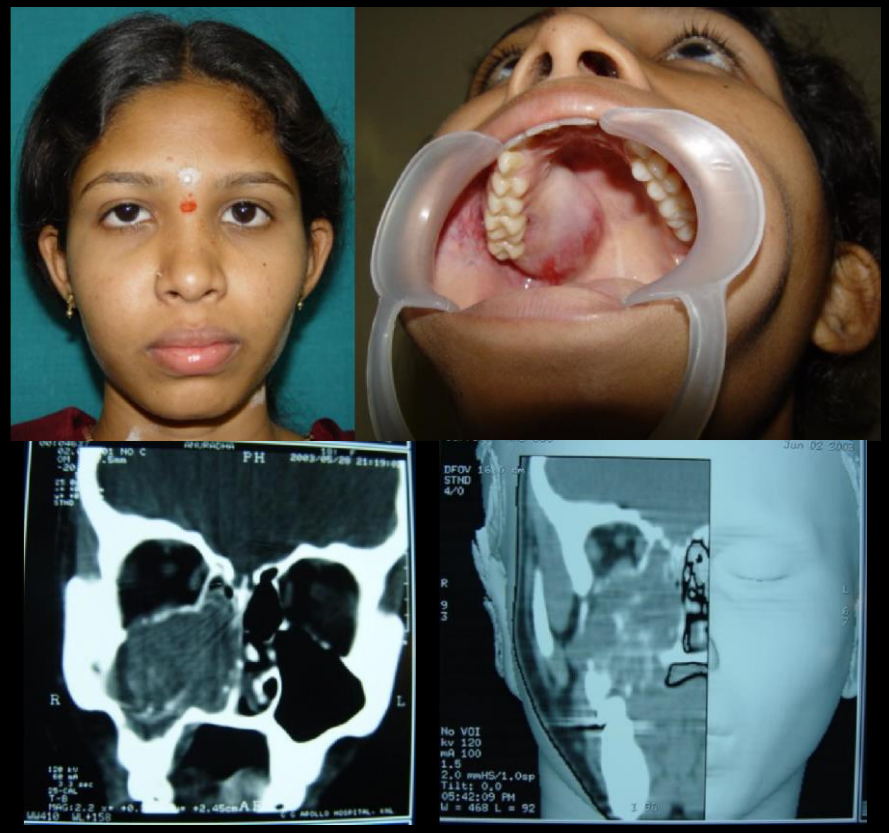

Craniofacial Tumors

Sarcoma and other malignancies

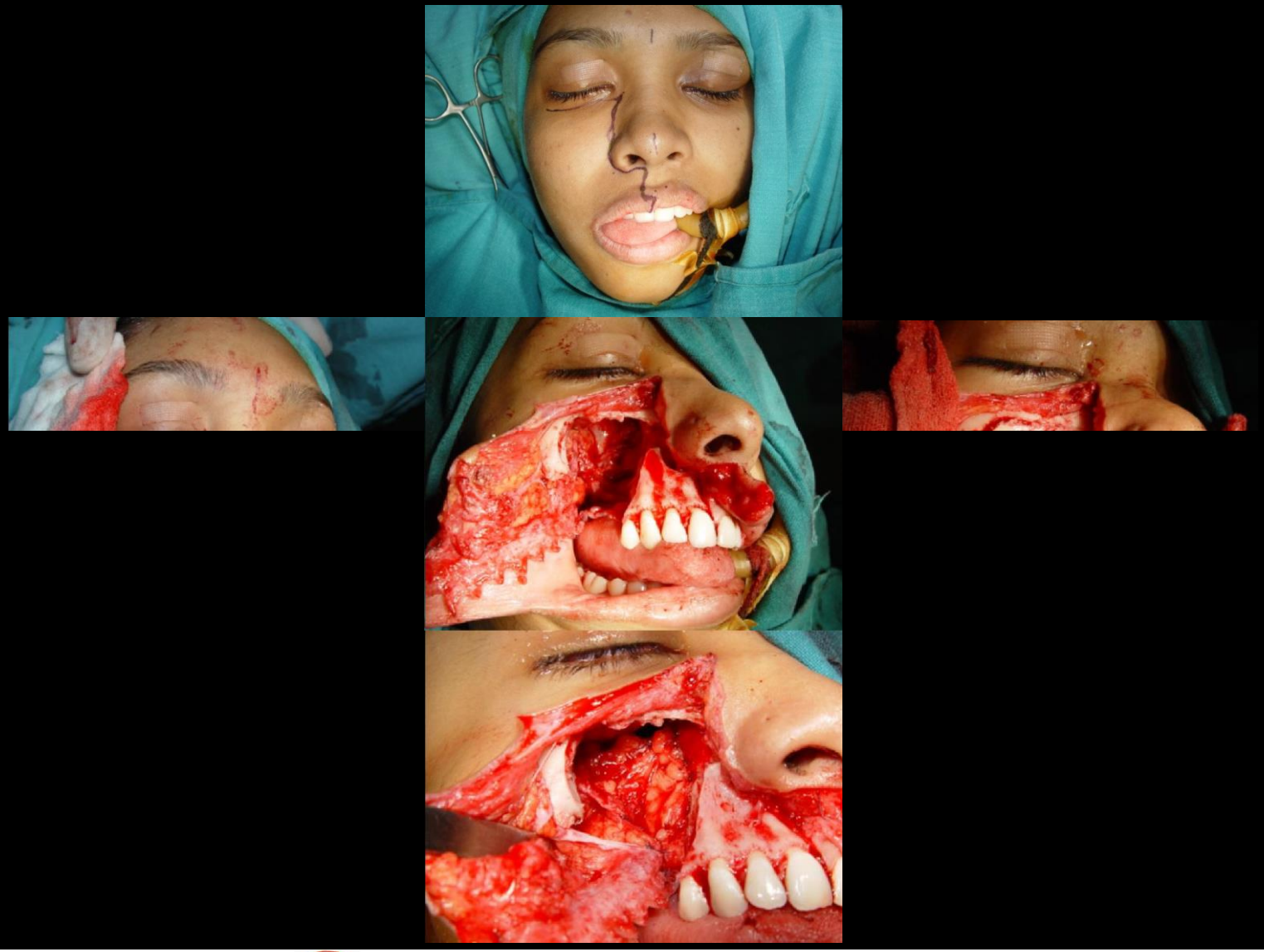

Benign and Malignant Head and Neck Tumors

Sarcoma and other malignancies

Craniomaxillofacial Trauma

Craniomaxillofacial Trauma

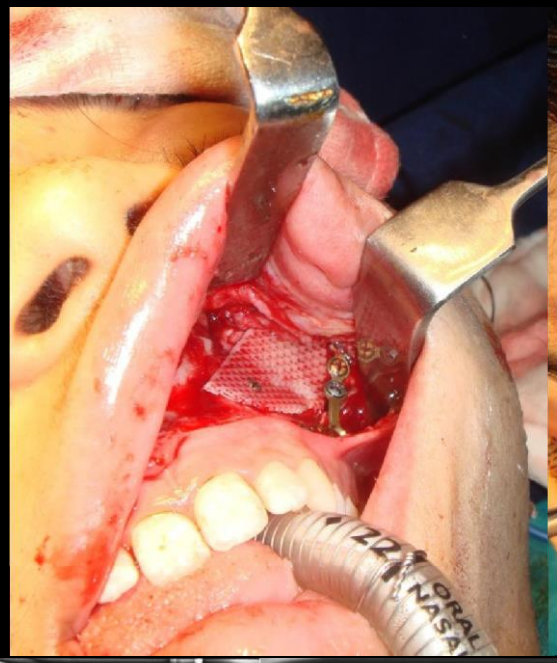

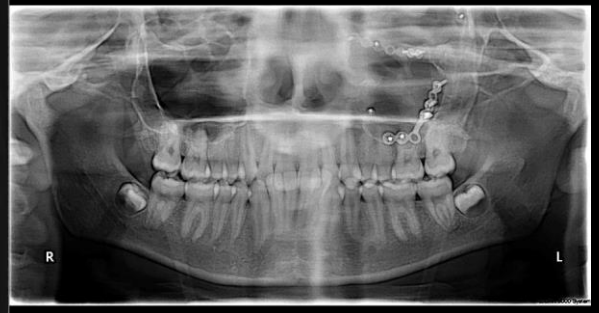

www.craniofacialinstitute.org

Craniomaxillofacial Trauma

Non-syndromic Orthognathic Deformities

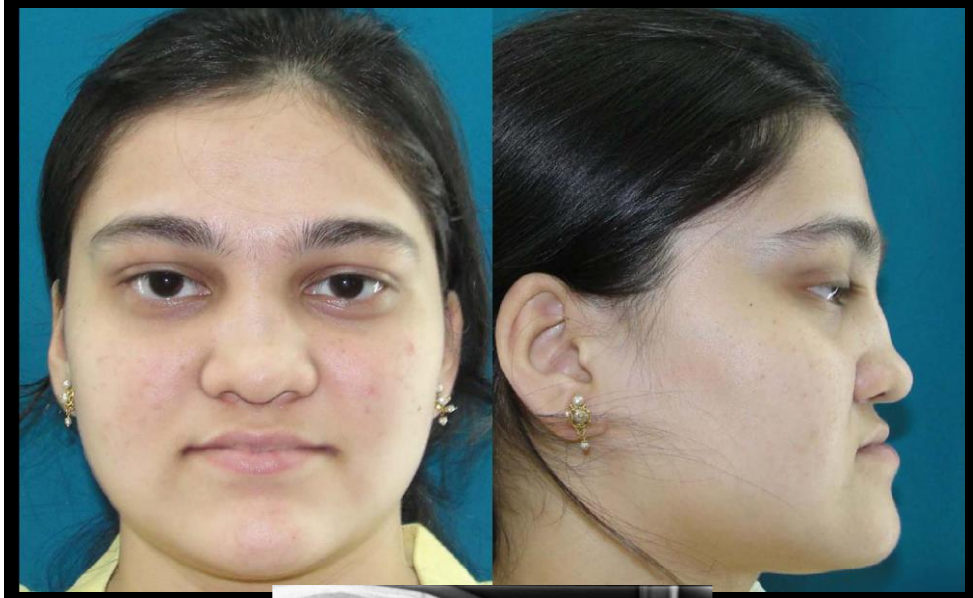

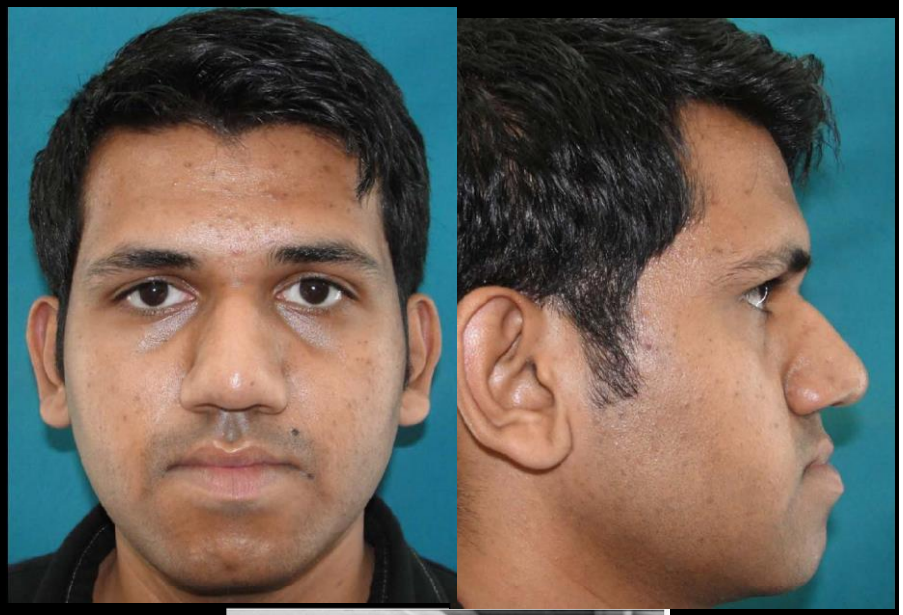

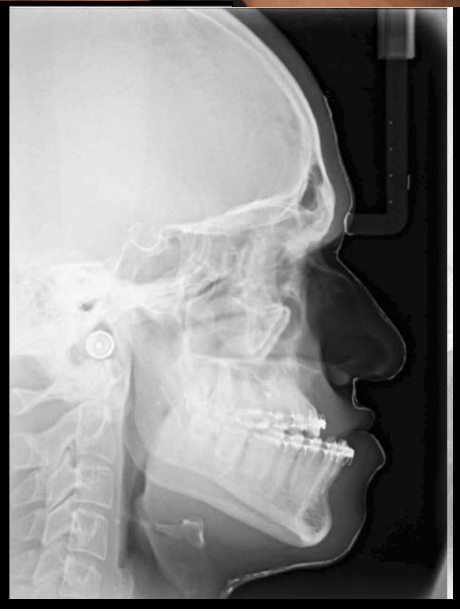

High LeFort I Osteotomy with Rhinoplasty

www.craniofacialinstitute.org

LeFort I + Bilateral Saggital Split Osteotomy

www.craniofacialinstitute.org

PLANNING SURGERY

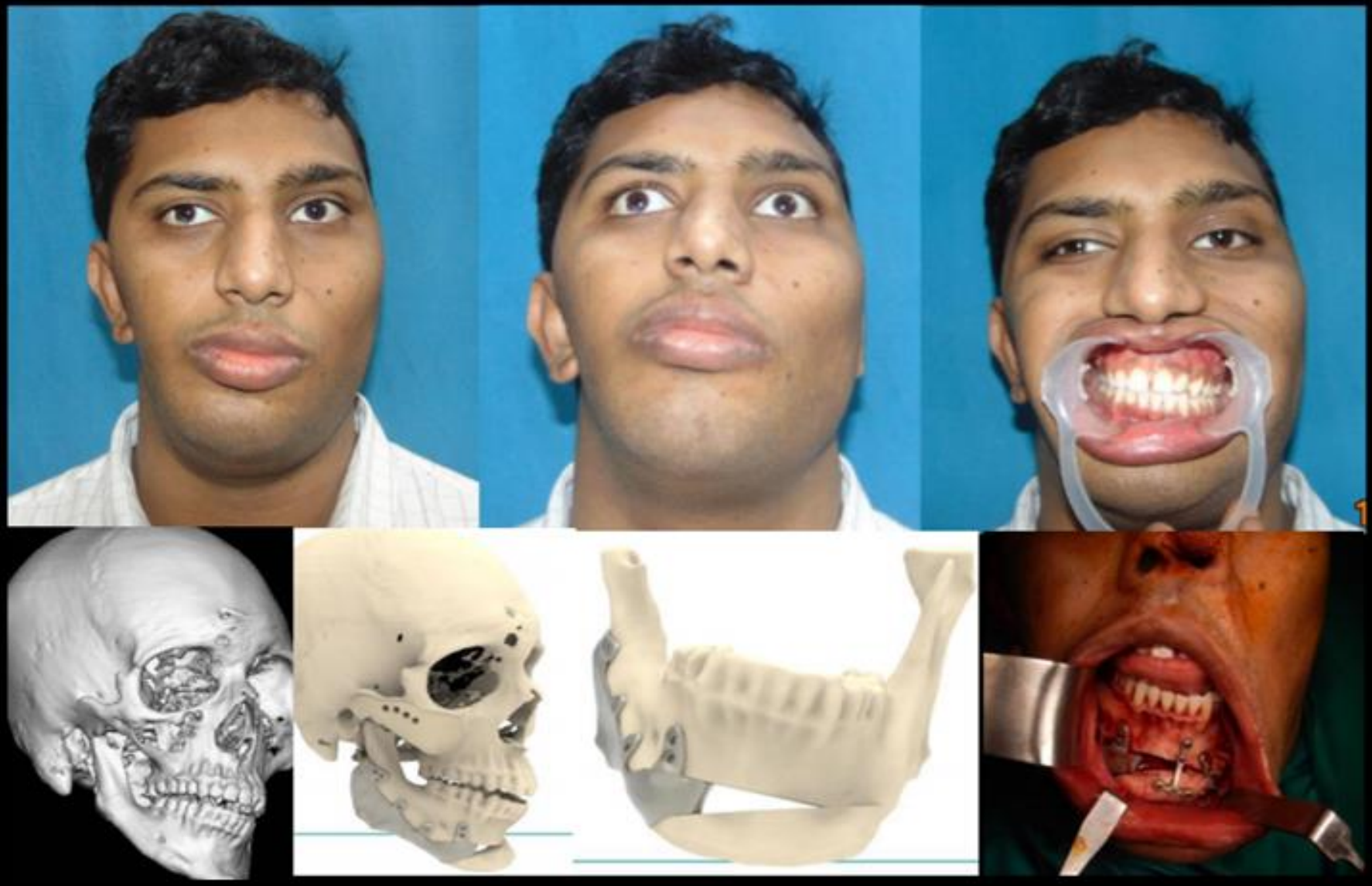

Facial Asymmetry Correction


26 03 2021
26 03 2021

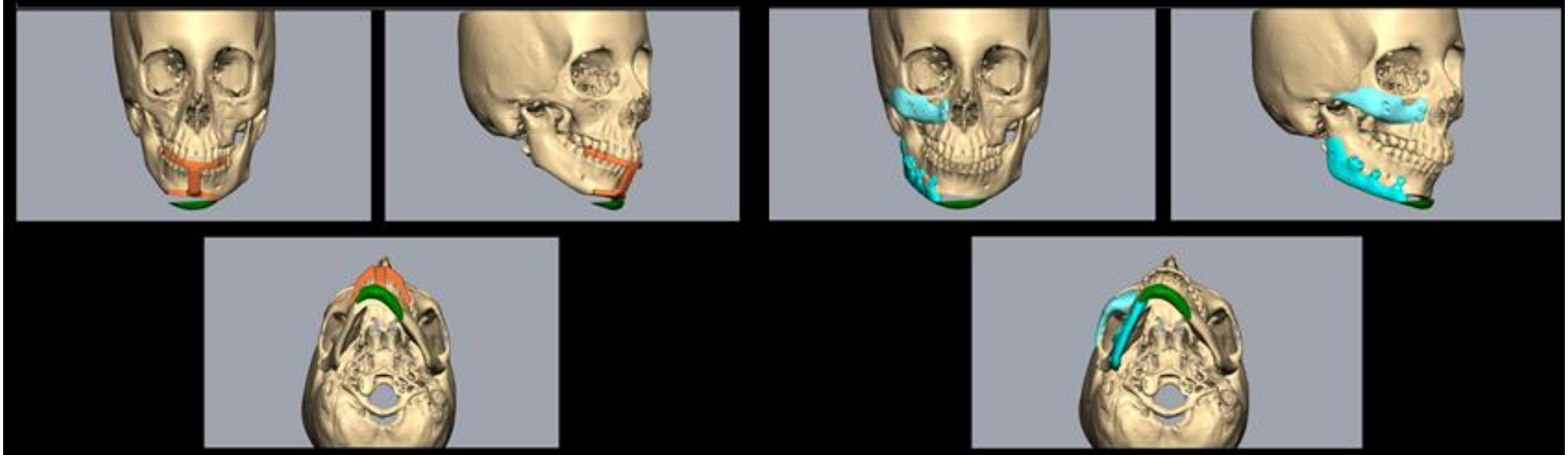

Bring the Smile Back

Thank You

www.craniofacialinstitute.org