

RHINOPLASTY

Prof. Dr. Dr. Srinivas Gosla Reddy

MBBS, MDS, FRCS (Edin.), FDSRCS (Edin), FDSRCS (Eng.), PhD

Dr. Rajgopal R. Reddy

MBBS, BDS, FDSRCPS (Glasg.), PhD

Dr. Ashish Fanan M.D.S.

Dr. Avni Pandey M.D.S.

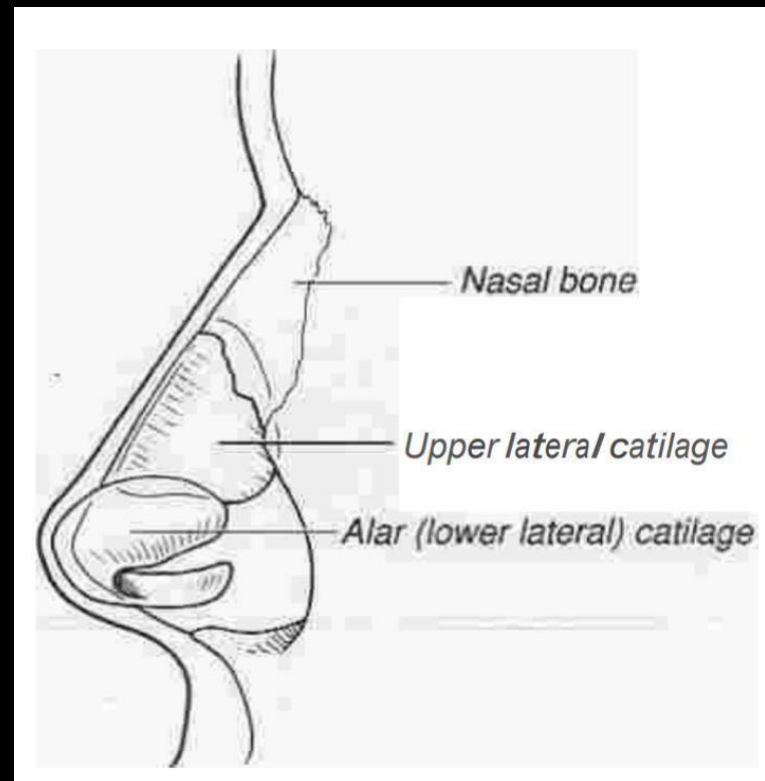
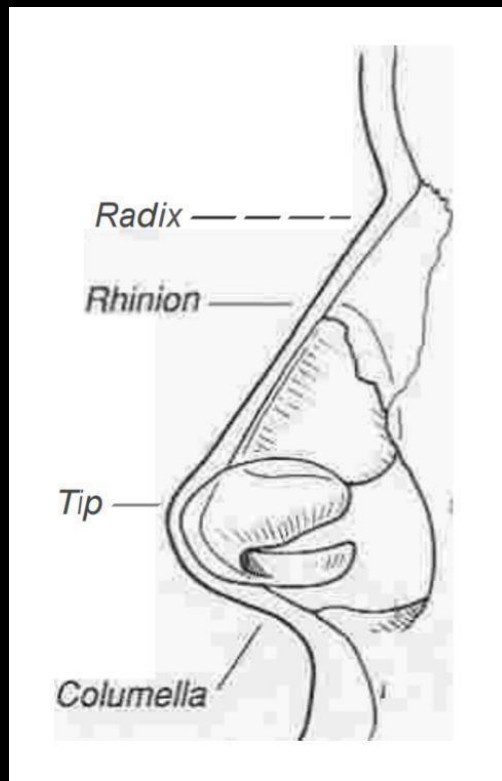
GSR Institute of Craniofacial Surgery,
Hyderabad India



ANATOMY

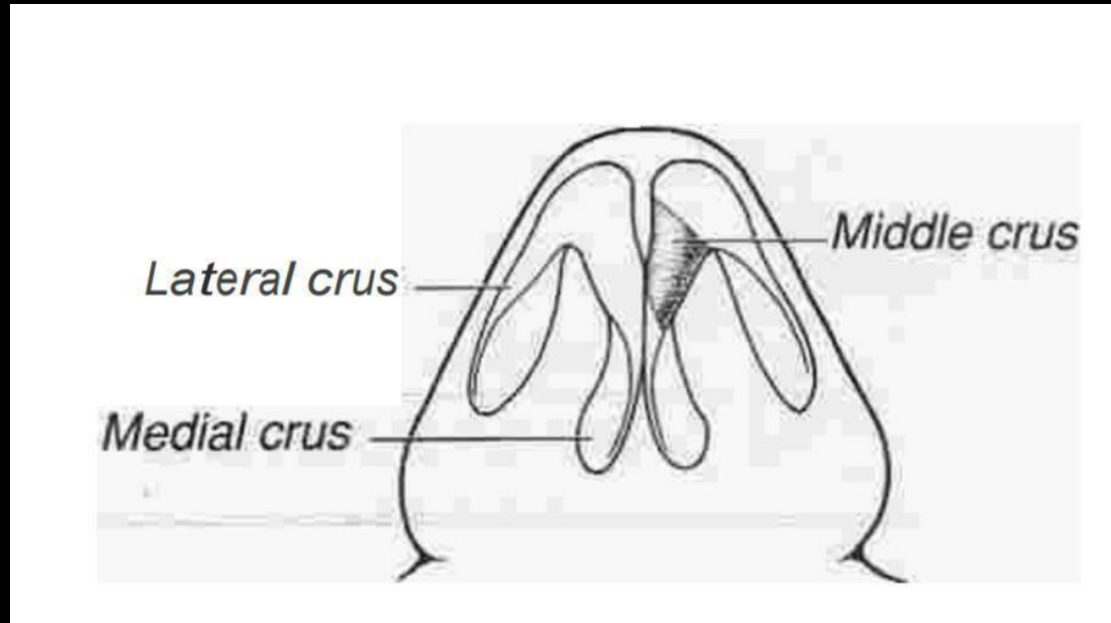


www.craniofacialinstitute.org



- **Rhinion** – Junction of bony and cartilaginous dorsum

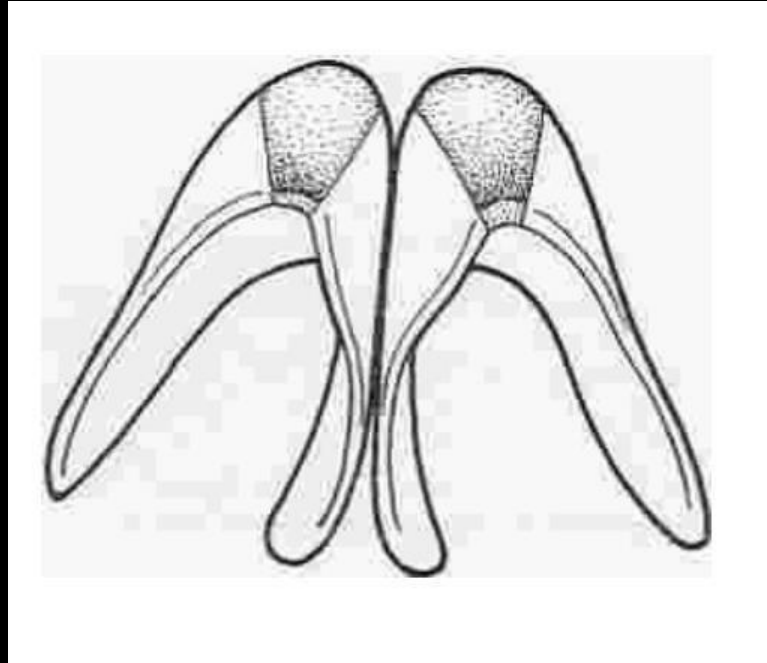




Lower lateral cartilages (**Alar Cartilage**):

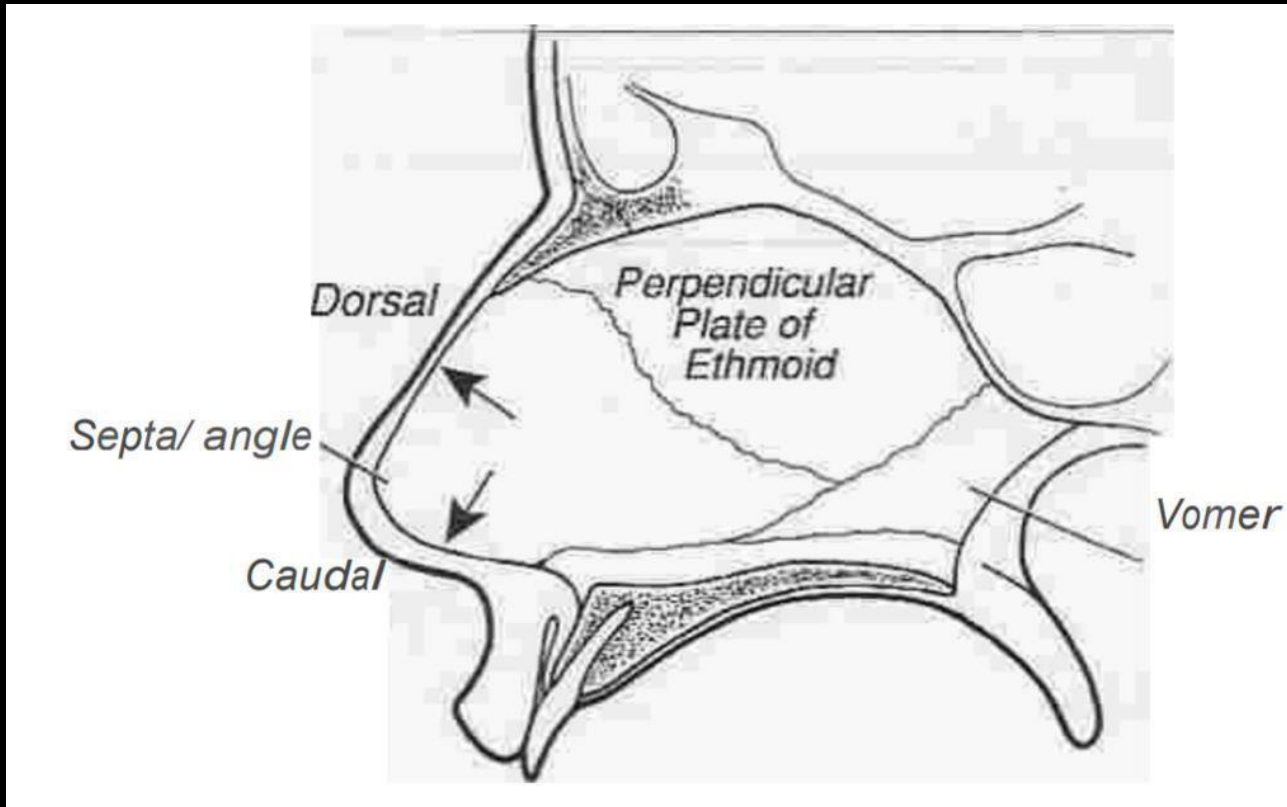
- **Lateral Crura**
- **Medial Crura**
- **Middle Crus** – Transition between Lateral and medial crura





- The **Dome – Junction** between **Medial** and **Lateral Crura**
 - **Most angulated** part of the cartilage



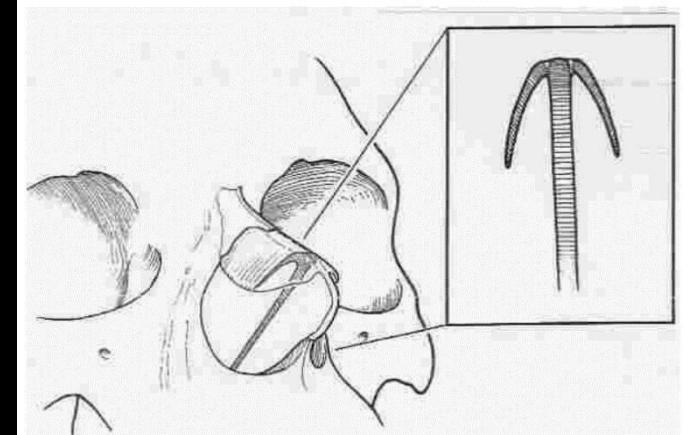


Septal Anatomy

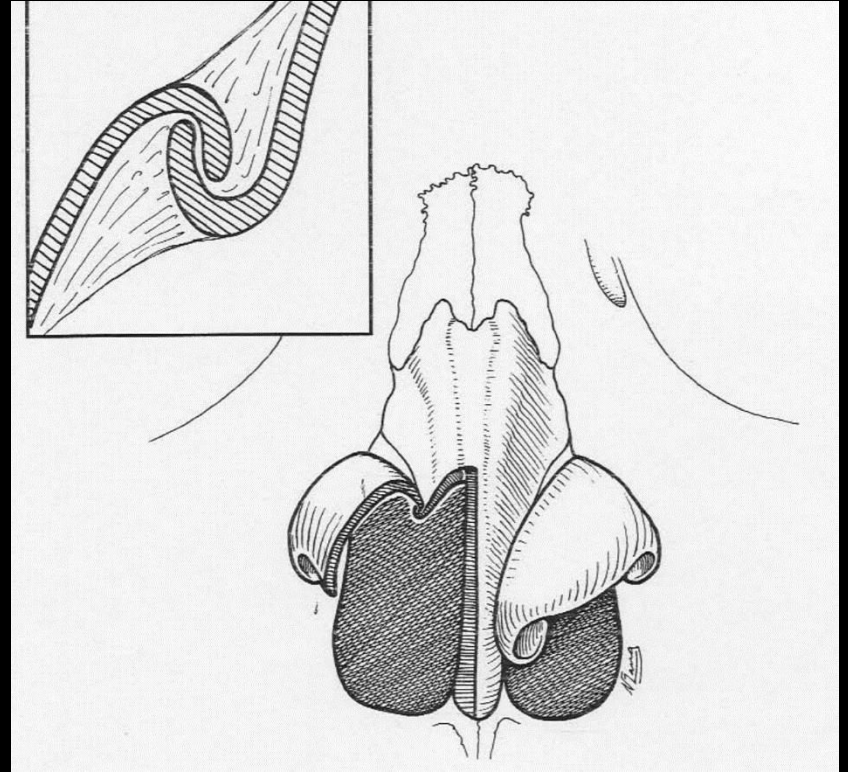


SURGICAL IMPLICATIONS

- At **Rhinion** – Upper Lateral cartilage joins the septum
 - The **joint at septal angle** (angle between caudal and dorsal septum) **is fibrous**.
 - Dividing the attachment, allows for straightening of nose
-
- **NASAL VALVE** : angle between septum and lower border of upper lateral cartilage
 - Even **minimal constriction** causes **substantial restriction** of air flow



- **Scroll** – Continuous roll of cartilage – junction of **alar** and **upper lateral** cartilage
- **Trimming the scroll** reduces bulbousness of the tip



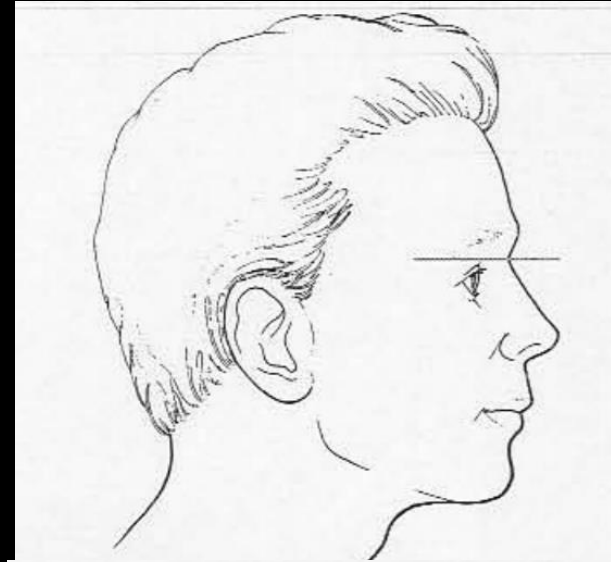
Analysis



A systematic analysis includes evaluation of the **Profile, frontal and basal view**

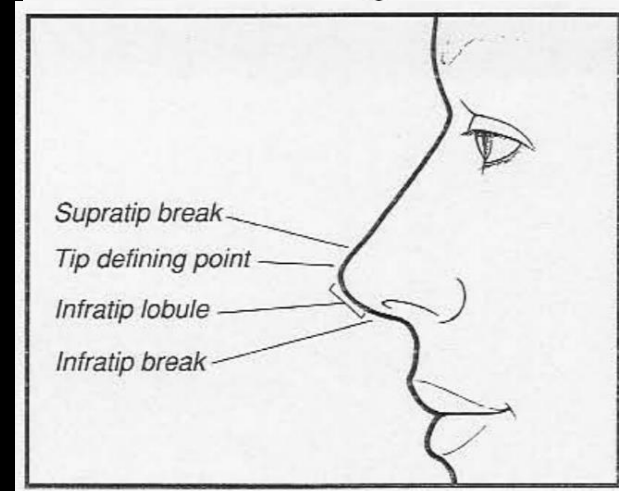
PROFILE VIEW

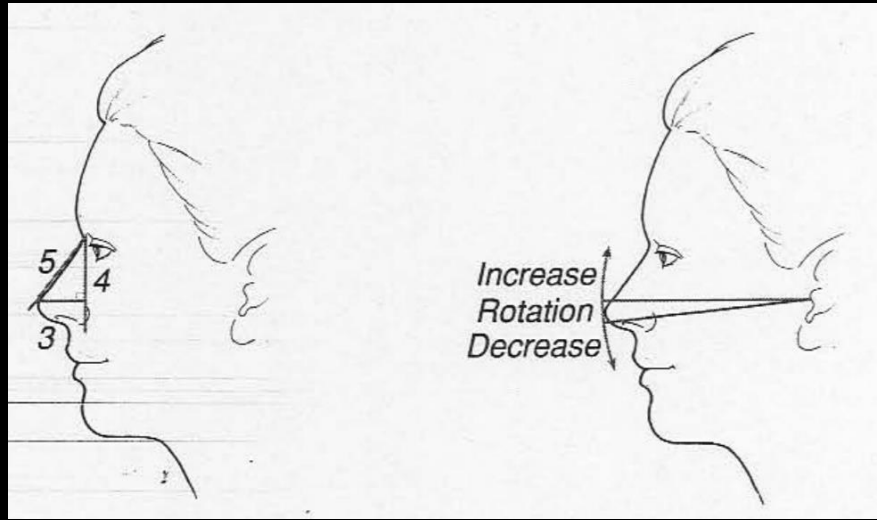
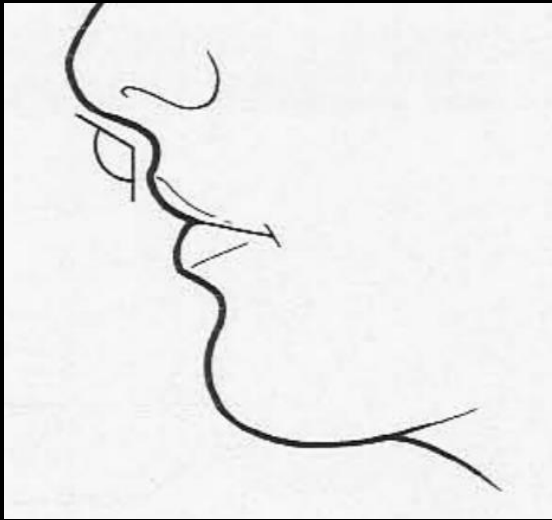
The nasofrontal angle should be at about the level of supratarsal crease



Generally the tip leads the dorsum by 1 – 2 mm.

- A **double break** characterizes a **refined tip**
- First break – junction of dorsum and tip
- Second break – junction of infra tip lobule and columella





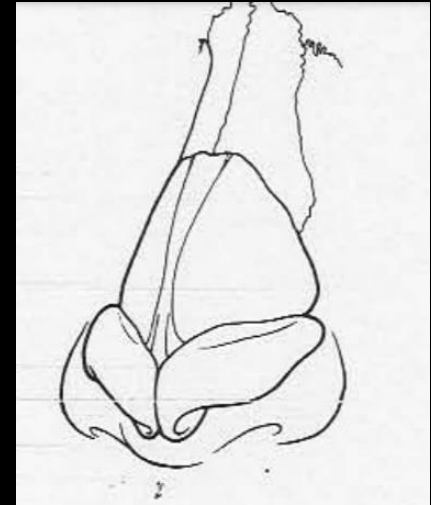
The **nasolabial angle** should be **90 – 105 in males** and **95 to 110 in females**

- Too wide angle – tip appears overrated

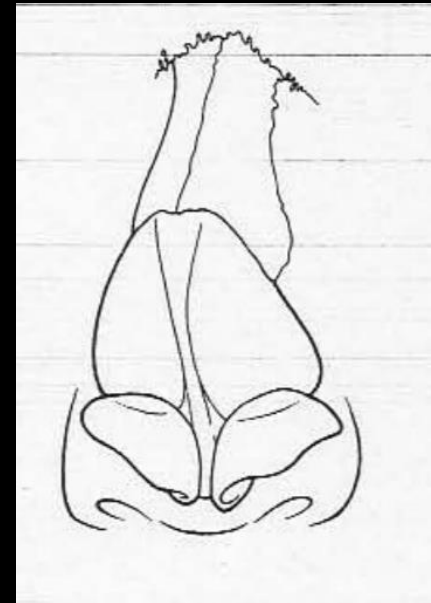


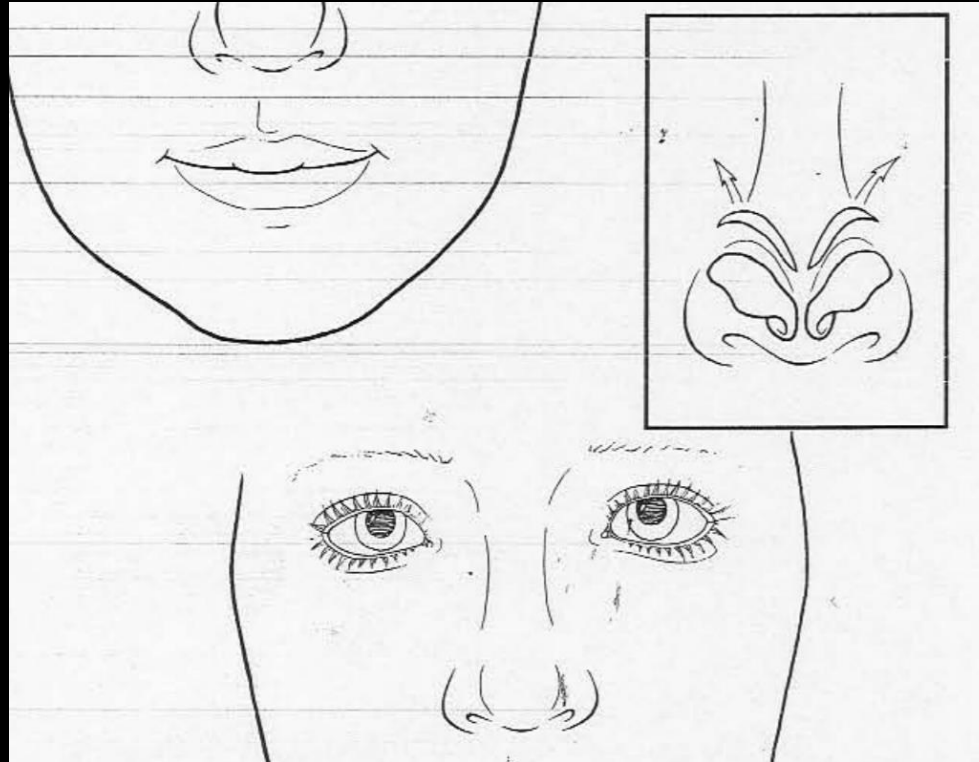
Frontal view

Deviated nose – nasal bones and upper lateral cartilages point in same direction



Twisted nose - nasal bones deviate in one direction while upper lateral cartilage return to midline



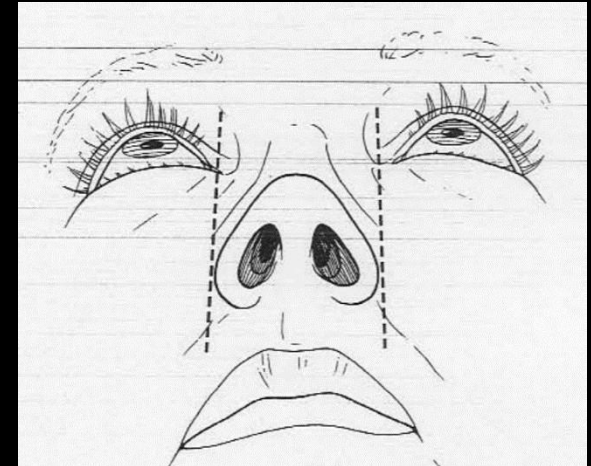
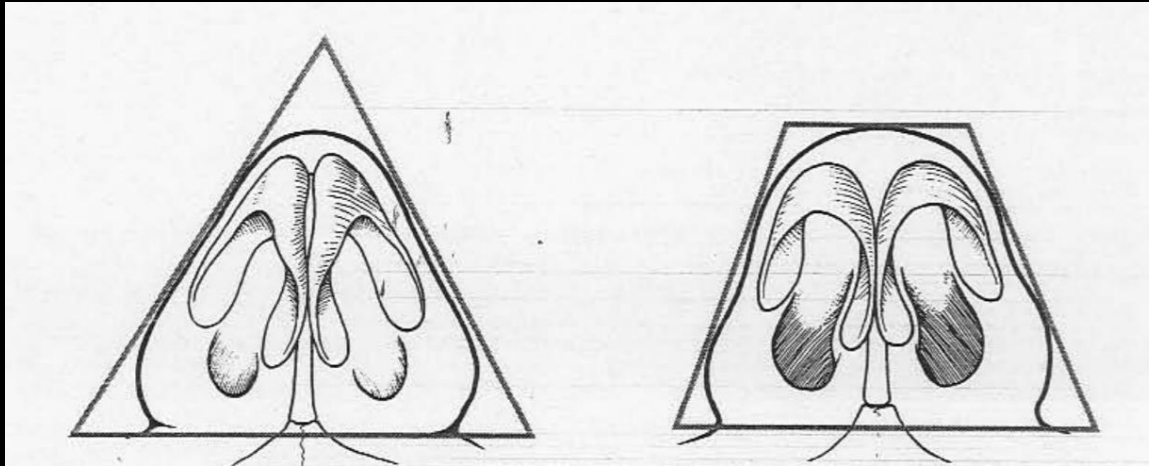


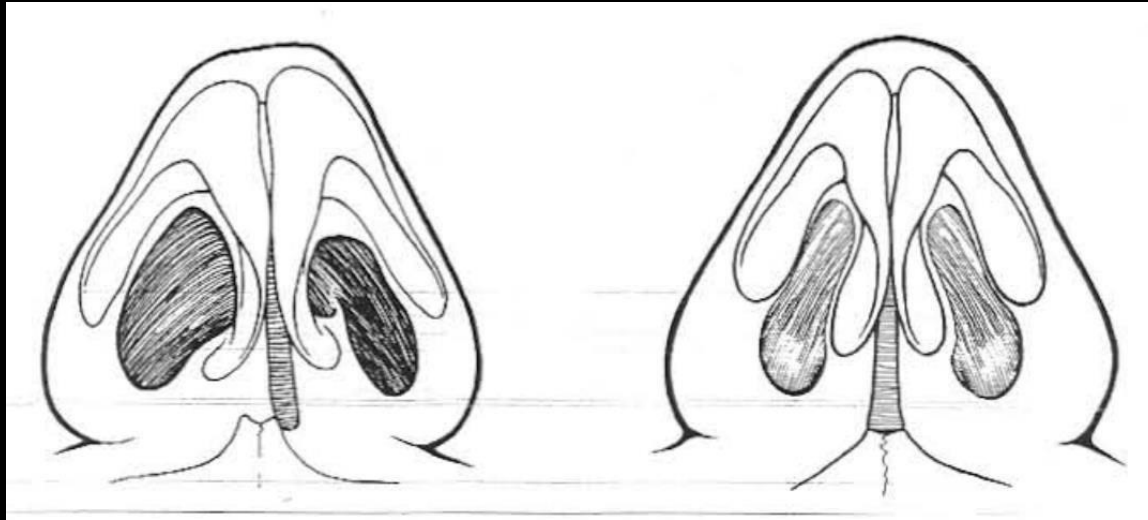
If the volume of the **lateral crura is too large** the **tip appears bulbous** – surgical correction is indicated



BASE

- When viewed from the base of the nose, **the tip** should **appear triangular**.
- If the **alar cartilages are bulbous** or the **domes are wide** the tip looks **trapezoidal**
- The **alar base width** should be **within 1 – 2 mm of inter canthal distance**






Dislocation of caudal septum off the premaxillary spine is often the cause of asymmetrical nostrils



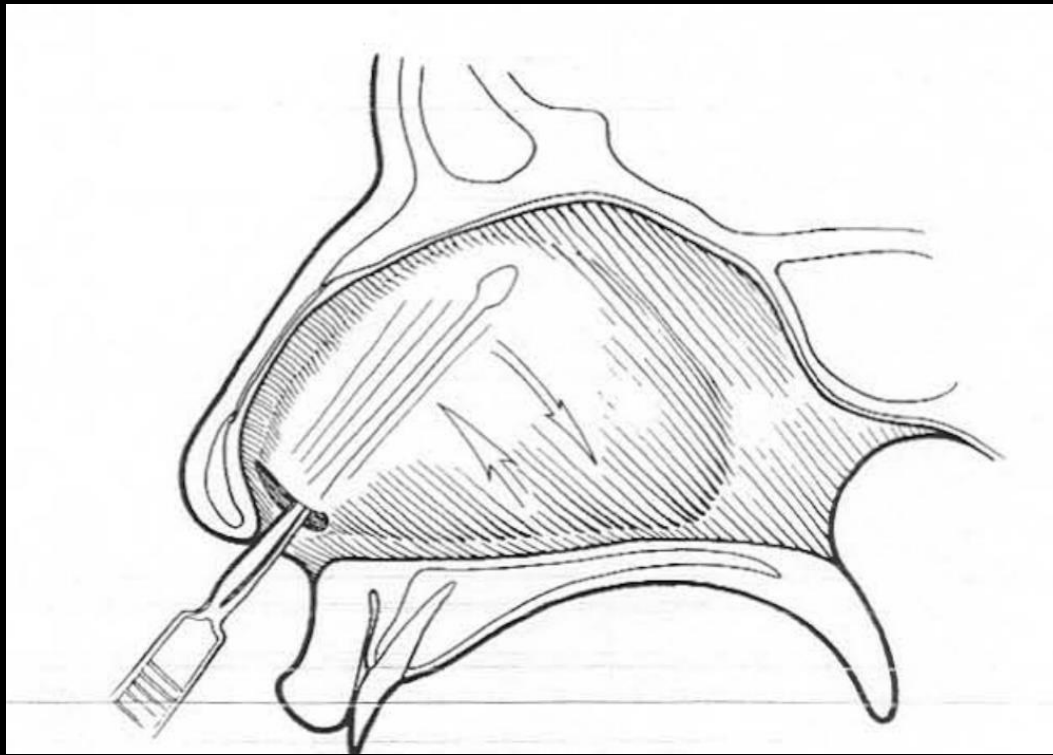
ENDONASAL RHINOPLASTY





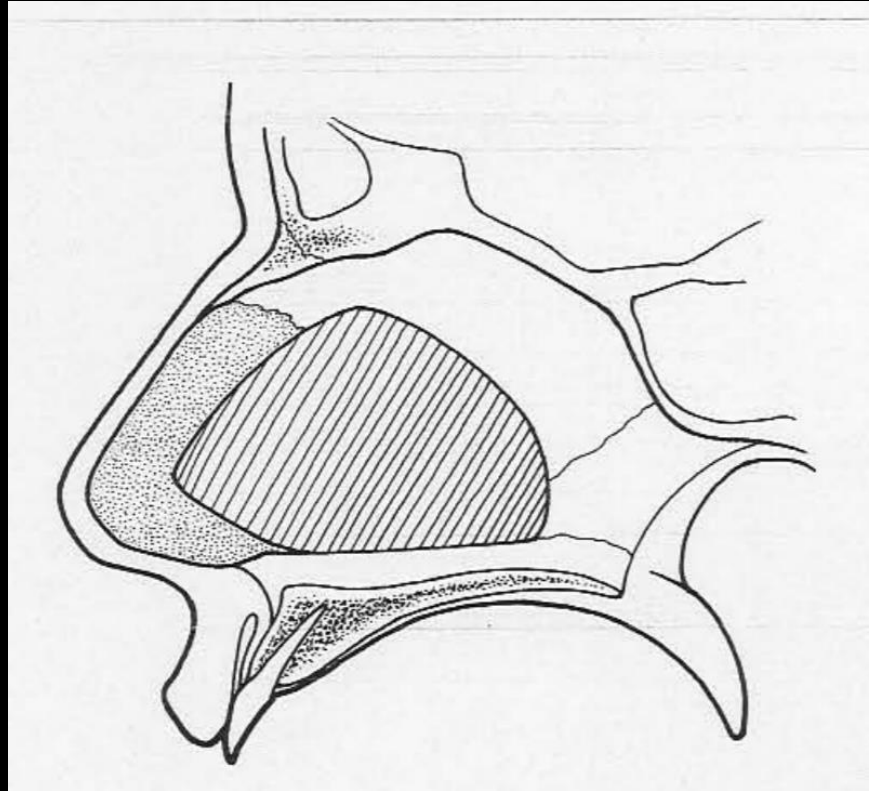
- **HEMITRANSFIXION INCISION** is made to **access the septum**
- Made **on one side** of caudal septum
- If caudal **septum is dislocated** from spine - **full transfixion incision** through **mucosa of both side** is made





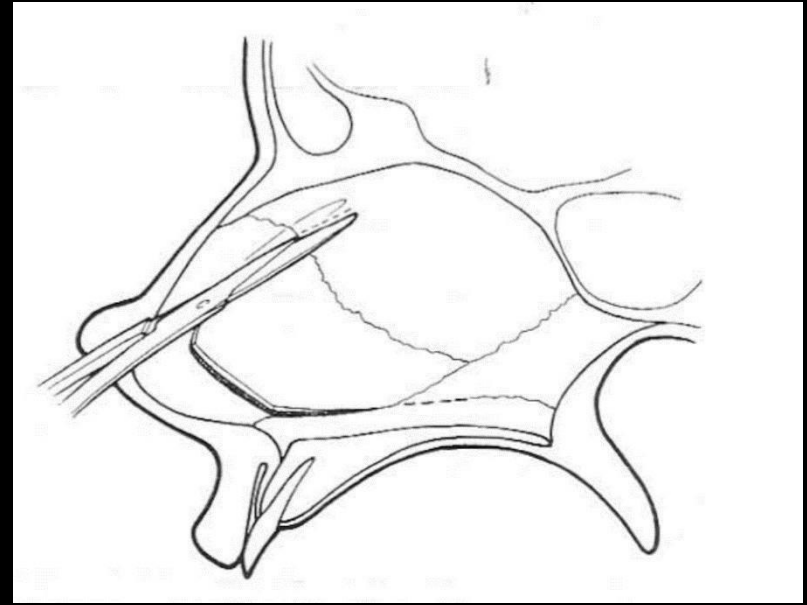
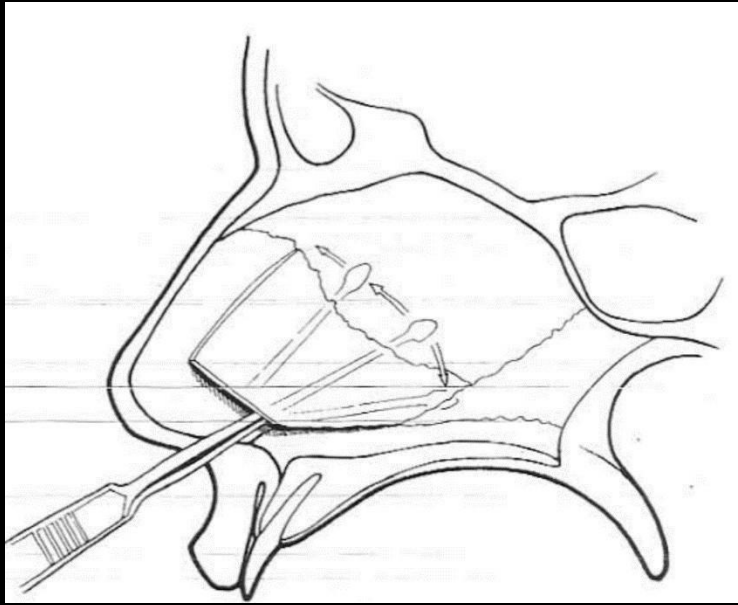
Mucoperiosteum and **mucoperichondrium** – lifted off the entire concave side of the septum for optimal visualization





- The cartilage to be resected is outlined
- A **6 mm dorsal strut** and **1 cm caudal strut** are preserved to support the external nose.

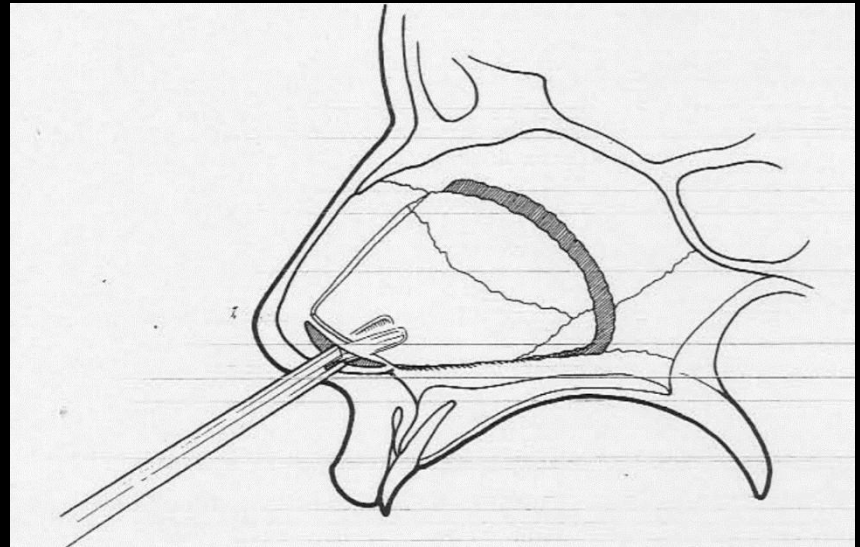




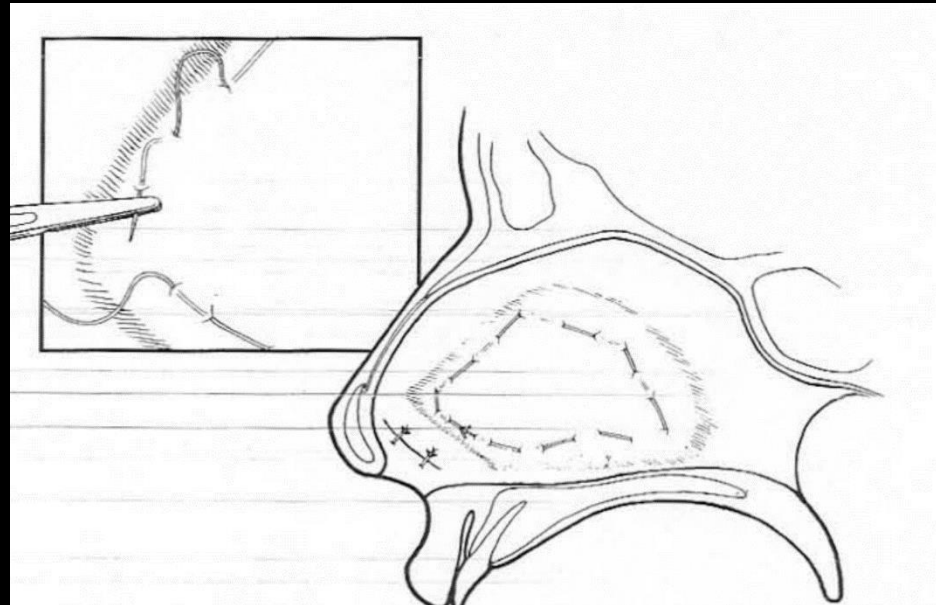
- **Contralateral mucoperiosteum** is dissected extending on to the **vomer and perpendicular plate of ethmoid**
- The perpendicular plate superiorly and vomer inferiorly are cut.



- The harvested septal cartilage-bone complex is removed while preserving the thick cartilage at the bone junction for tip grafting



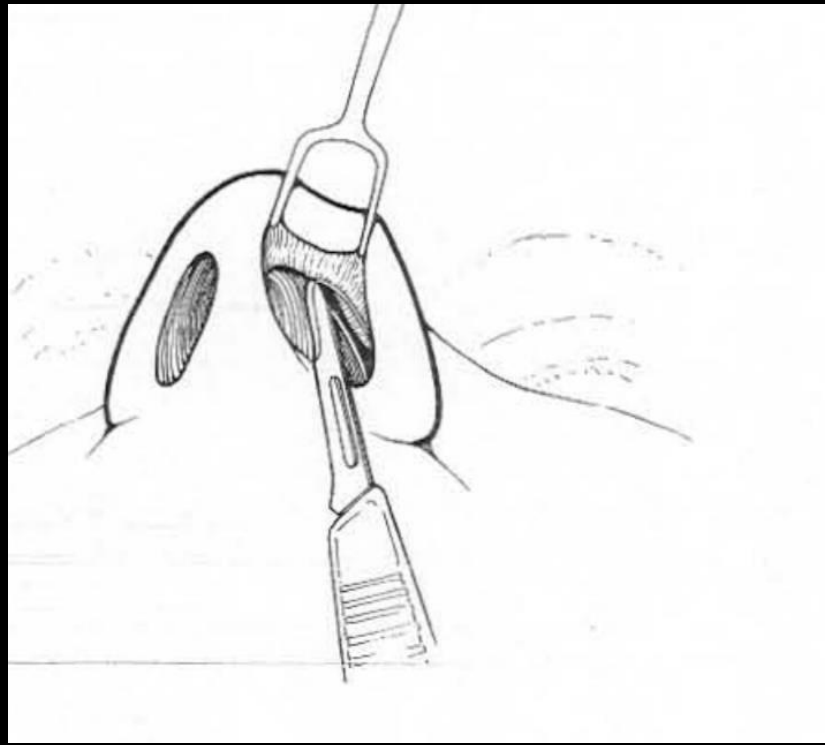
- The **hemitransfixion** incision is closed using **quilting stitches**.



THE RHINOPLASTY THEN STARTS WITH DEGLOVING OF THE NOSE

- Bilateral intercartilaginous incisions – To access dorsum of nose
- Alar marginal incisions – for nasal tip delivery and access



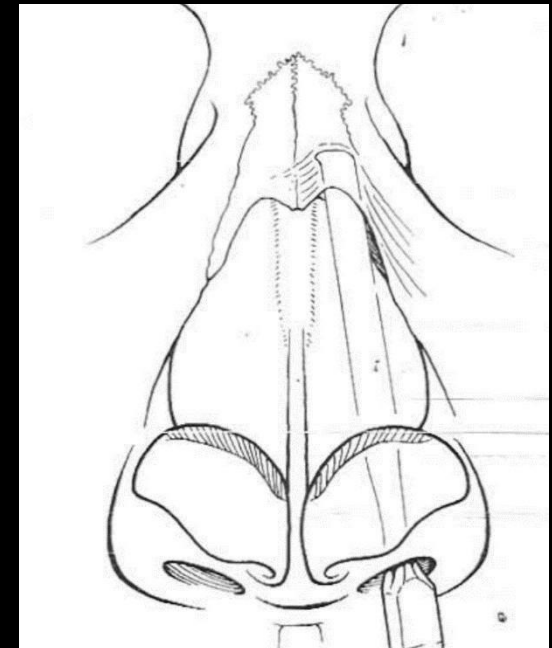
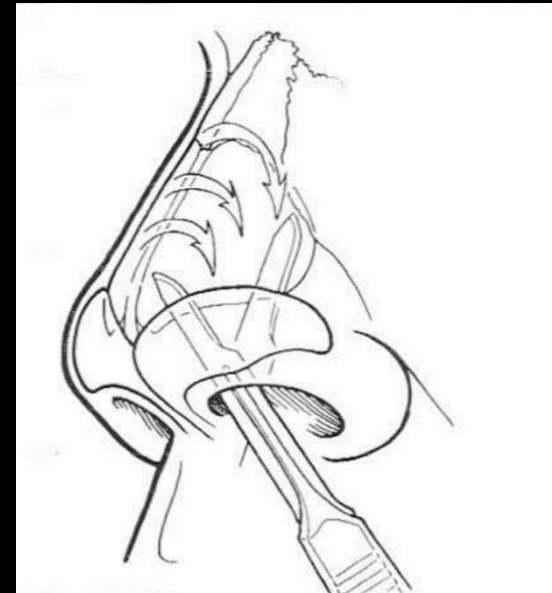


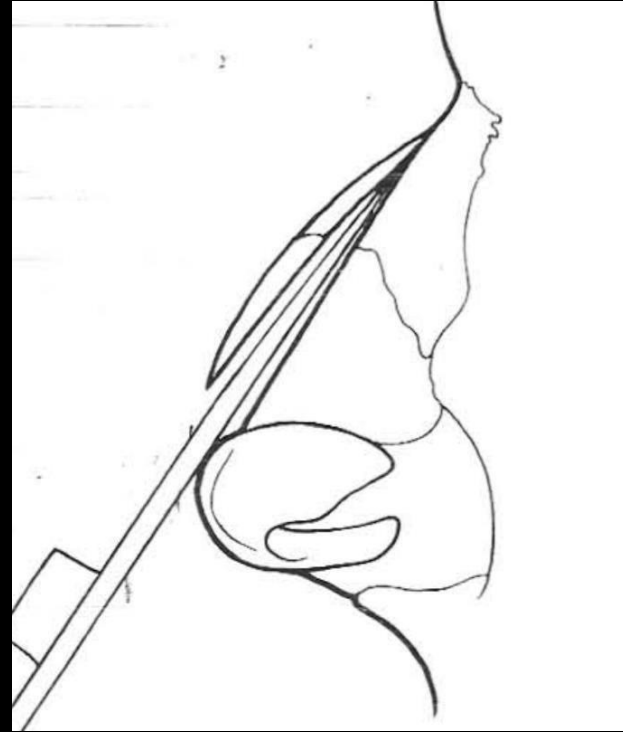
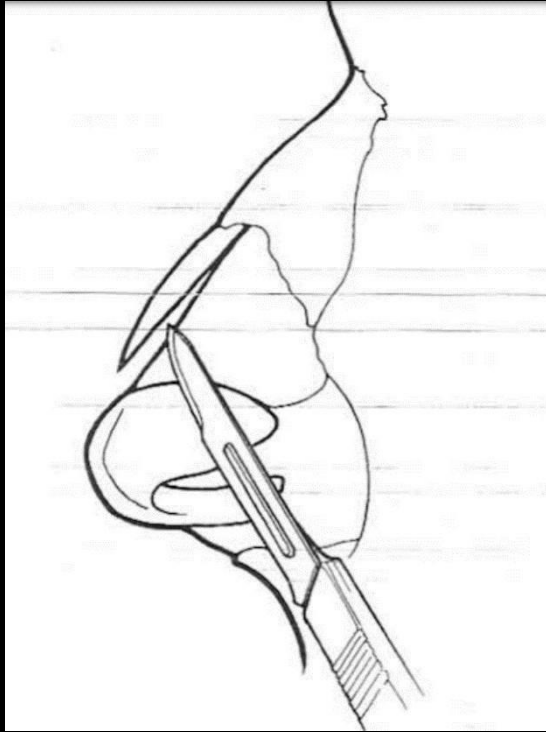
BILATERALINTERCARTILAGINOUS INCISION – to access the dorsum of the nose

- Given 1 mm above caudal margin of upper lateral cartilage extending medially above nasal valve around the septal cartilage.
- This incision meets the hemi or full transfixion incisions made previously



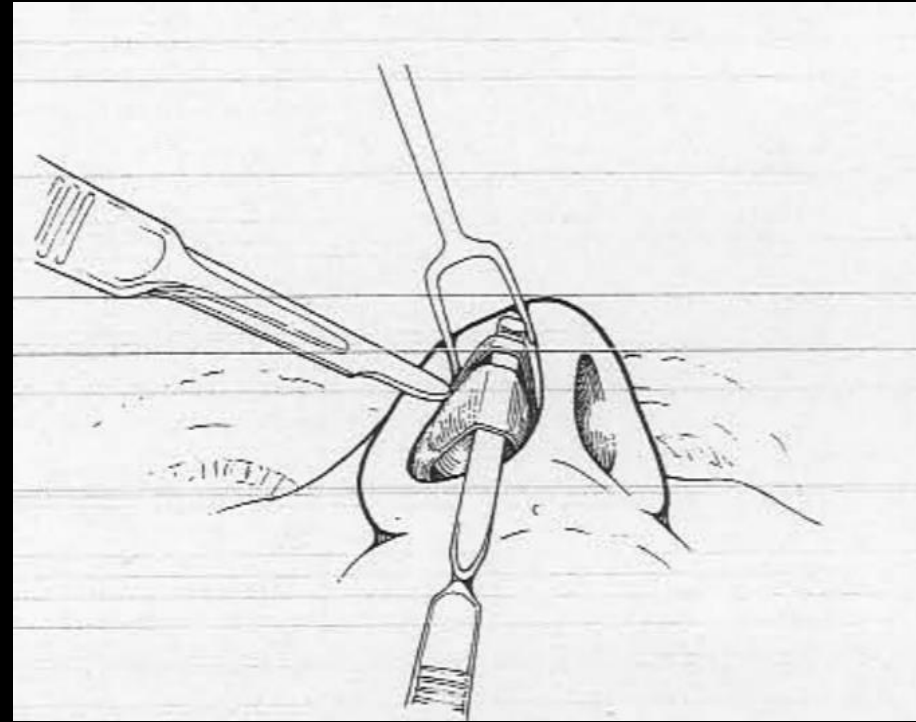
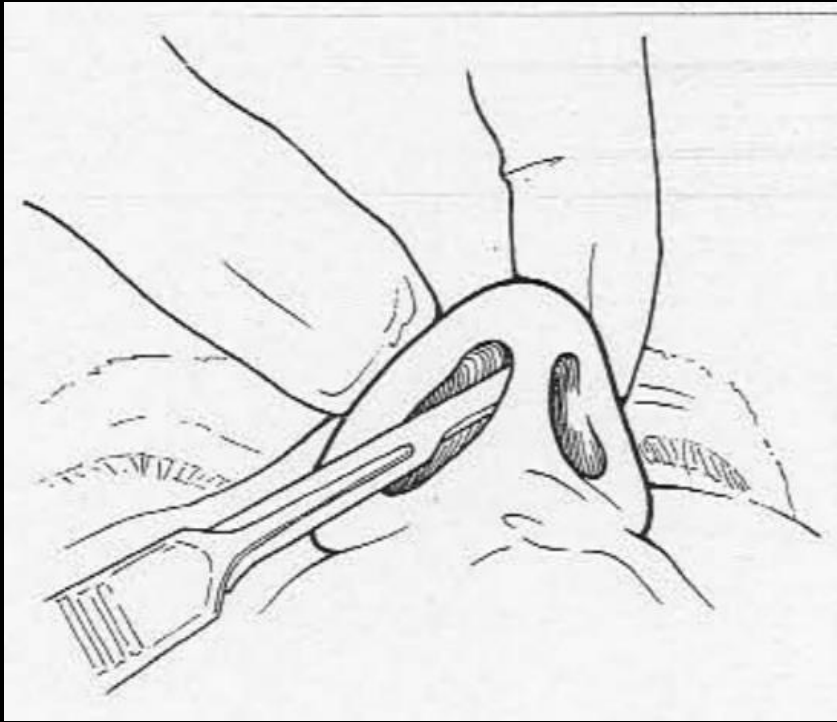
- Elevation of soft tissue over cartilaginous dorsum and upper lateral cartilage is done
- The periosteum just above the caudal margins of nasal bone is elevated to allow introduction of instruments for dorsal reduction





Surgeon may remove the hump at this stage or proceed to work on tip





ALAR MARGINAL INCISION – for endonasal tip delivery and access

- Made bilaterally at **lower margins of alar cartilages**, elevating the soft tissue in **supraperichondrial plane**
- The **plane is connected** with **intercartilaginous incision** allowing tip delivery which is modified as necessary



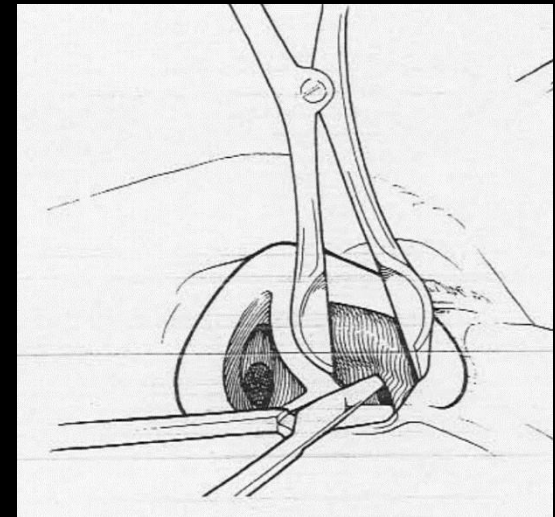
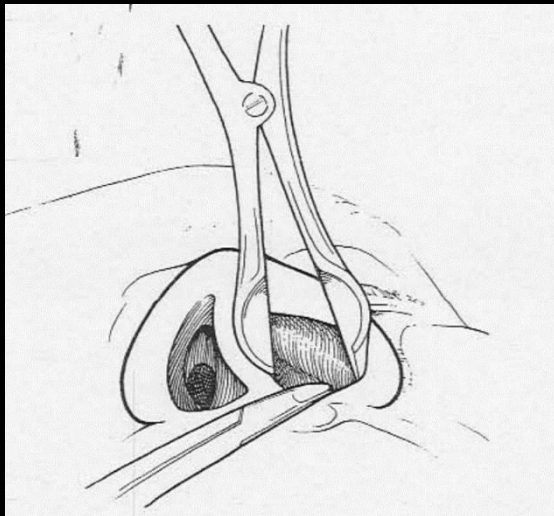
- Osteotomies are then performed
 - Medial osteotomy
 - Lateral osteotomy
- Osteotomies are used for 3 reasons
 - To close and open roof created by removing a hump
 - To straighten a crooked nose
 - To flatten convex nasal bones

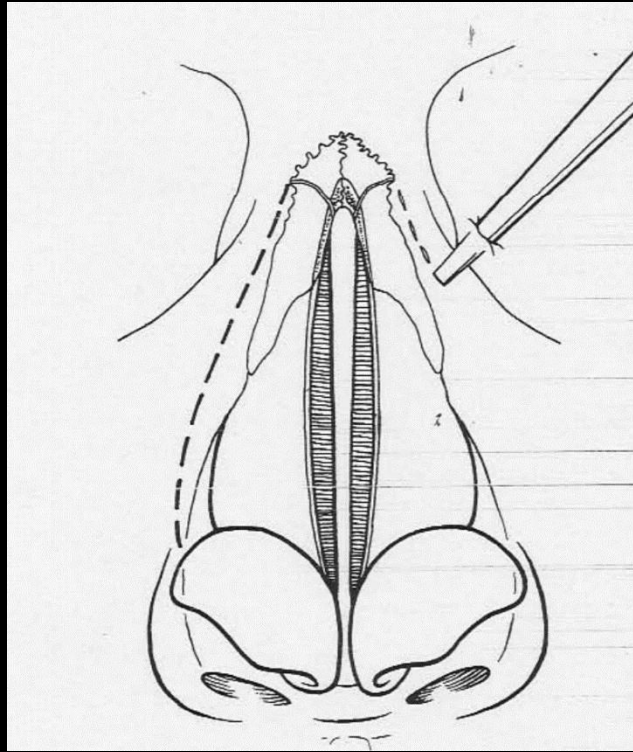


Medial osteotomy

- is made parallel to midline – when the nose is crooked
- May fade laterally – when nose is straight

For **lateral osteotomies**, vestibular skin is punctured and osteotomes are inserted.





An osteotome can also be employed **percutaneously** for lateral osteotomy

After multiple perforations have been created in the bone, digital pressure is applied to fracture it.



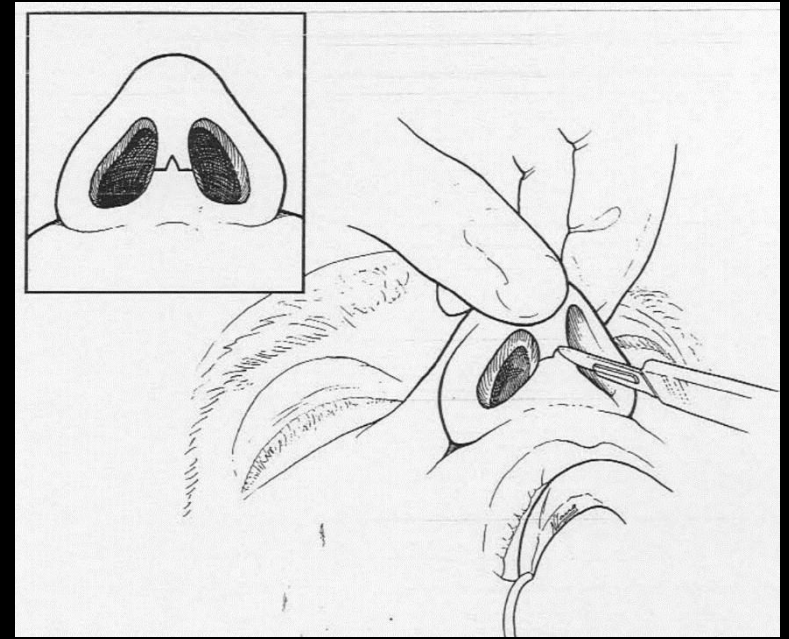
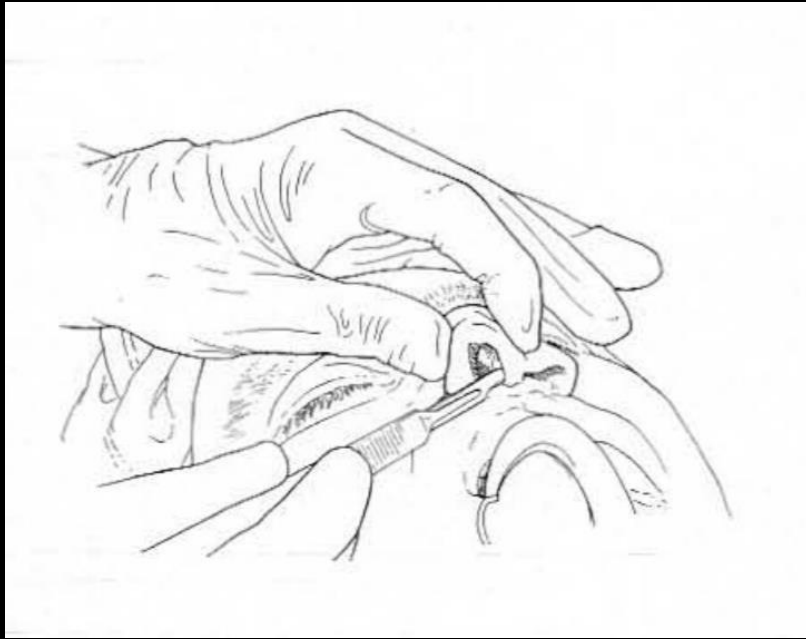
Surgical considerations

- Lateral osteotomy acts as a hinge, allowing upper lateral cartilages and nasal bones to come together in midline.
- The only area that's actually narrowed by osteotomes is the dorsum
- Eventual bone remodelling at the pyriform aperture will nullify any immediate narrowing of the base of the nose
- Precise re-approximation and suturing of mucosa at the valve area prevents scarring and air entry restriction.



External Approach






An external rhinoplasty begins with **bilateral incisions** just anterior to the **medial crura** extending from the dome to the mid-columellar region

An **inverted v incision** across the **columella** connects incisions on the side



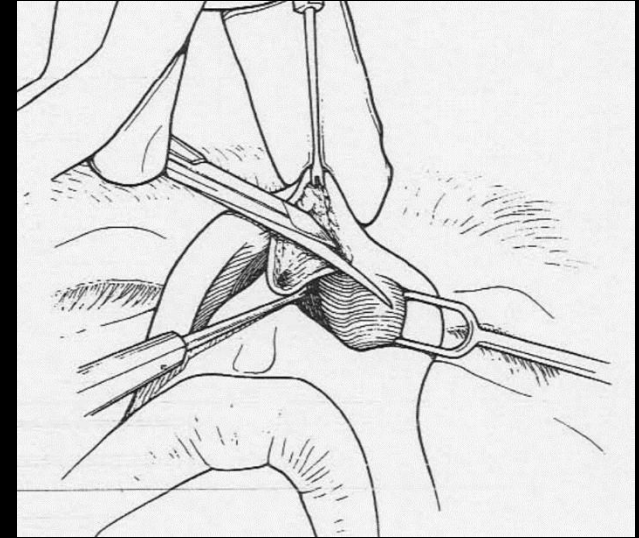


Small sharp scissors are then advanced across the columella and opened to spread the transcolumellar incision, dividing any soft tissue attachments.

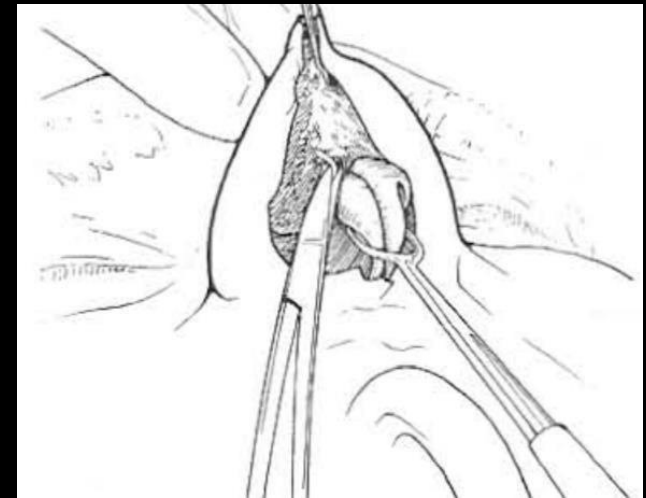
A double hook is used to retract the columellar flap thus raised.

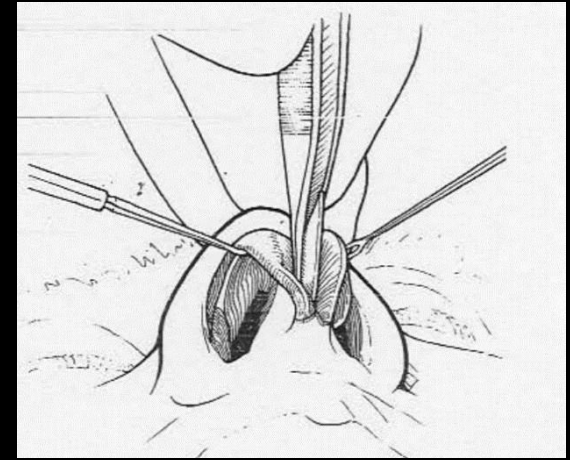
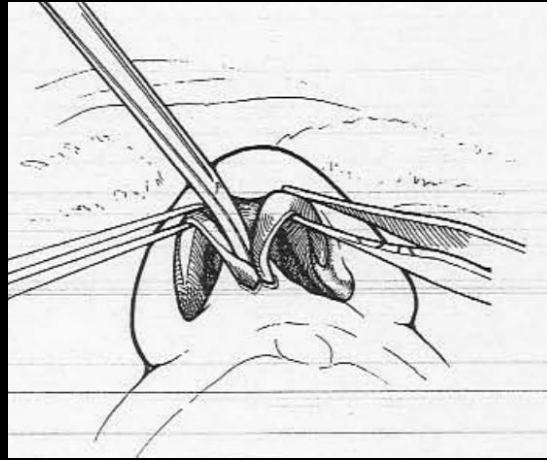
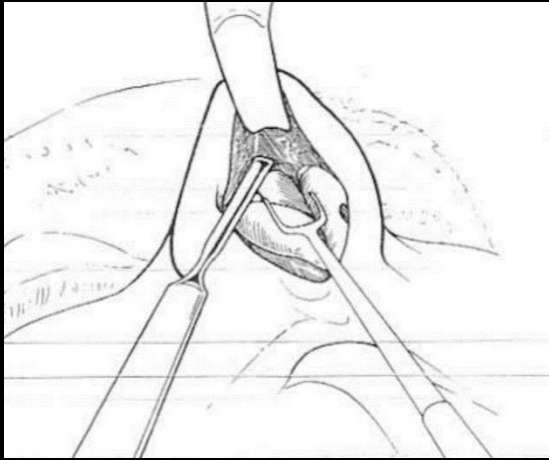


- Small scissors are inserted with **one blade** along the **vestibule over the lower rim of alar cartilage** and the **other** in the **pocket over the lateral crura**, the **marginal incision** is then completed.



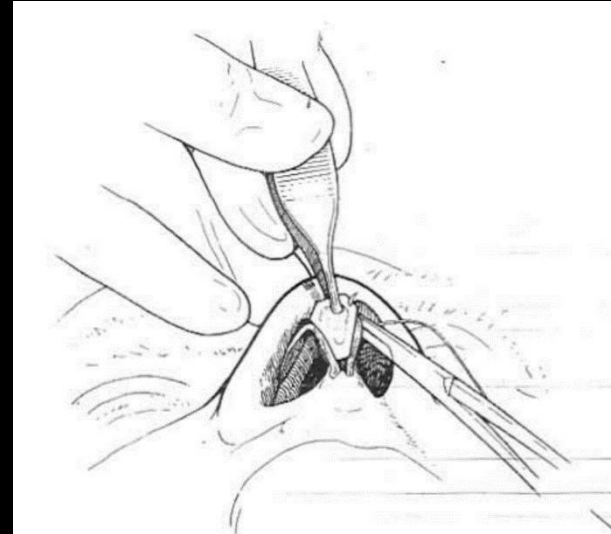
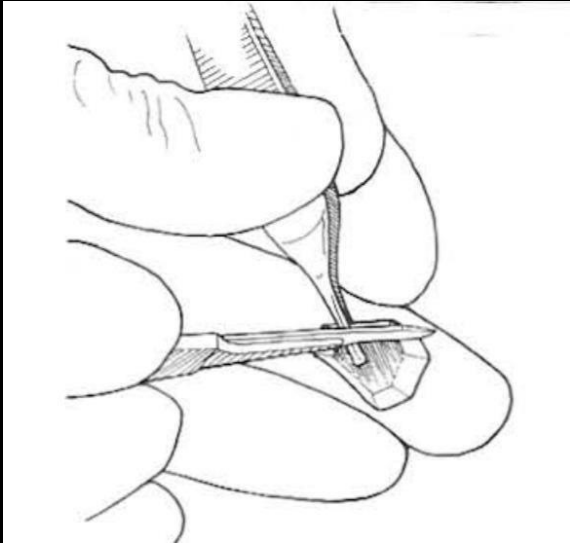
- The domes are retracted inferiorly.
- **Dissection is extended to the septal angle** along the dorsum **up to to the caudal end of nasal bones**.





- Periosteum is lifted off the nasal bones
- Small scissors are used to create a **pocket between the medial crura** for **placement of a strut** if required
- The strut is secured with sutures, usually 2 to 3 stitches suffice.





- If **shield graft** is to be placed, it is **bevelled to prevent sharp edges**
- The graft is secured using PDS or nylon sutures
- **Sutures nearest to the domes are placed** before those closest to transcolumellar incision, **to promote optimal positioning.**



- The **trancolumellar incision** is closed with a **deeply placed fine sutures** and **fine skin sutures**.
- **Absorbable sutures** are used to close the incision **along the alar margins**
- The nose is taped and splinted



Surgical considerations

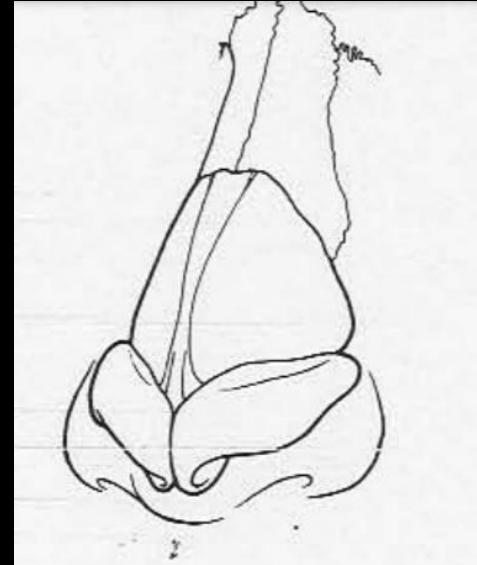
- The external approach provides a panoramic view of septum thus making the septoplasty easier in patients with high septal deflection or in revision cases.
- Dividing the attachments upper lateral cartilages to the septum helps in proper elevation of muco-perichondrium flap and exposure of septum
- While placing the strut, the soft tissue in front of nasal spine is preserved to prevent lateral strut displacement.
- Replacement of skin over strut and shield complex may produce a slight upward rotation of tip and eventual flaring of the lateral crura. This can be prevented by dividing the dome and excising a small segment of lateral crus.




Crooked Nose

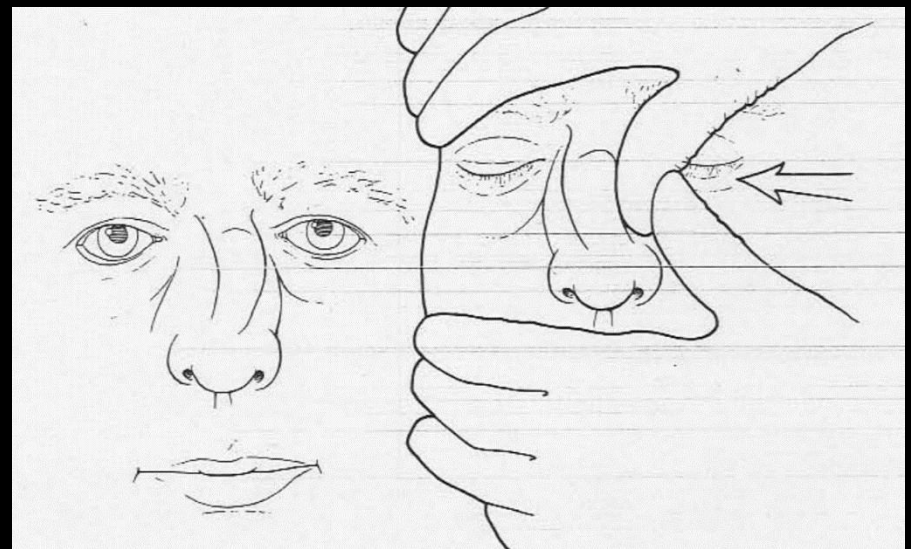
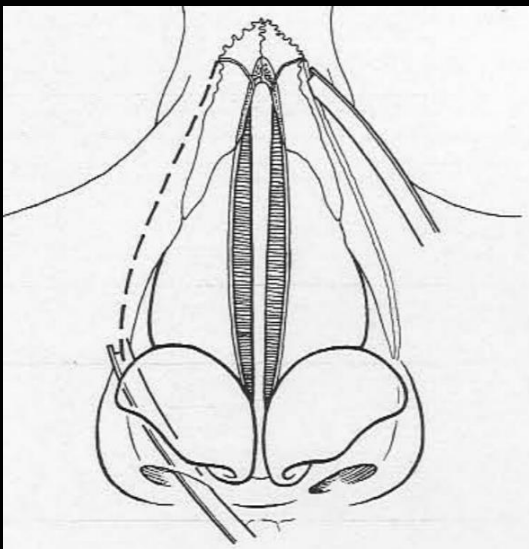


- A **deviated nose** is one in which the nasal bones and upper lateral cartilage point away from the midline



- A **twisted nose** is one in which the nasal point in one direction but the upper lateral cartilages return to the midline.





- If **septum is crooked**, **septoplasty** is performed followed by disarticulation of upper lateral cartilage from septum
- **Next**, both **medial and lateral osteotomies** are performed.
- If, perpendicular plate of ethmoid is also crooked, it should be digitally fractured.
- If the **nose is still crooked** after central complex fracture, **camouflaging crushed cartilage grafts** should be placed **along the side walls** of the nose.



The patients should never be guaranteed an absolutely straight nose.

With the use of good technique, however improvement though not perfection is achieved in almost all cases



Saddle Nose

- Most saddle nose repairs include **augmentation of the nasal dorsum with autogenous septal grafts**
- **Auricular grafts** are **the most preferred option**, which are well tolerated and don't get resorbed
- Other autogenous options include
 - **Split Calvarial Graft** – stiff and has sharp edges
 - **Rib** – resorbs and wraps sometimes



MANAGEMENT OF THE TIP

- Projection
- Rotation
- Geometric form
- Definition

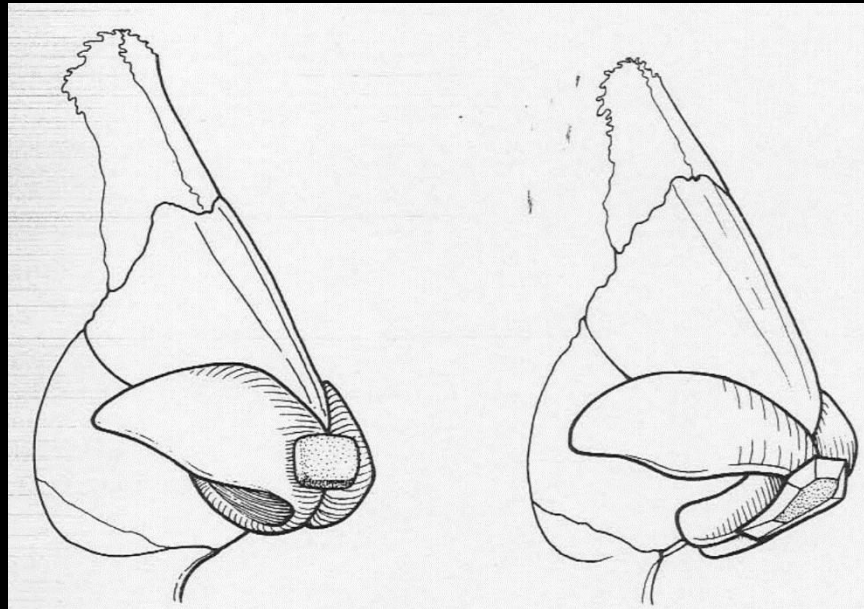


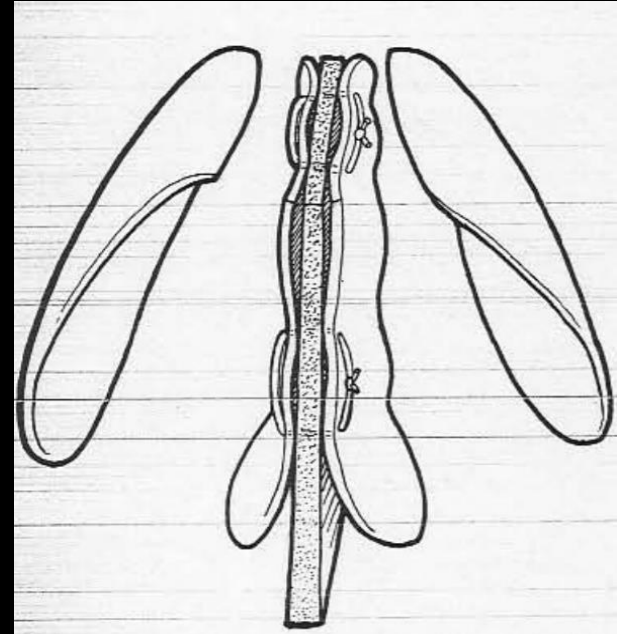
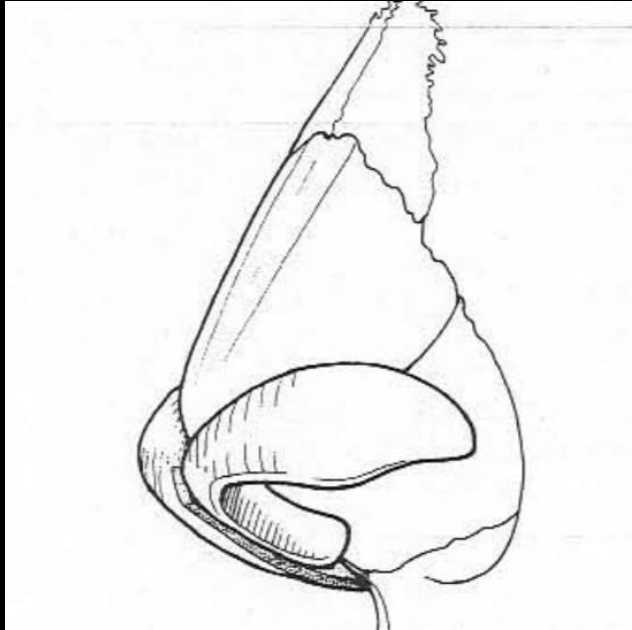
Projection

In general, the tip leads the dorsum by 1 – 2 mm

Increasing the tip projection

If only 1 – 2 mm of additional projection is required, a **supradermal** or **shield graft** can be in a pocket in the tip





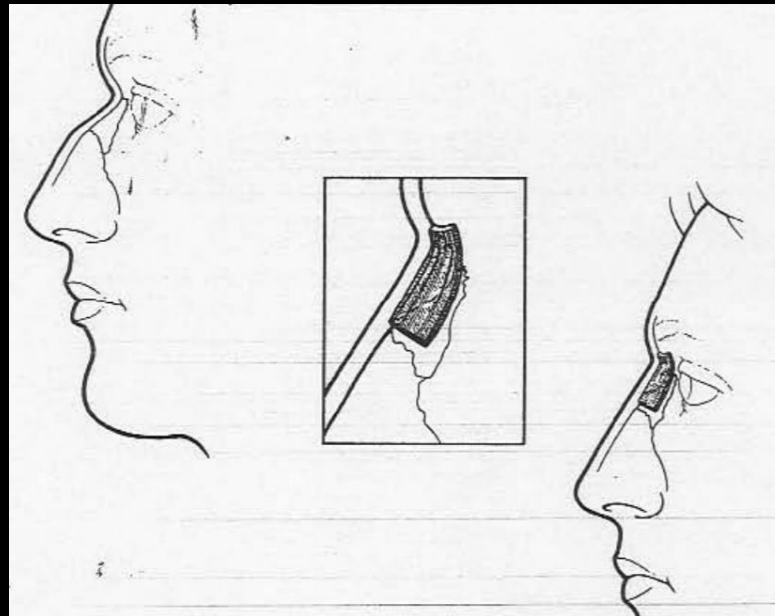
If still more projection is required, a **strut of autogenous septal cartilage** can be sutured between medial crura

Alternatively, **domes can be divided** and intercrural strut is placed and **medial crura** is sewed to the strut.



Decreasing tip projection

- Achieving acceptable result is difficult, since definition may be lost when the skin contracts around the new smaller framework
- It is important to note that a well proportioned large nose is preferred over an ill-proportioned small one
- In most cases, use of a **radix graft** can eliminate the need for tip reduction

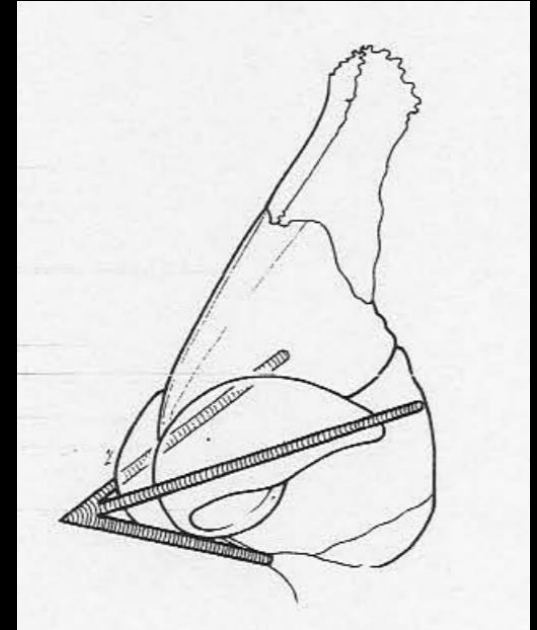


The tripod model

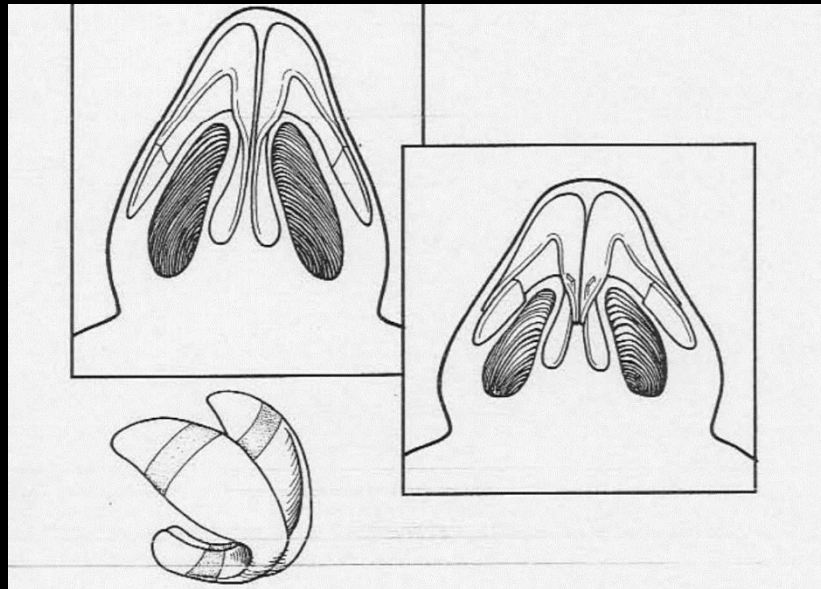
- Each lateral crus represents one leg each of tripod
- The third leg is formed by medial crura and caudal septum

Pushing gently on the tip will reveal the origin of tip support.

- If its springy - tip is primarily supported by crura
- If septal angle is palpable - septum is the primary support



- If **septum** is providing **support**, **septal angle** is lowered.
- If the tip is over projected because of the length of the medial and lateral crura, the crura has to be modified.
 - A segment of **lateral crura** or the **medial crura** can be excised or overlapped and fixed with sutures.



Rotation

Increasing the tip rotation

- Remove the hump if present
- Shorten the caudal septum
- Shorten lateral crura
- Premaxilla augmentation

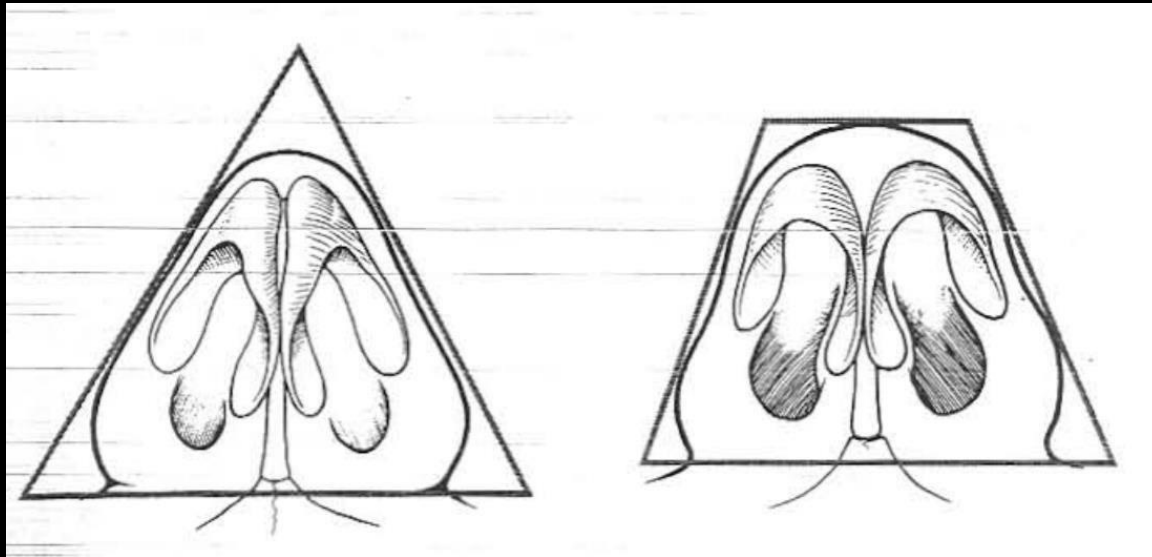
Decreasing the tip rotation

- Trim caudal segment near spine - decreases the nasolabial angle causing derotation
- Augmentation of dorsum

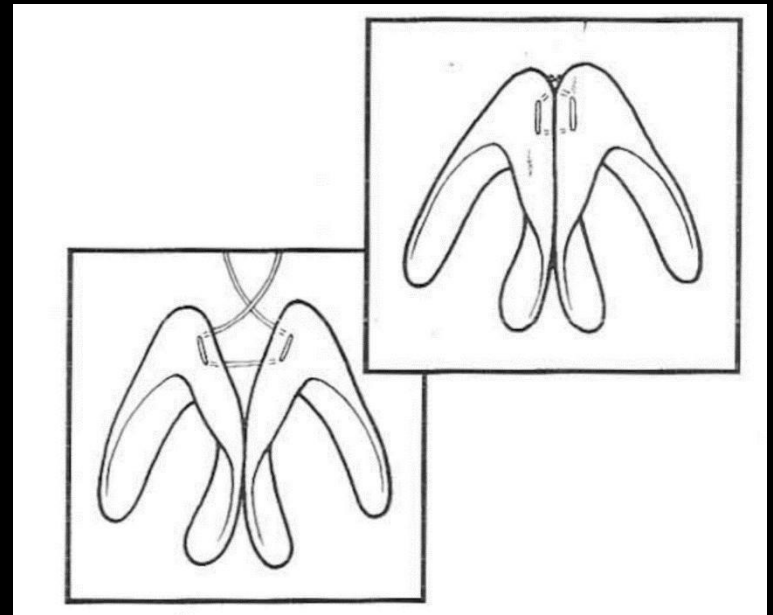


SHAPE

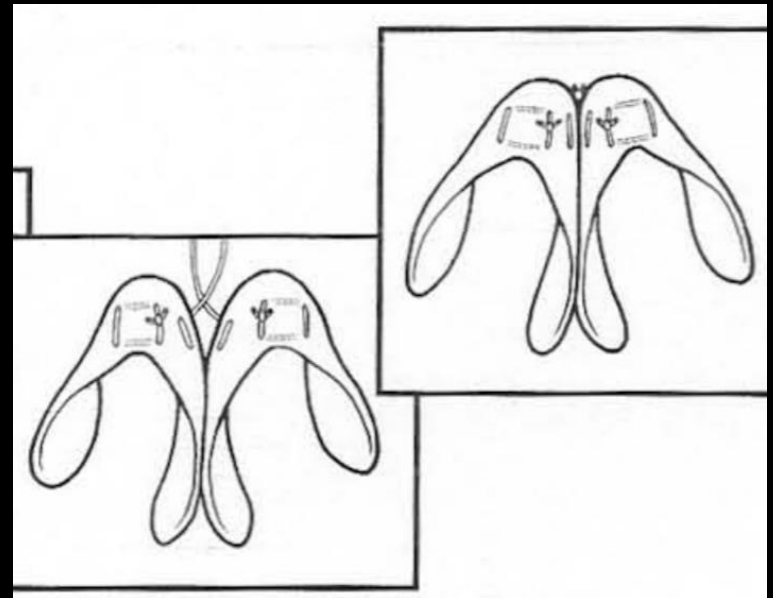
- When viewed from the base of the nose, **the tip** should **appear triangular**.
- If the **alar cartilages are bulbous** or the **domes are wide** the tip looks **trapezoidal**



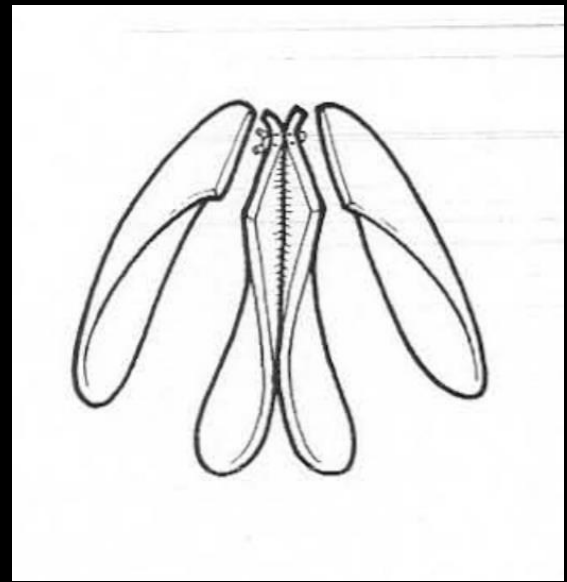
- In patients with V shaped domes, placement of a suture between the medial crura will narrow it and create a more triangular tip.



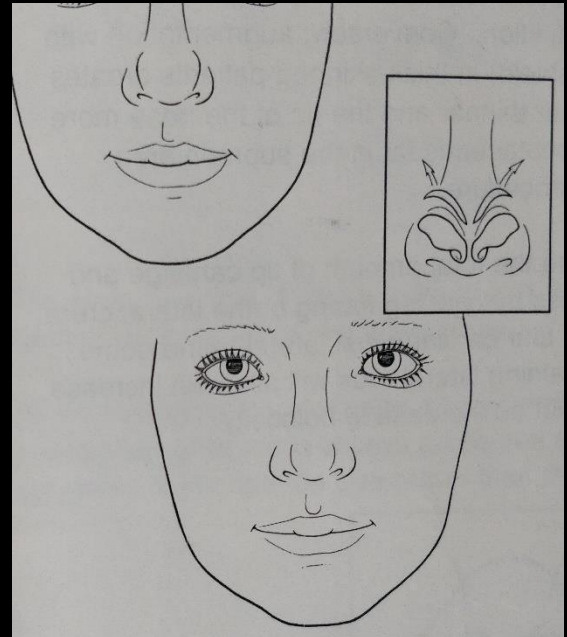
- Alternatively, sutures can be placed in each dome separately. A separate stitch allows precise control of interdomal distance



- For maxial narrowing – domes are divided, medial crura sutured together
- Sharp edges of the cartilage may show through the skin, in thick skinned patients its less evident

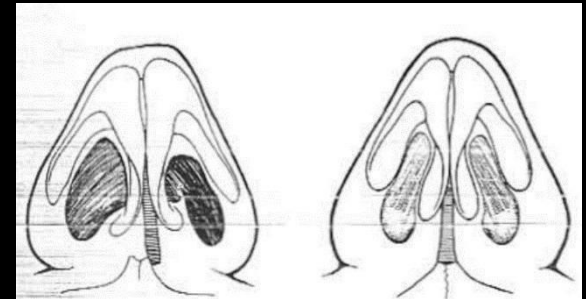
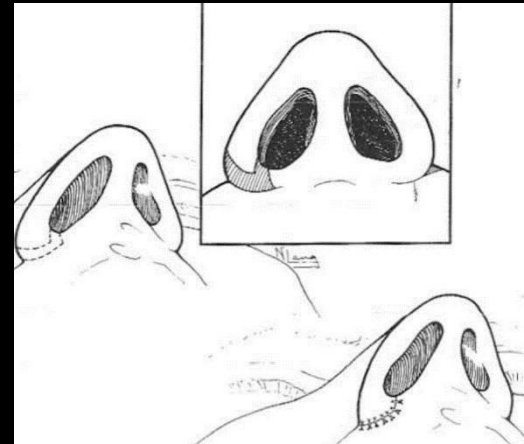
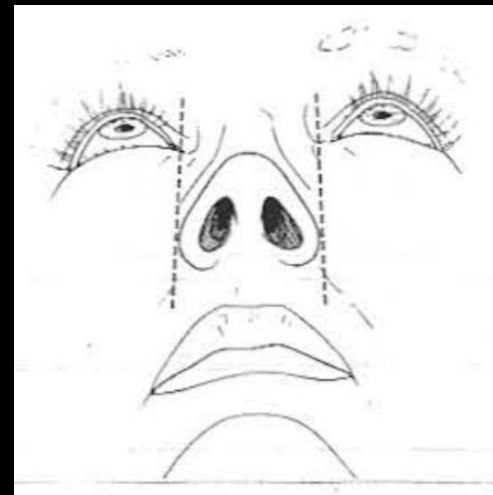


- The bulbousness can be decreased by excising the cephalic portion of the lateral crura.
- A 6 mm wide cartilage is preserved to prevent alar notching.



ALAR BASE

- The alar base should be no more than **1 – 2 mm wider than the inter-canthal distance** when the nose is viewed from its base
- While performing alar base resections, a small flap of tissue is always preserved medially at the base of columella to change the size rather than the shape
- **Asymmetrical nostrils** are usually the result of dislocation of **caudal septum**. Repositioning restores the symmetry



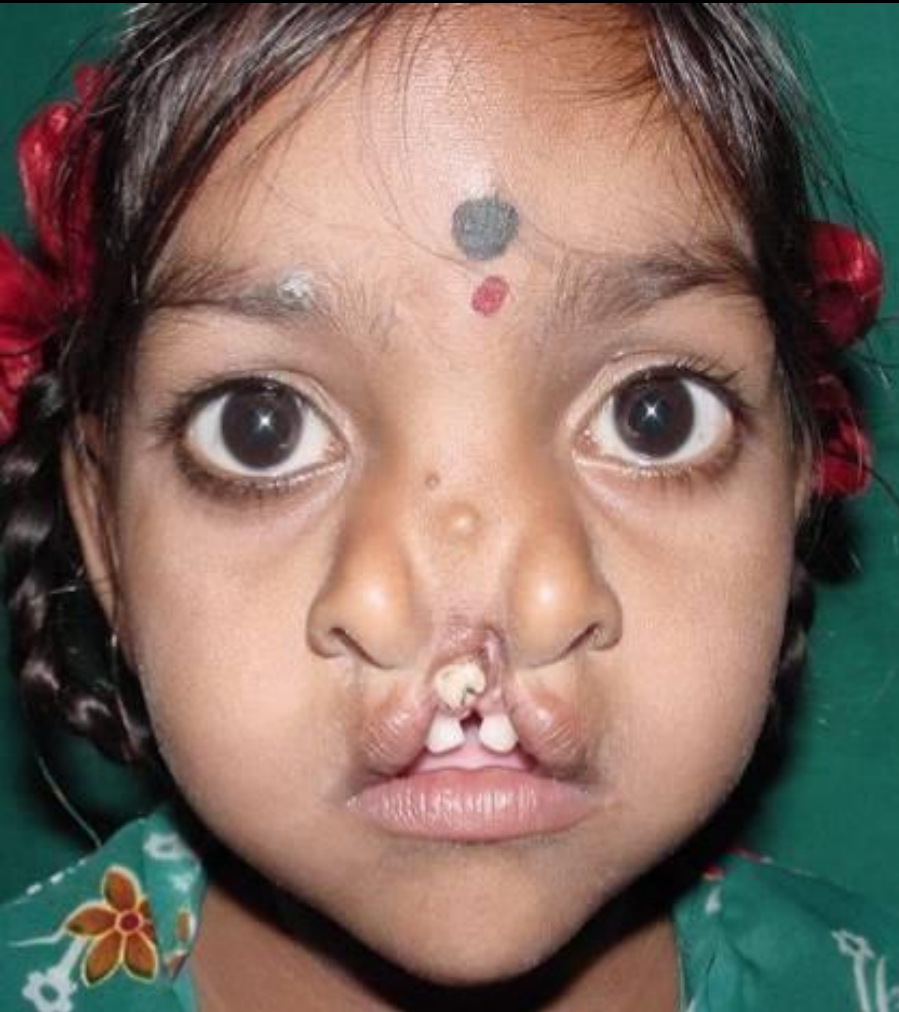Nasal Fracture



- Patients with nasal fractures present to emergency room with substantial swelling - management includes usual procedures employed in any trauma case
- Patient should return for evaluation after the swelling has subsided
- The **traditional treatment** for nasal fracture is **closed reduction**
- Septoplasty is undertaken in cases where septum is fractured as well
- Occasionally medial and lateral osteotomies are performed, if nose continues to deviate even after septoplasty
- **Open reduction** works best when performed **within two weeks of fracture**. After that development of fibrous tissue between the fragments make repositioning difficult.



Bring the Smile Back



Thank You

www.craniofacialinstitute.org