Orbital Osteotomy For Hypertelorism

Prof. Dr. Dr. Srinivas Gosla Reddy
MBBS, MDS, FRCS (Edin.), FDSRCS (Edin), FDSRCS (Eng.), PhD

Dr. Likith Ram Reddy MD DDS
Dr. Sri ramchandra Damaraju MS MCh

Dr. Rajgopal R. Reddy
MBBS, BDS, FDSRCPS (Glasg.), PhD
Dr. Ashish Fanan M.D.S.
Dr. Avni Pandey M.D.S.

GSR Institute of Craniofacial Surgery
Hyderabad India

GSR Institute of Facial Plastic Surgery

- Non-profit hospital established in 1996
- Dedicated Cleft & Craniofacial Centre of Excellence
- Presently 1,600 cleft and cranio-facial surgeries are done every year
- 3 surgeons and 4 fellows with full support team
- More than 30,000 documented cleft & craniofacial surgeries have been performed since 1996
- 600 primary new born cleft children are registered every year

Definition

D. M. Grieg

first described hypertelorism in 1924

Definition

I. T. Jackson et al

first defined Hypertelorism and Teleorbitism as

Lateralization of the total orbital complex with resulting increases in the interorbital distance and intercanthal width.

The intercanthal and interpupillary distances are increased and may be symmetric, asymmetric, or unilateral.

Definition

H. F. Sailer et al.

Further modified the definition to include lateral orbital wall distance.

Increase in the distance between the lateral orbital walls and the interorbital distance to denote true hypertelorism

Intercanthal distance measurement should be done clinically for aesthetics.

Measuring Orbital Hypertelorism

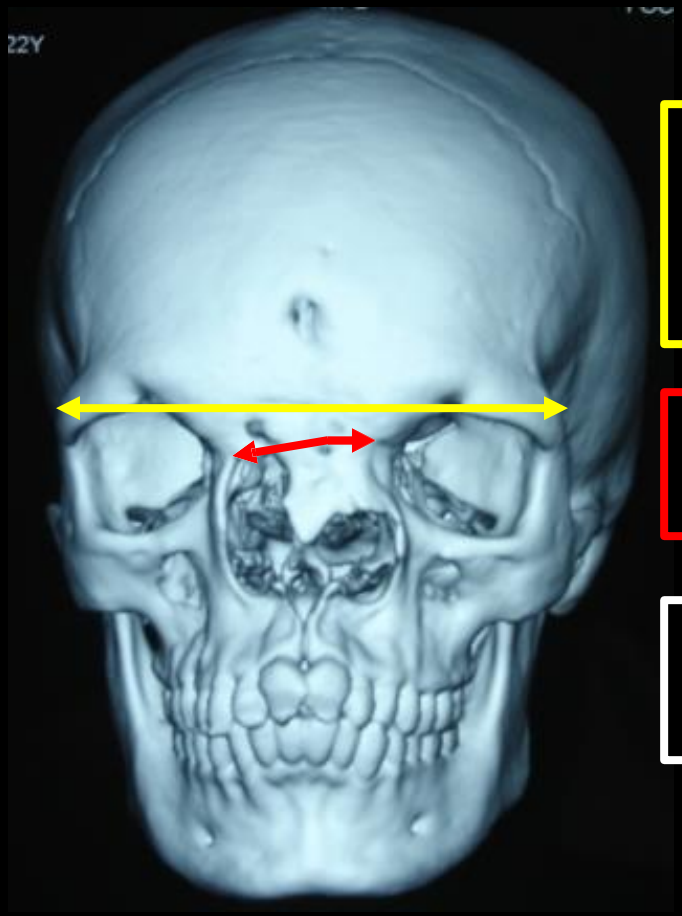

Lateral orbital wall distance

Inter orbital distance

Inter canthal distance

Interorbital distance = distance between the right and left dacryon points

These points correspond clinically to the bony anterior lacrimal crests

Classification

Hypertelorism is a physical finding, that may or maynot be a part of a syndrome.

It is usually secondary to another deformity

I.T. Jackson et al. classified the cause of Orbital Hypertelorism as one of the following

- Cleft related
- Traumatic
- Frontonasal encephalocele
- Ethmoidal and frontal sinus pathology
- Nasal pathology
- Craniosynostosis, Apert's and Crouzon's syndromes

We have developed our own classification based on this classification to help us plan hypertelorism correction

Sailer's Classification

Medial Hypertelorism

- Caused by pathology that leads to hypertrophy, hyperplasia or derangement of the fronto-nasal-ethmoidal complex.

  Eg. Cleft related, Naso/frontal encephalocele, nasal/ethmoidal bone hyperplasia.

Lateral Hypertelorism

- Caused by pathology that causes synostosis of the cranial-zygomatic-maxillary complex

  Eg. Craniosynostosis, Apert/Cruzon syndromes

Classification: Cleft Related Bilateral Orbital Hypertelorism

Hyperplasia of Bilateral Ethmoidal sinus

Classification: Cleft Related Unilateral Orbital Hypertelorism

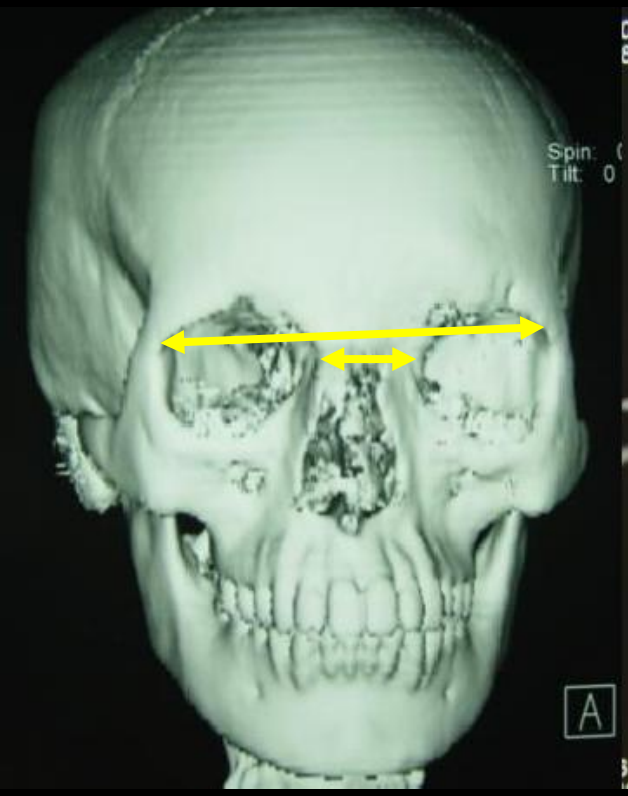

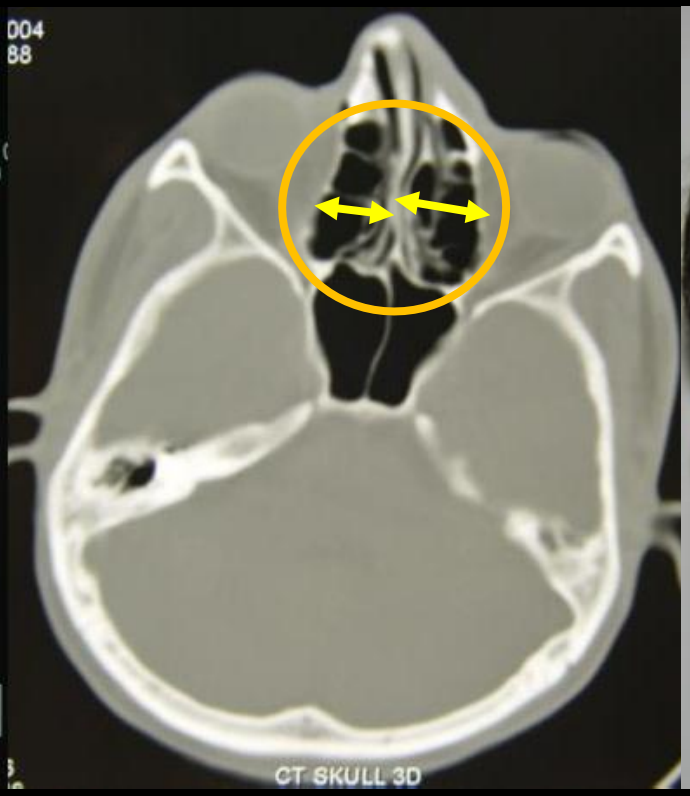



Hyperplasia of Left Ethmoidal sinus

Classification: Traumatic

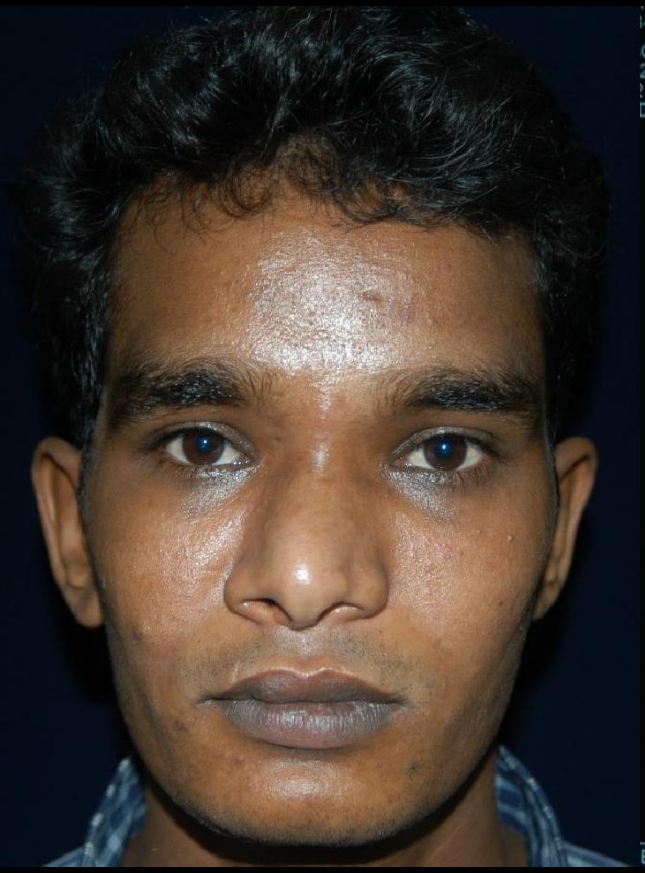

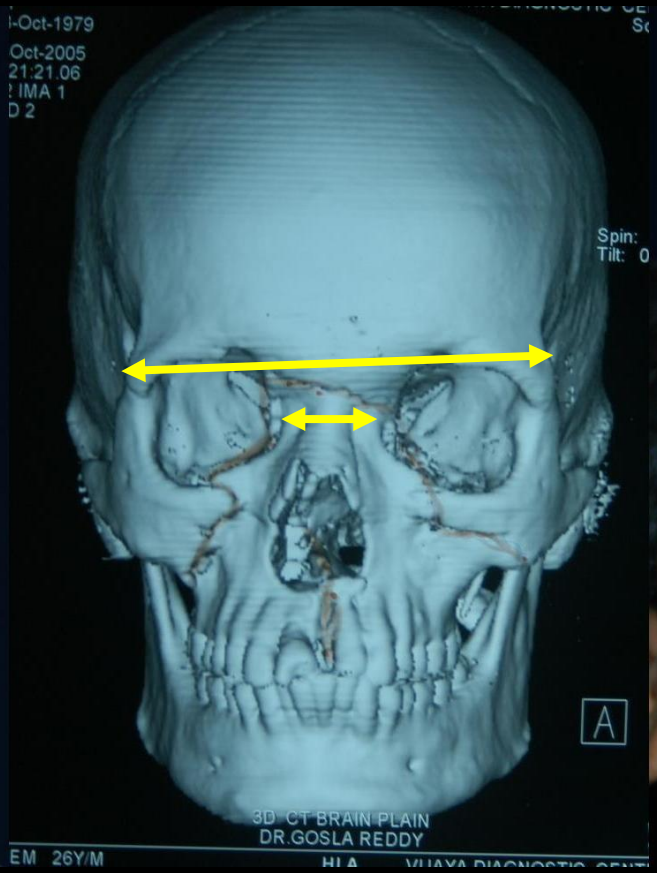

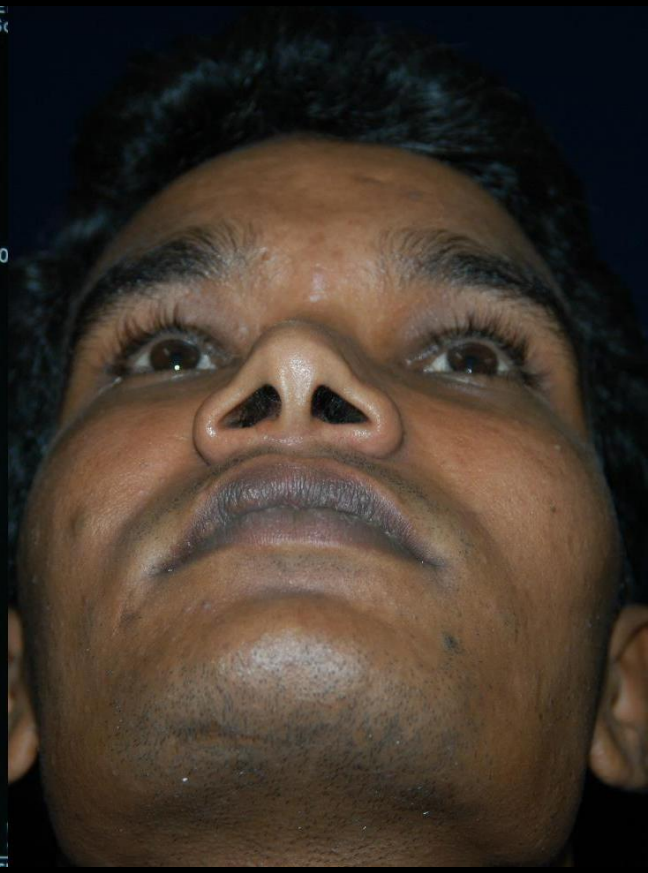

Increase in the volume of Ethmoidal sinus

Classification: Fronto-Nasal Encephalocele (Pseudohypertelorism)

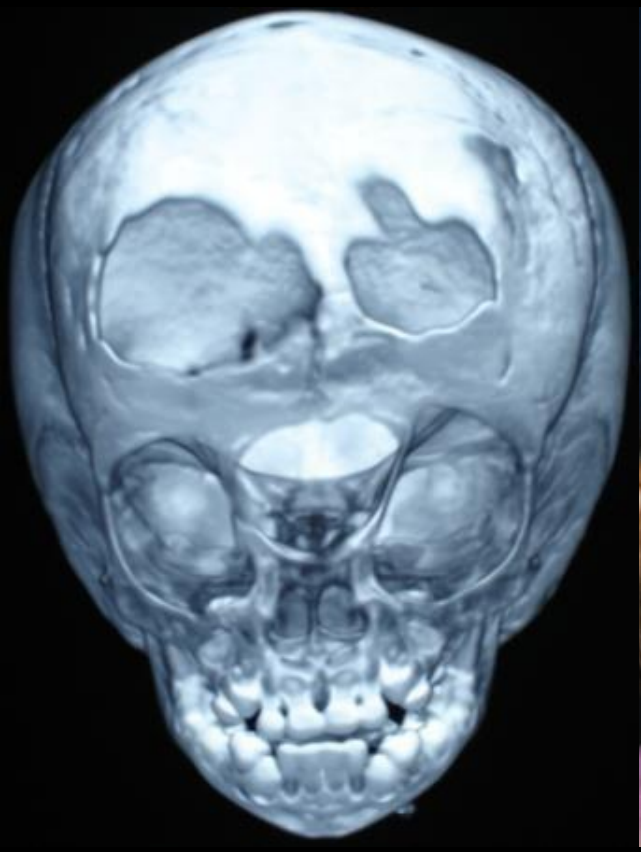

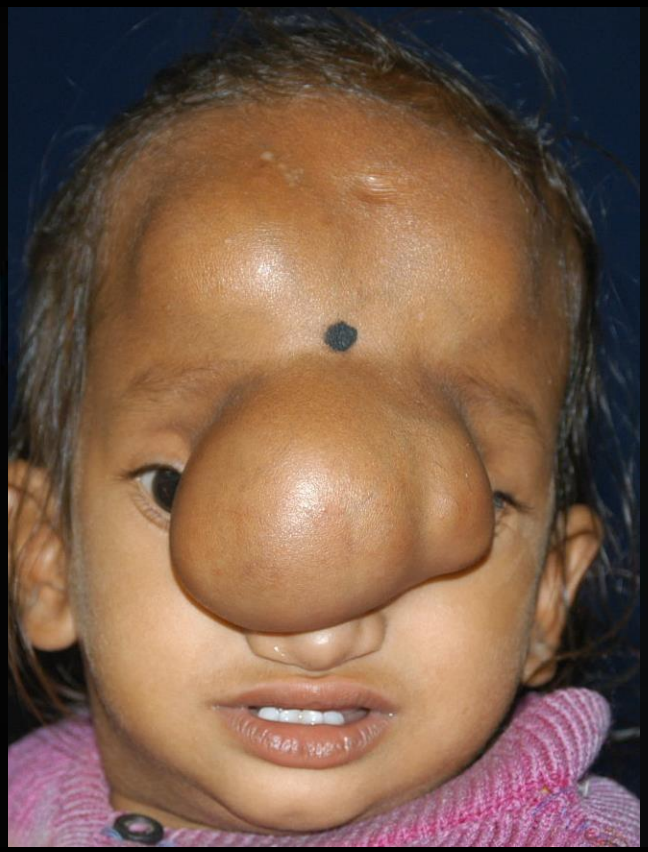

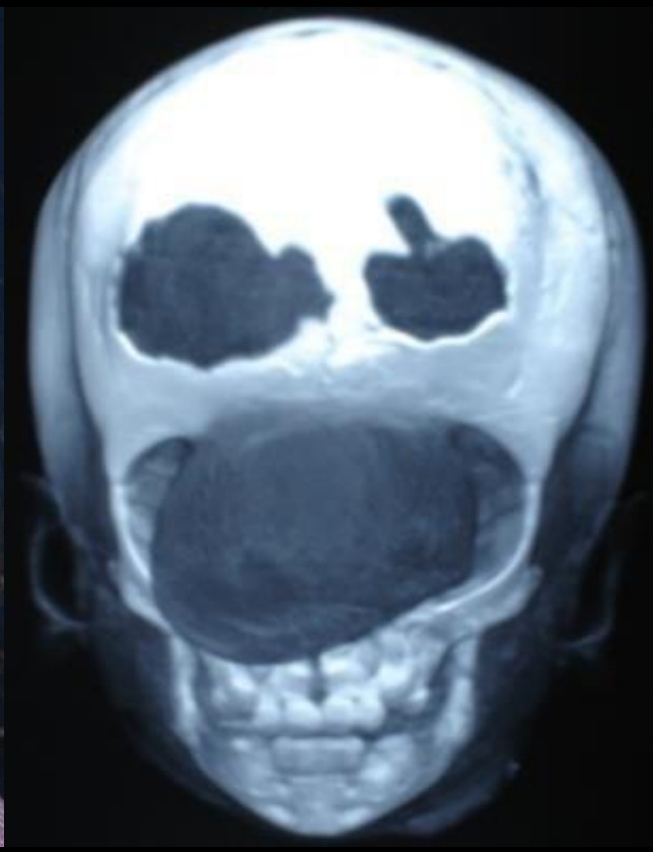

Increase in the volume of Ethmoidal sinus

Classification: Nasal Pathology

Increase in the volume of Ethmoidal sinus

Classification: Aperts Syndrome

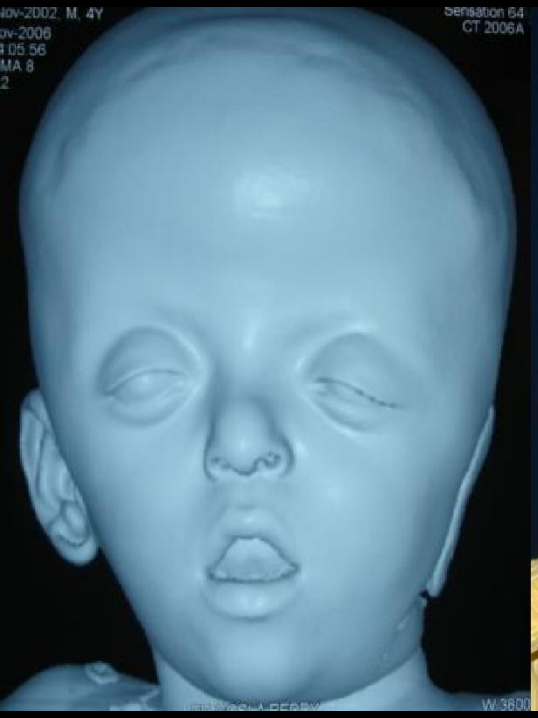

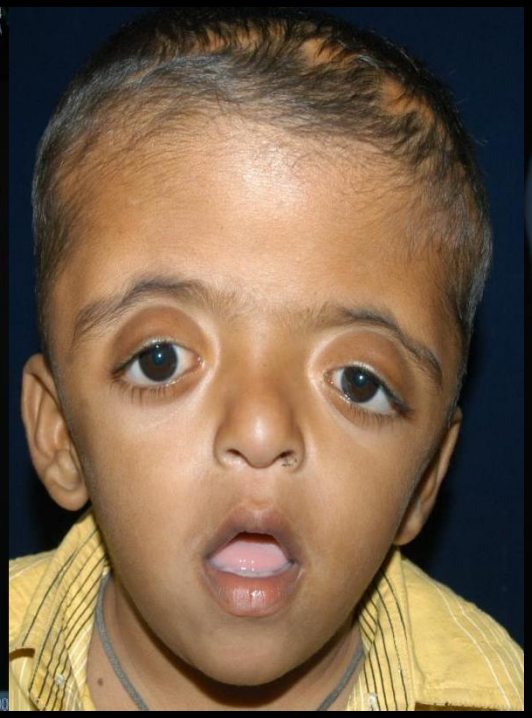

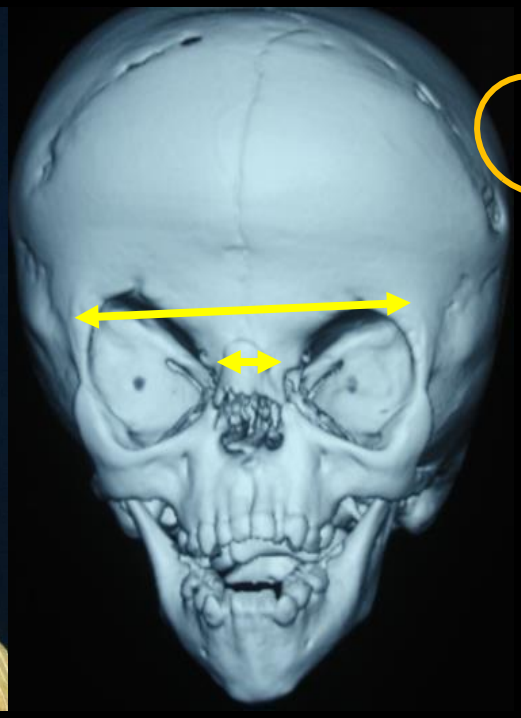

Lateral orbital wall distance is increased.

Severity

Paul Tessier

Classified the severity of orbital hypertelorism into three categories of increased interorbital distance.

Type	Distance (mm)	Severity
I	30 to 34	Mild
II	35 to 39	Moderate
III	> 40	Severe

Investigations

The best investigations to assess hypertelorism are axial section CT scans of thefacial bones.

Investigations

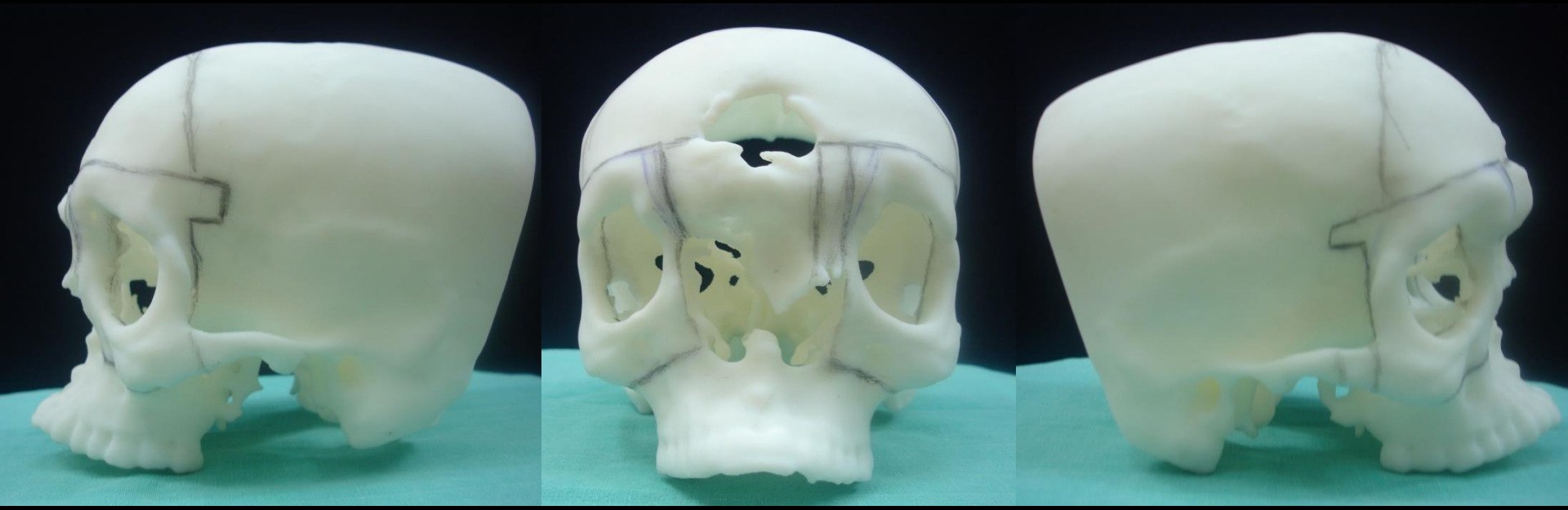

The best way to plan hypertelorism correction is with stereo lithographicmodels.

Treatment

Intracranial Hypertelorism Corrections

GSR Hospital

Year	Number
2006	03
2007	05
2008	06
2009	05
2010	06
2011	04
2012	06
2013	05
2014	06
2015	05
2016	03
2017	01
Total	55

Treatment

Principles of Treatment

- First principle — Combine as many small procedures as is safe and practical into one operation
- Second principle — Decrease infection rates by limiting combined intraoral and intracranial procedures.
- Third principle — Decrease the number of revisionary and redo procedures.
- Fourth principle — Maximize the overall long-term functional and aesthetic results.

Treatment

Mild Hypertelorism

- Caused by trauma or nasal pathology.
- Conservative management.

Severe Hypertelorism

- Caused by encephalocele, facial clefting or in Apert's and Cruzon's syndrome.
- Management through Intra Cranial or Trans Cranial approach

Indications for intracranial approach

- Moderate to severe orbital hypertelorism
- Encephalocele
- Cribriform plate lower than the level of the naso-frontal suture

Treatment

Correcting a functional defect vs. cosmetic defect

- Most hypertelorism corrections are cosmetic defect corrections.
- Even in patients with severe craniosynostosis, frontal monobloc advancement without hypertelorism correction will treat the raised intracranial pressure
- Naso/frontal/ethmoidal encephaloceles are the only functional defects that will be helped with hypertelorism correction

Osteotomy Cuts for Box and Spectacle Osteotomy

Box Osteotomy

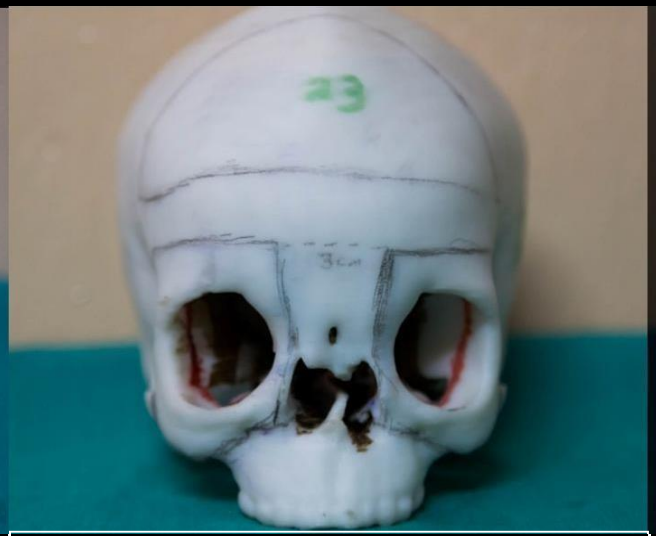

Spectacle Osteotomy

Facial Bi-partition

- Box Osteotomy done in older children and adults
- Done for patients with Medial Hypertelorism (Nasal pathology)

- Spectacle osteotomy done in young children because of better fixation area
- Spectacle osteotomy cannot be done in patients with frontal encephalocele
- Orbits need medial and mostly parallel movement

In infants Spectacle and Box osteotomy is not preferred because of tooth budsin infra orbital region.

Osteotomy Cuts for Facial Bi-partition

Box Osteotomy



Spectacle Osteotomy

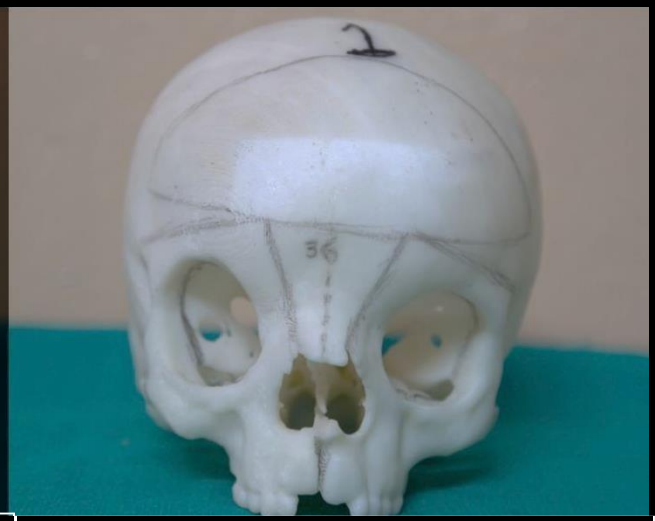

Facial Bi-partition

- **Facial Bi-partition** done in both children and adults
- Done for patients with Lateral Hypertelorism (Cranio-maxillary Defects)
- Orbits that need medial and rotational movements
- Mid palatal maxillary splitting is done to flare the constricted maxilla

Also done in all hypertelorism corrections in infants as this technique ensures no cuts are placed in the region of tooth buds

Box Osteotomy

Orbital Hypertelorism: Treatment

Craniofrontonasal Dysplasia

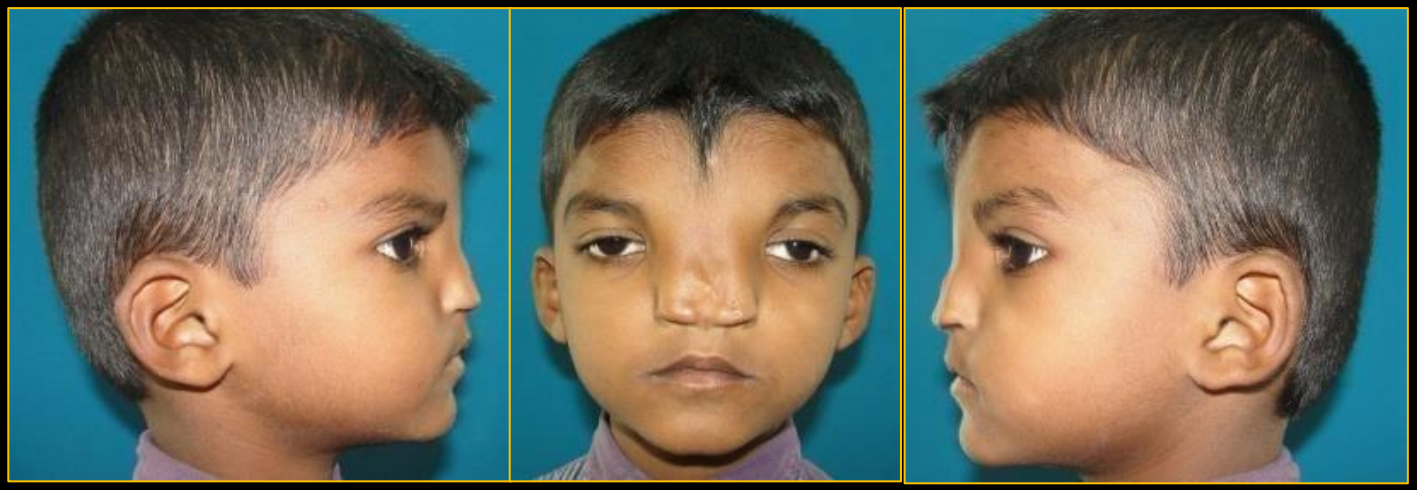

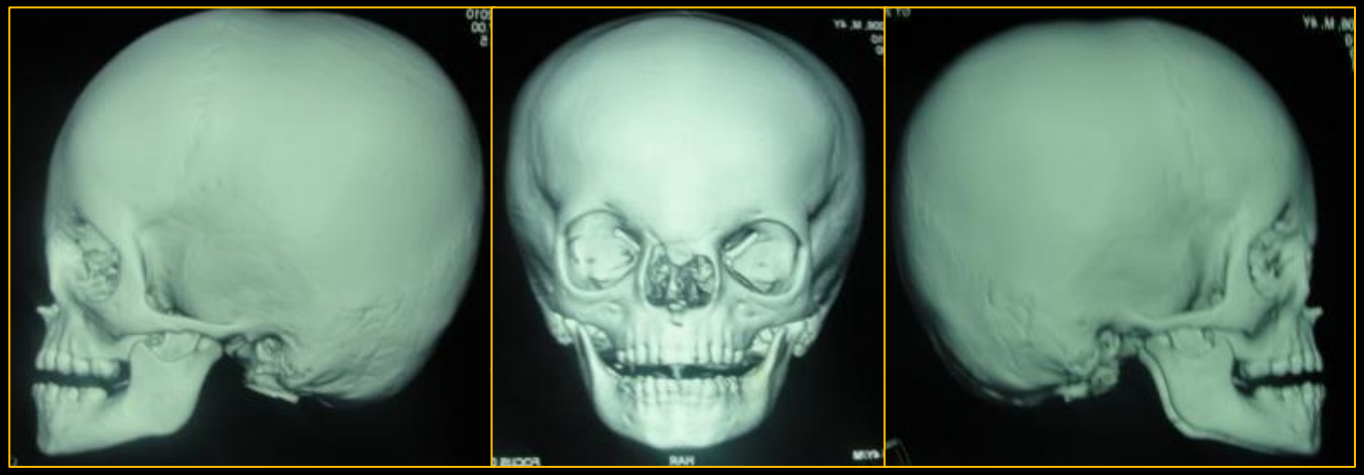

Orbital Hypertelorism: Treatment

Craniofrontonasal Dysplasia

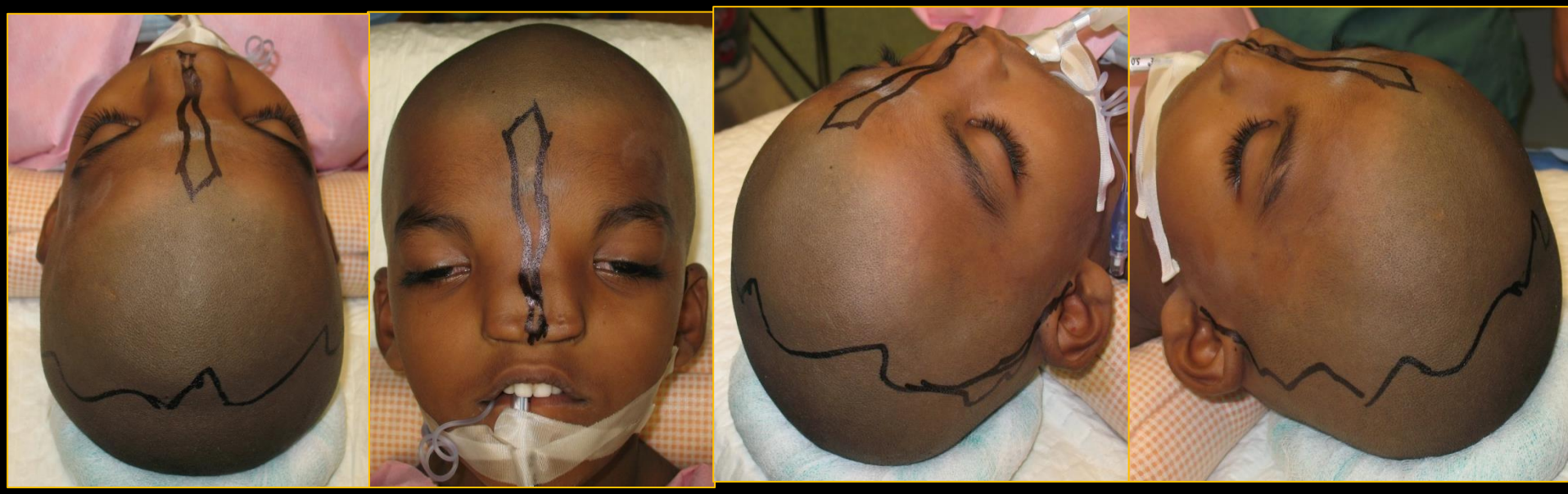

Skin Incision

- The skin incision for the intracranial correction of orbital hypertelorism consists of bicoronal incision with the dissection as far forward and anterior as possible.

Orbital Hypertelorism: Treatment

Craniofrontonasal Dysplasia

Pericranium

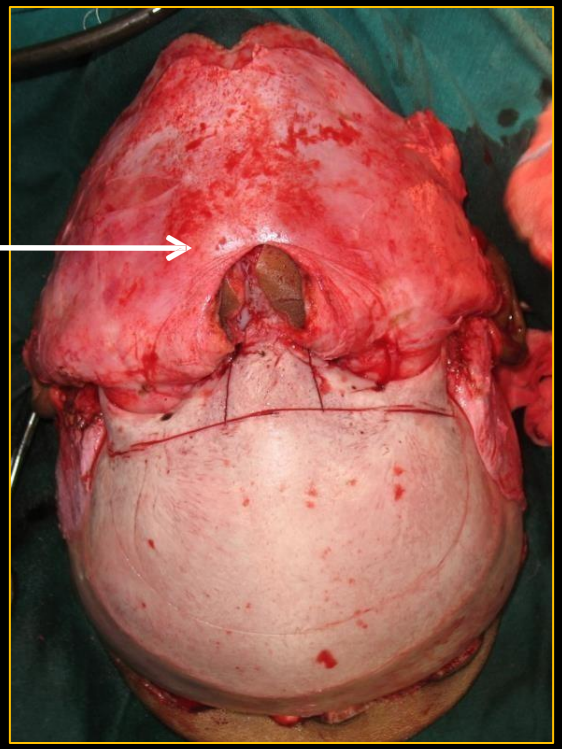

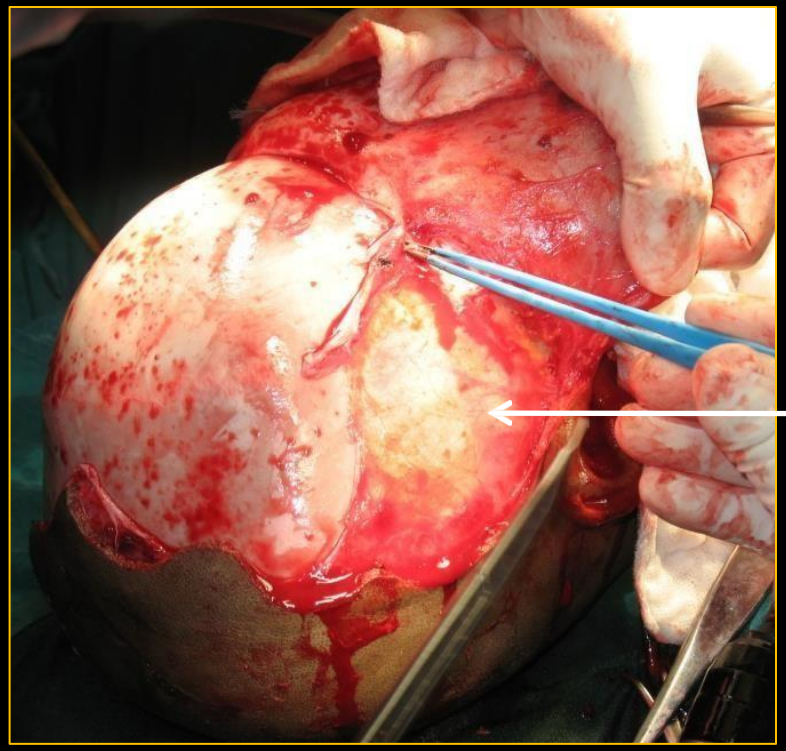

Temporalis Muscle

Raising Bicoronal Flap

- Sub pericranial dissection is done and the pericranial layer is preserved to use if a flap is required
- Dissection is continued temporally to keep temporalis adherent to thebone.

Orbital Hypertelorism: Treatment

Craniofrontonasal Dysplasia

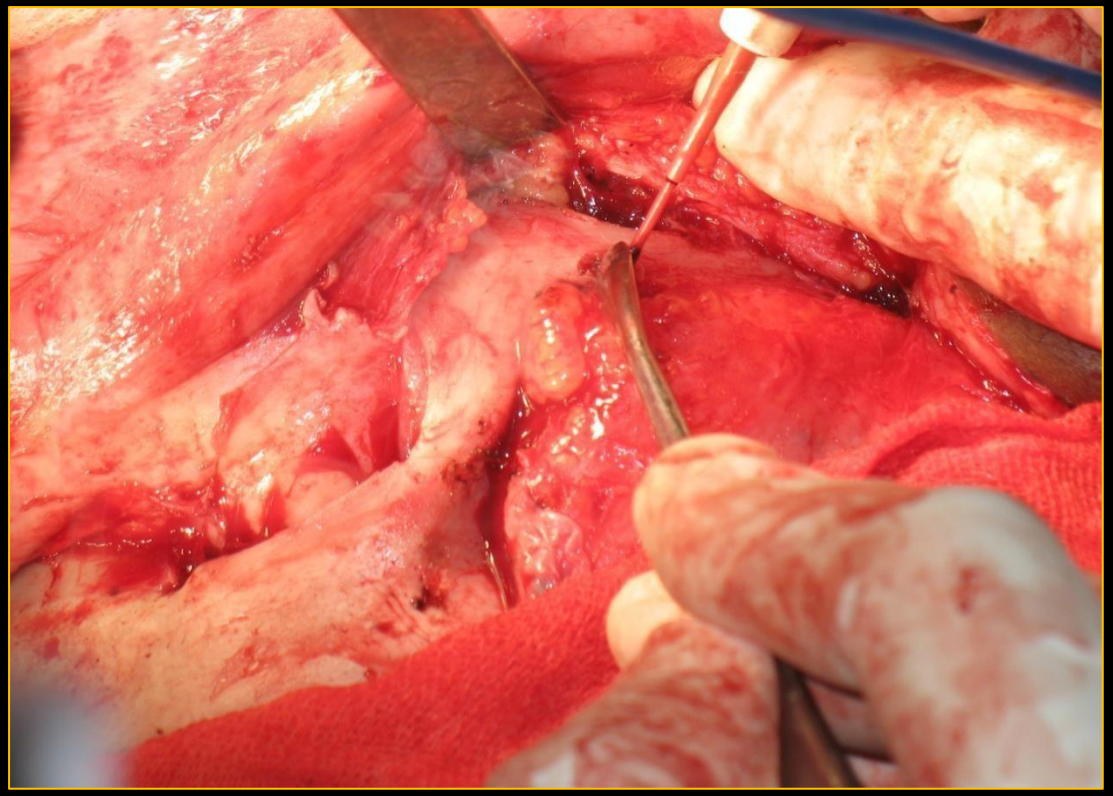

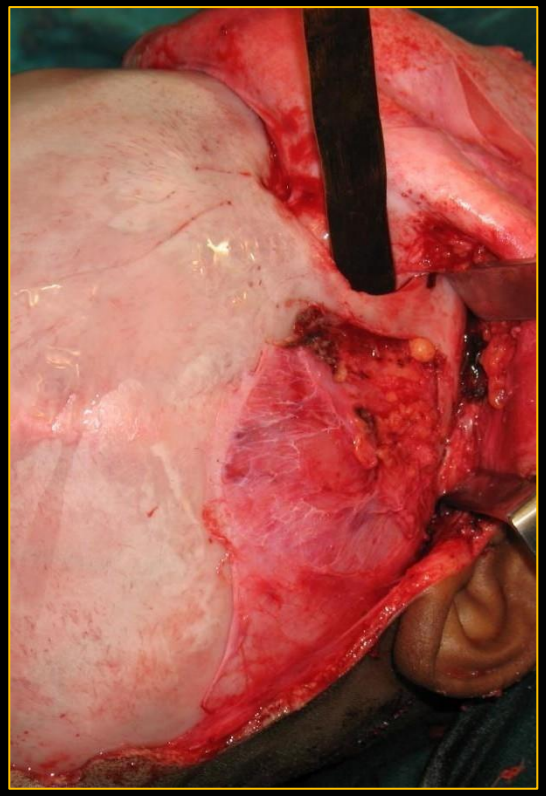

Raising Bicoronal Flap

- Dissection is done in such a way to expose the zygomatic arches.

Orbital Hypertelorism: Treatment

Craniofrontonasal Dysplasia

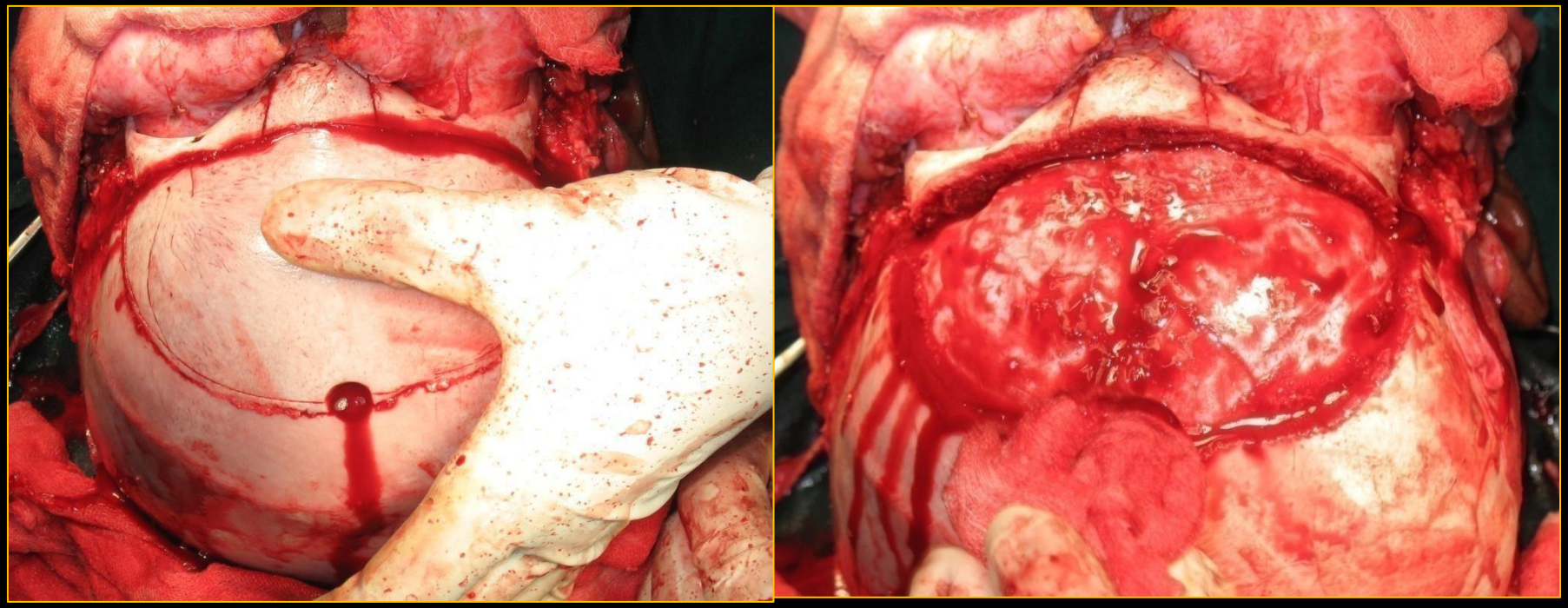

Transfrontal Craniotomy

- Frontal Cranial Flap is raised to facilitate retraction of the brain while orbital osteotomy is being performed

Orbital Hypertelorism: Treatment

Craniofrontonasal Dysplasia

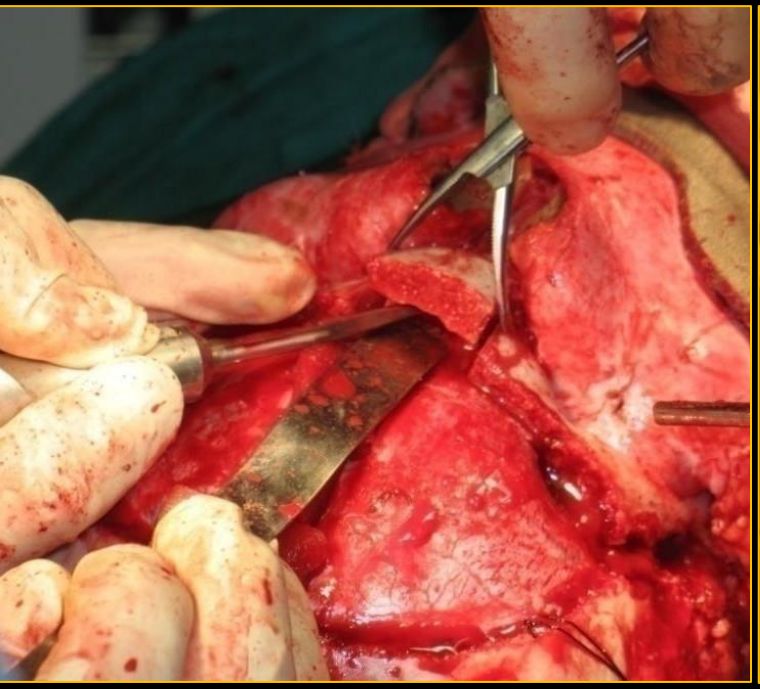

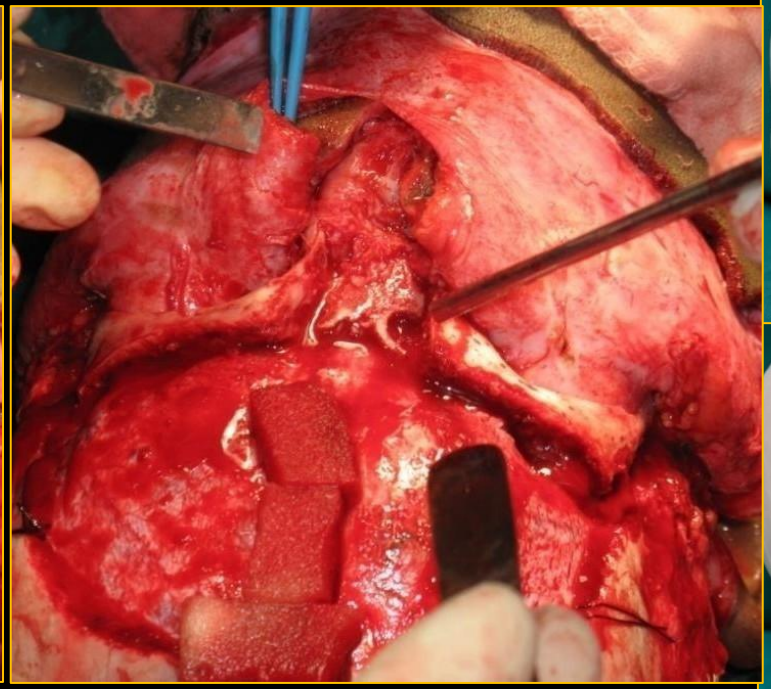

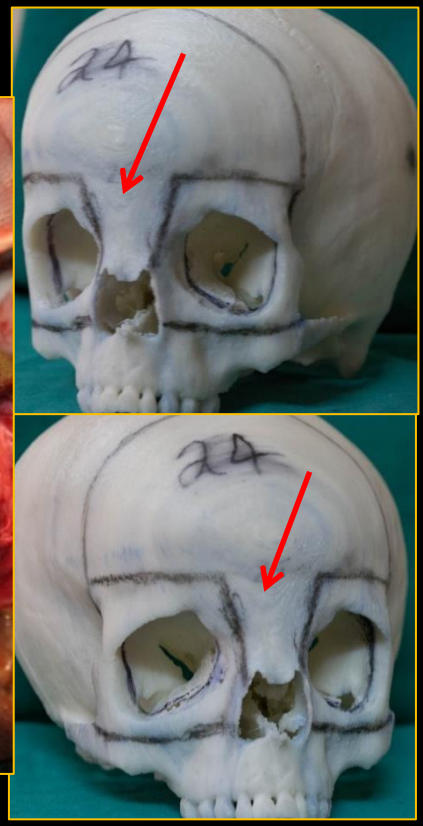

Medial wall of orbit osteotomy

- Central block of bone between the orbits is removed and medial wall osteotomy is done.

Orbital Hypertelorism: Treatment

Craniofrontonasal Dysplasia

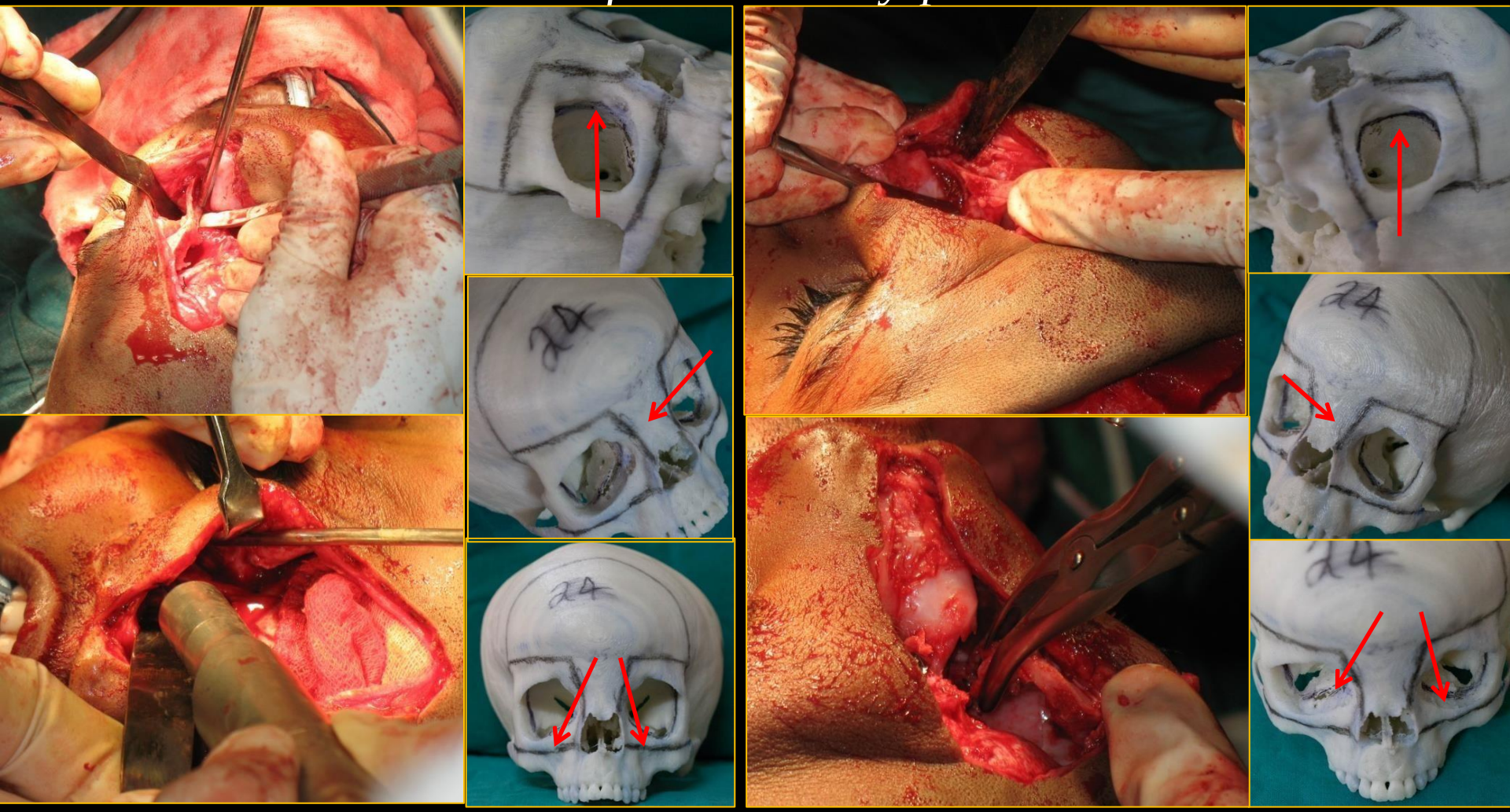

Medial and inferior wall of orbit osteotomy

Orbital Hypertelorism: Treatment

Craniofrontonasal Dysplasia

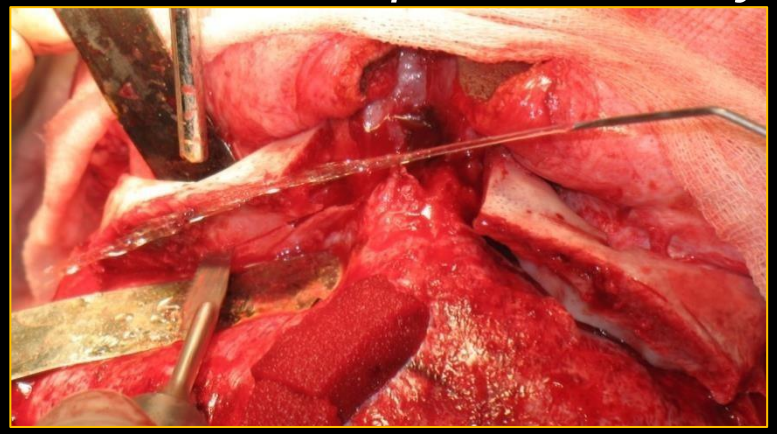

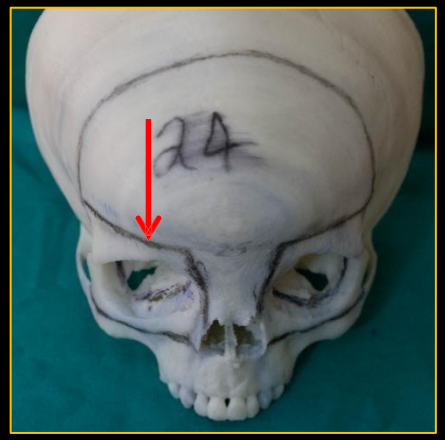

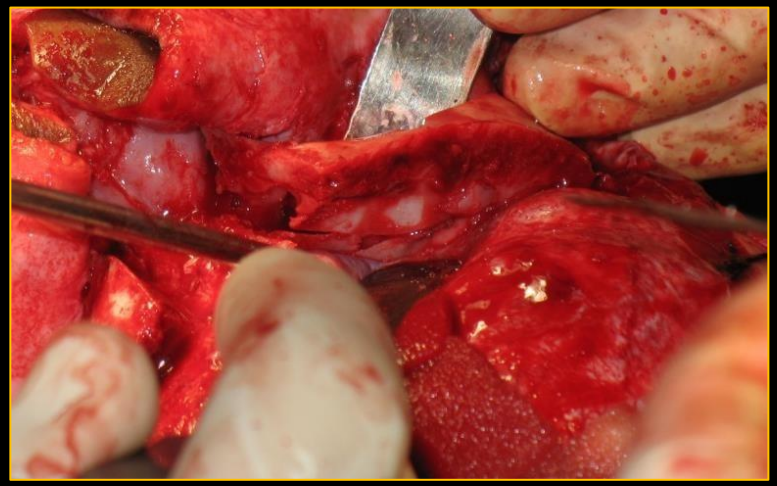

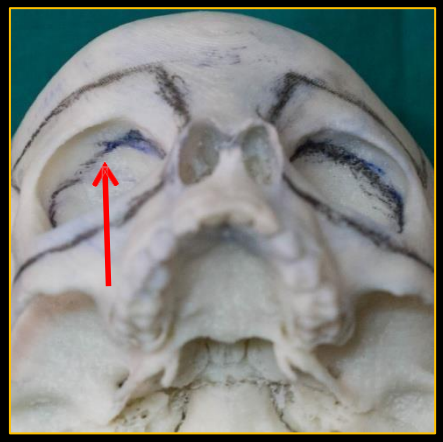

Orbital roof osteotomy

- Bony cuts of the orbital roofs are performed with intracranial visualization

Orbital Hypertelorism: Treatment

Craniofrontonasal Dysplasia

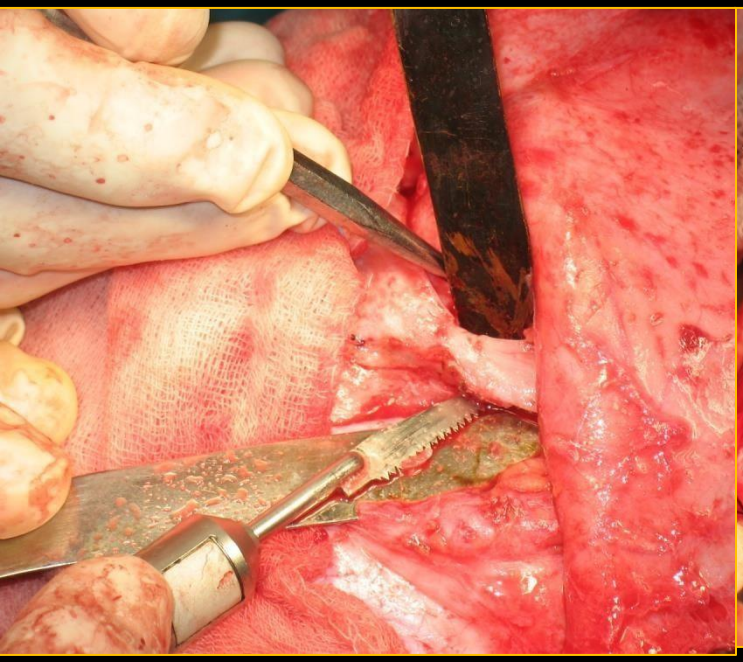

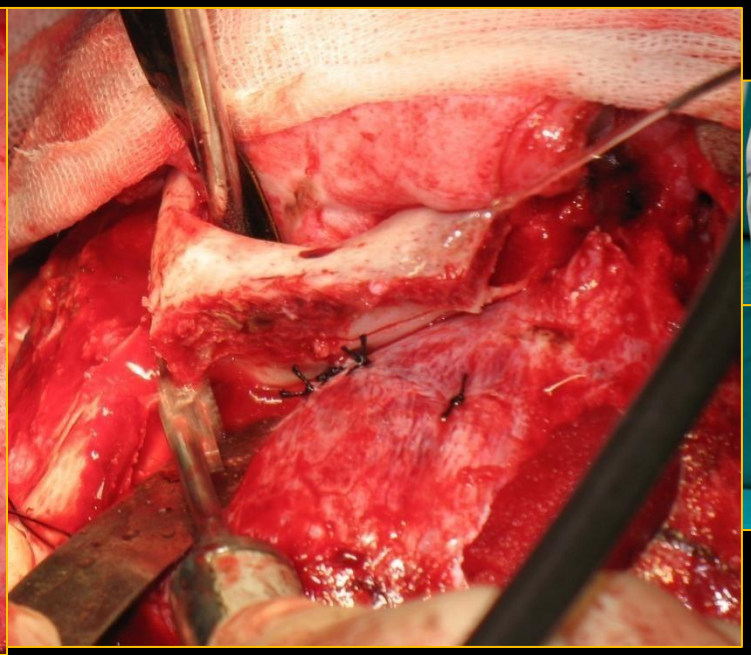

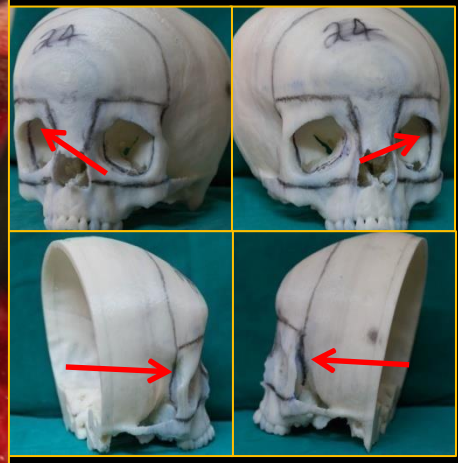

Lateral Orbital Wall Osteotomy

- Initially extracranially, through the fronto-zygomatic region
- Final cut superiorly is done intracranially

Orbital Hypertelorism: Treatment

Craniofrontonasal Dysplasia

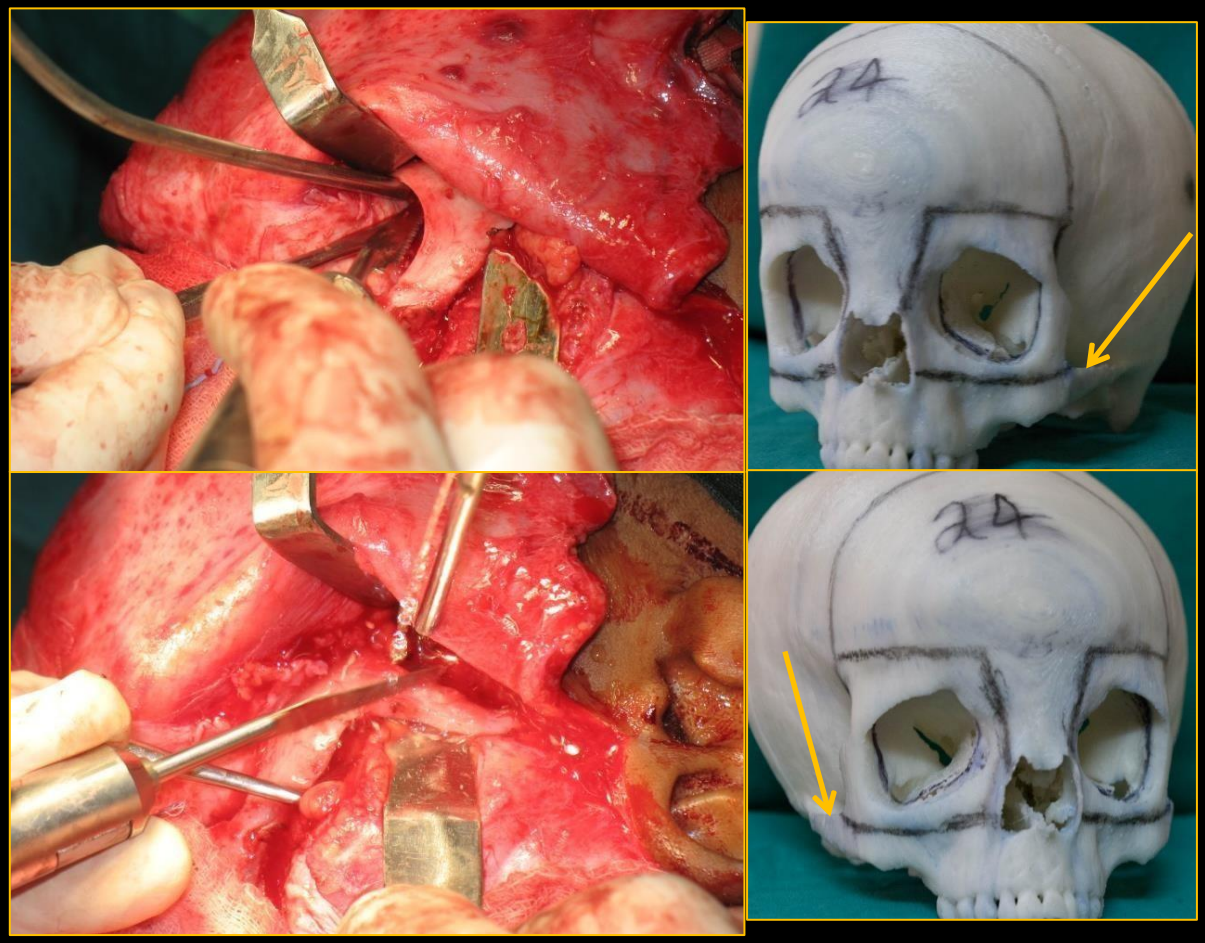

Zygomatic Arch Osteotomy

Orbital Hypertelorism: Treatment

Craniofrontonasal Dysplasia

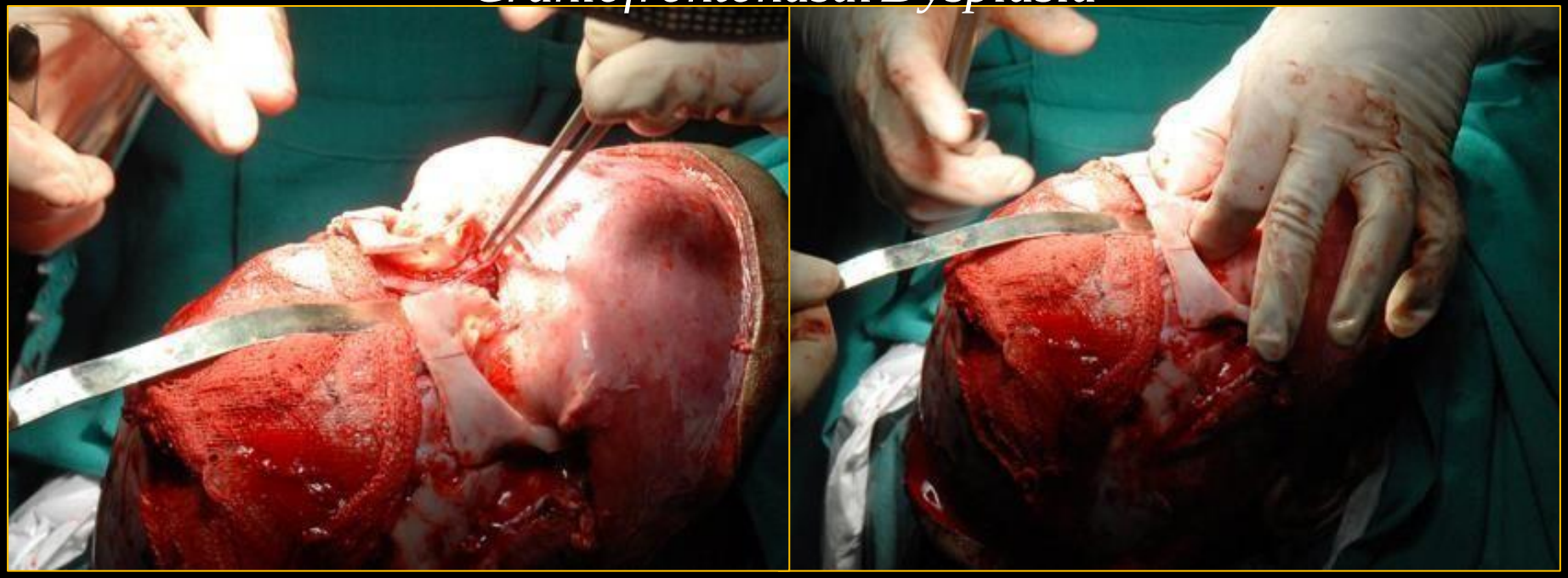

Finishing osteotomy/Inferior wall osteotomy

- Wedge of bone is removed from either side of piriform fossa so that the nasal airways are not constricted when the orbits are moved medially
- If the osteotomies have been performed to their full depth, the orbits can be approximated by finger pressure alone

Orbital Hypertelorism: Treatment

Craniofrontonasal Dysplasia

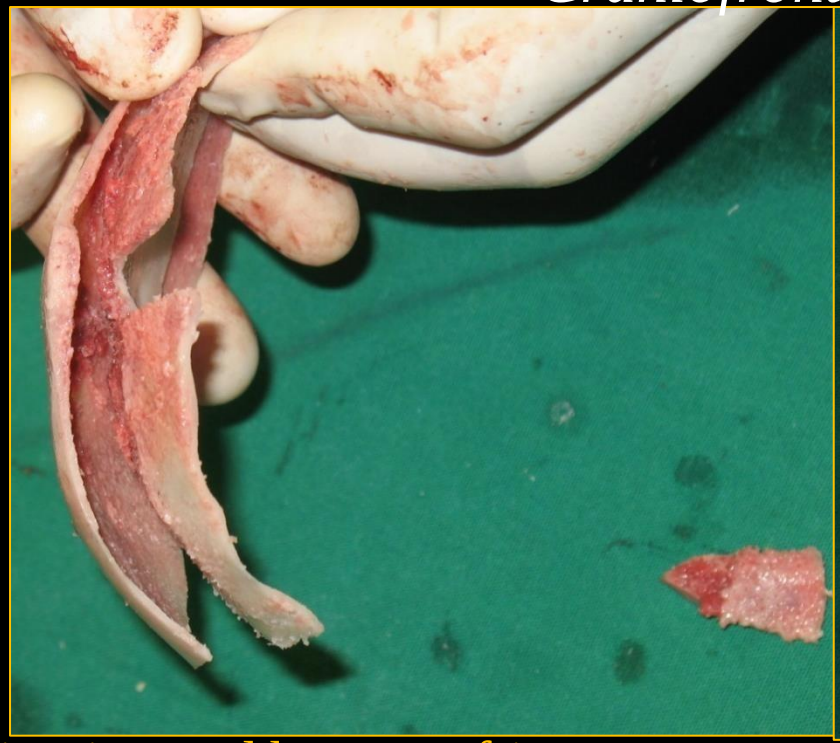

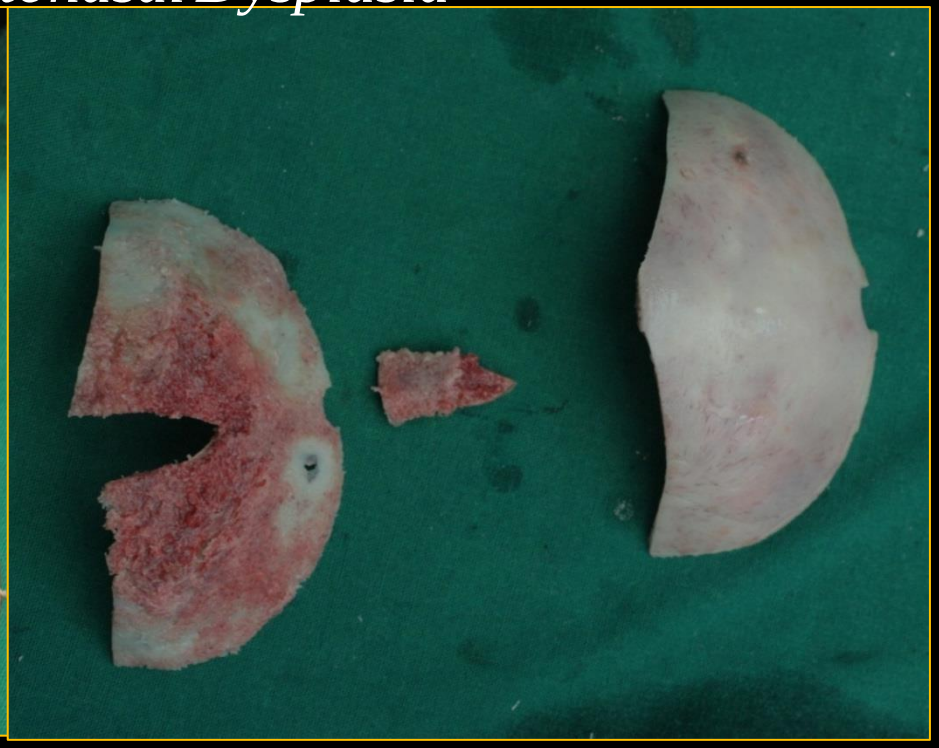

Fixation and bone grafting

- Bone graft material harvested from the calvarium can be split into the two cortices and
- One cortex can be used to graft bone in the defects and the other can be used to close the original defect

Orbital Hypertelorism: Treatment

Craniofrontonasal Dysplasia

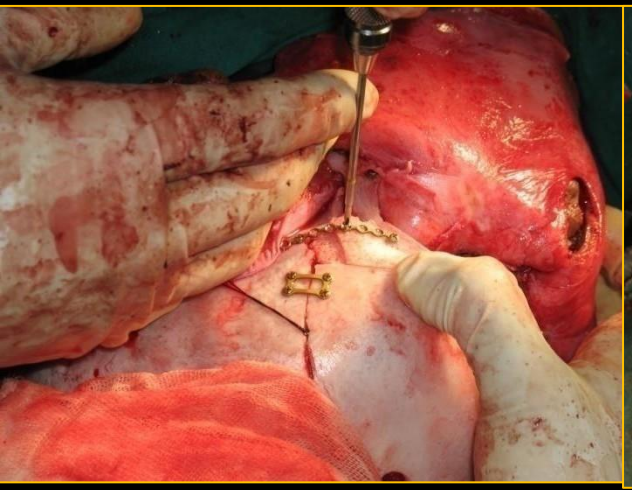
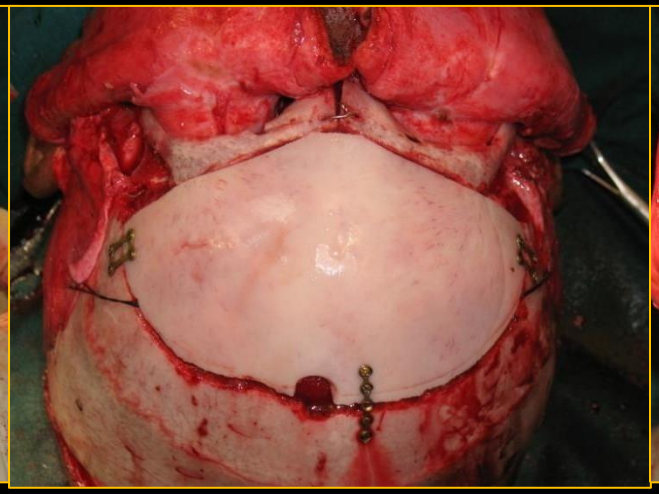
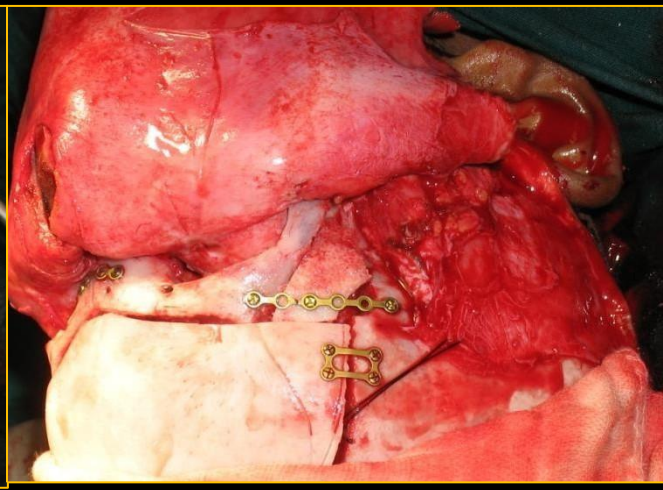

Fixation and bone grafting

- The orbits are positioned and held in place with wires or micro-or miniplates.
- Bone graft material harvested from the clavarium, iliac crest, or rib is then used to fill in the resulting gap defects at the lateral orbital walls and zygomatic areas

Orbital Hypertelorism: Treatment

Craniofrontonasal Dysplasia

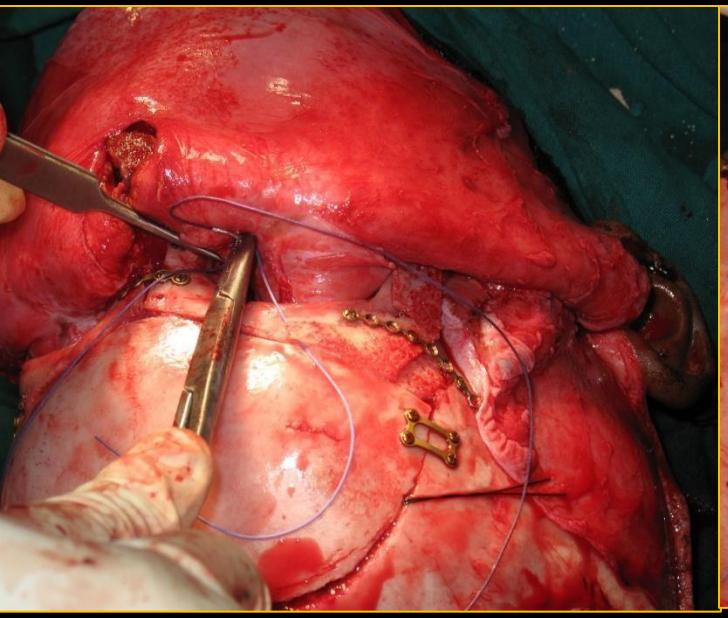

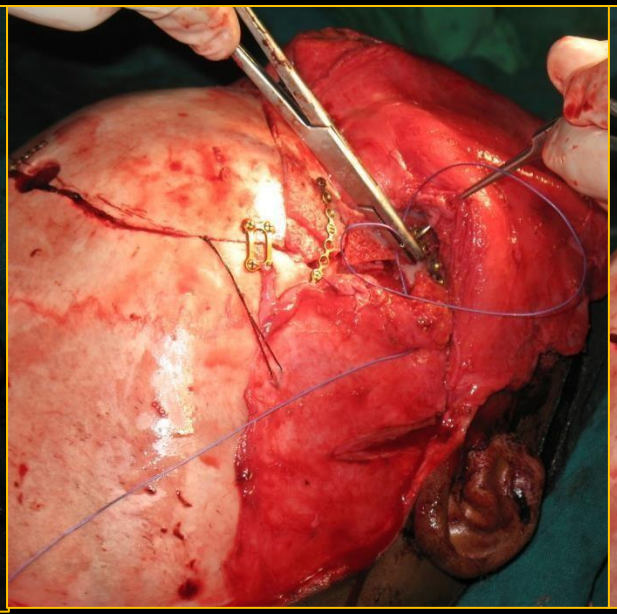

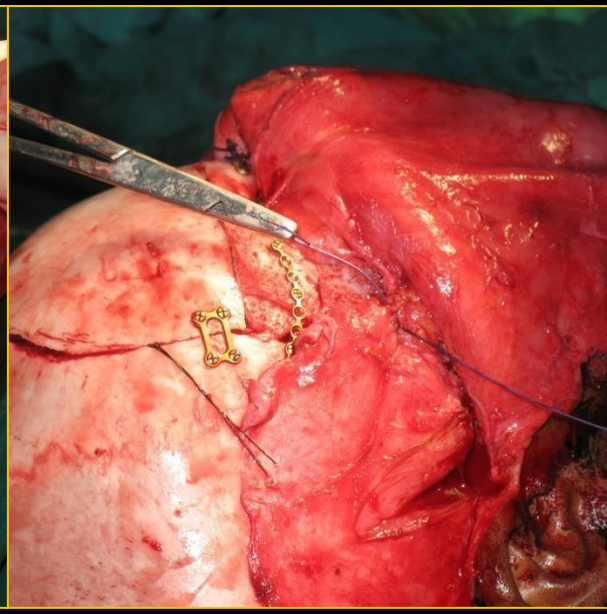

Medial Canthus and Temporalis muscle sling

Orbital Hypertelorism: Treatment

Craniofrontonasal Dysplasia

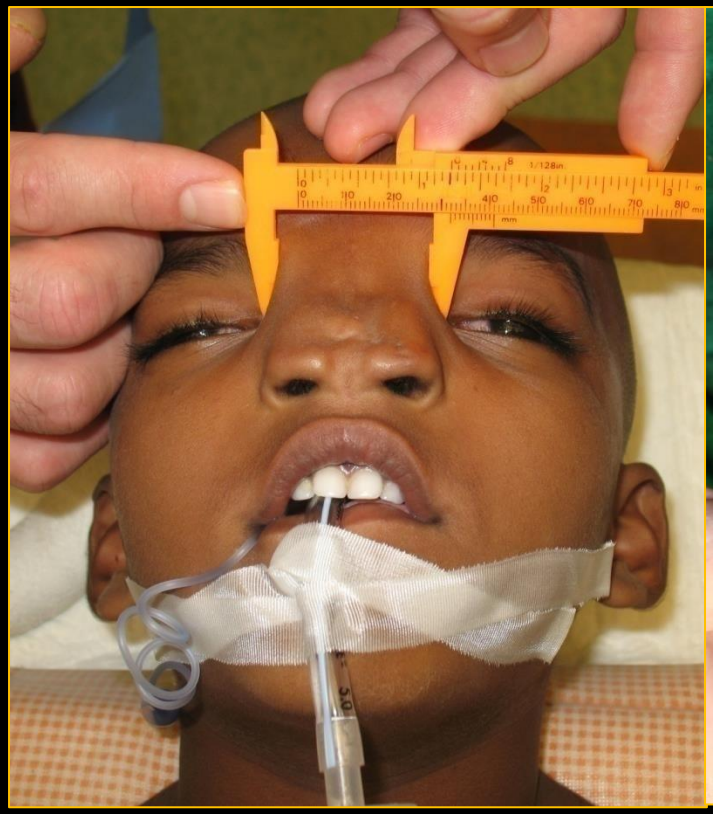

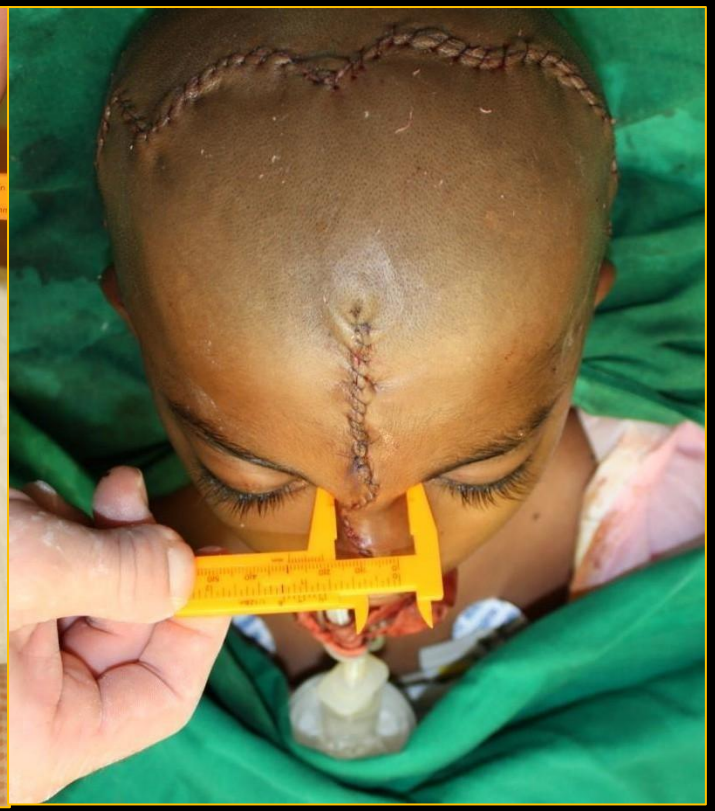

Orbital Hypertelorism: Treatment

Craniofrontonasal Dysplasia

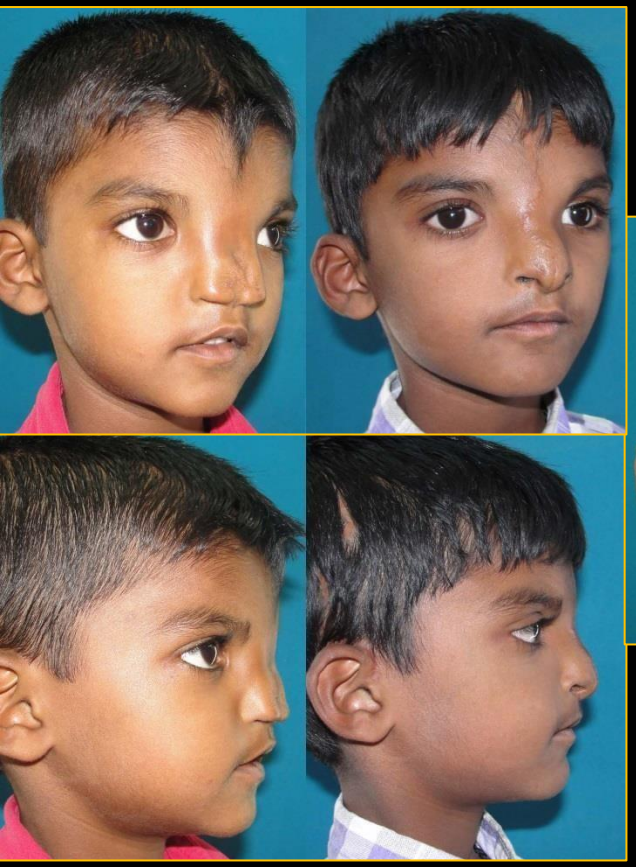

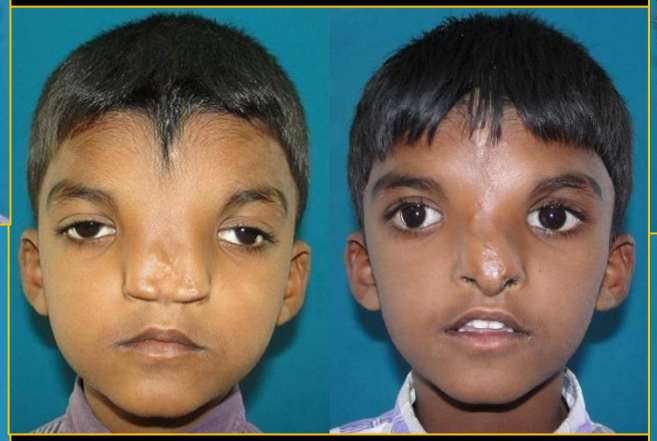

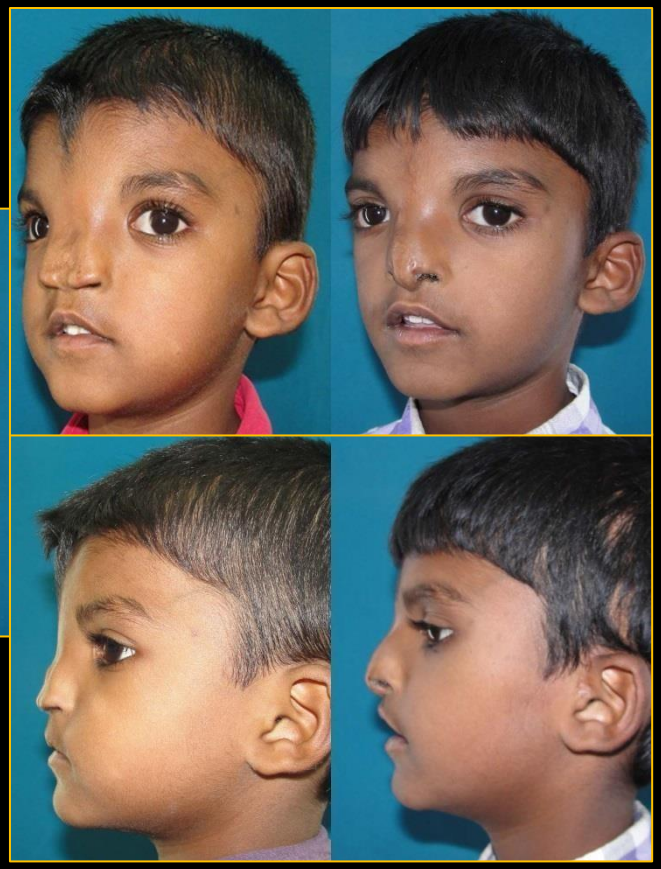

Orbital Hypertelorism: Treatment

Tessier 0-14 Craniofacial Cleft

Orbital Hypertelorism: Treatment

Tessier 0-14 Craniofacial Cleft

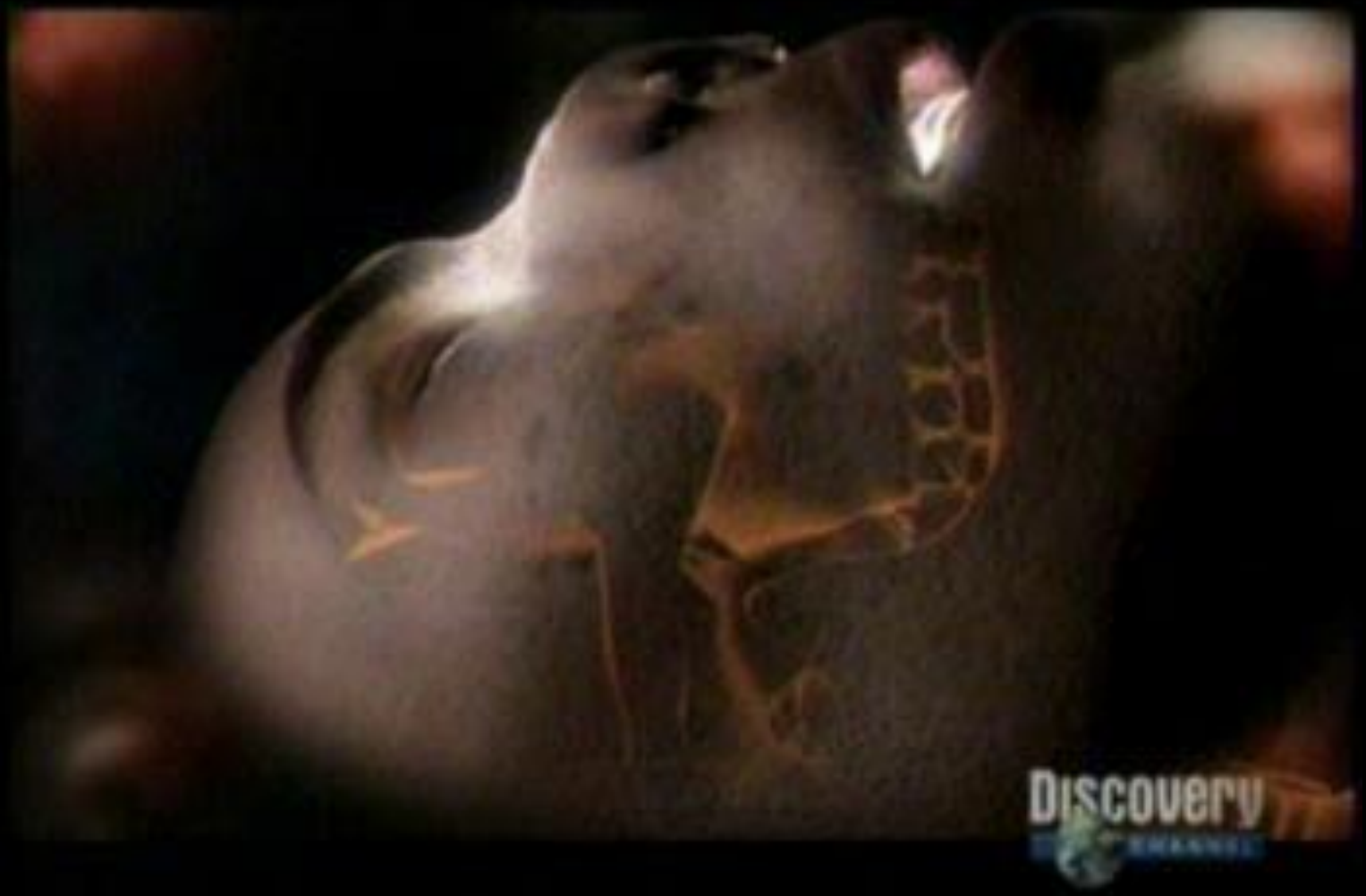

Orbital Hypertelorism: Treatment

Tessier 0-14 Craniofacial Cleft

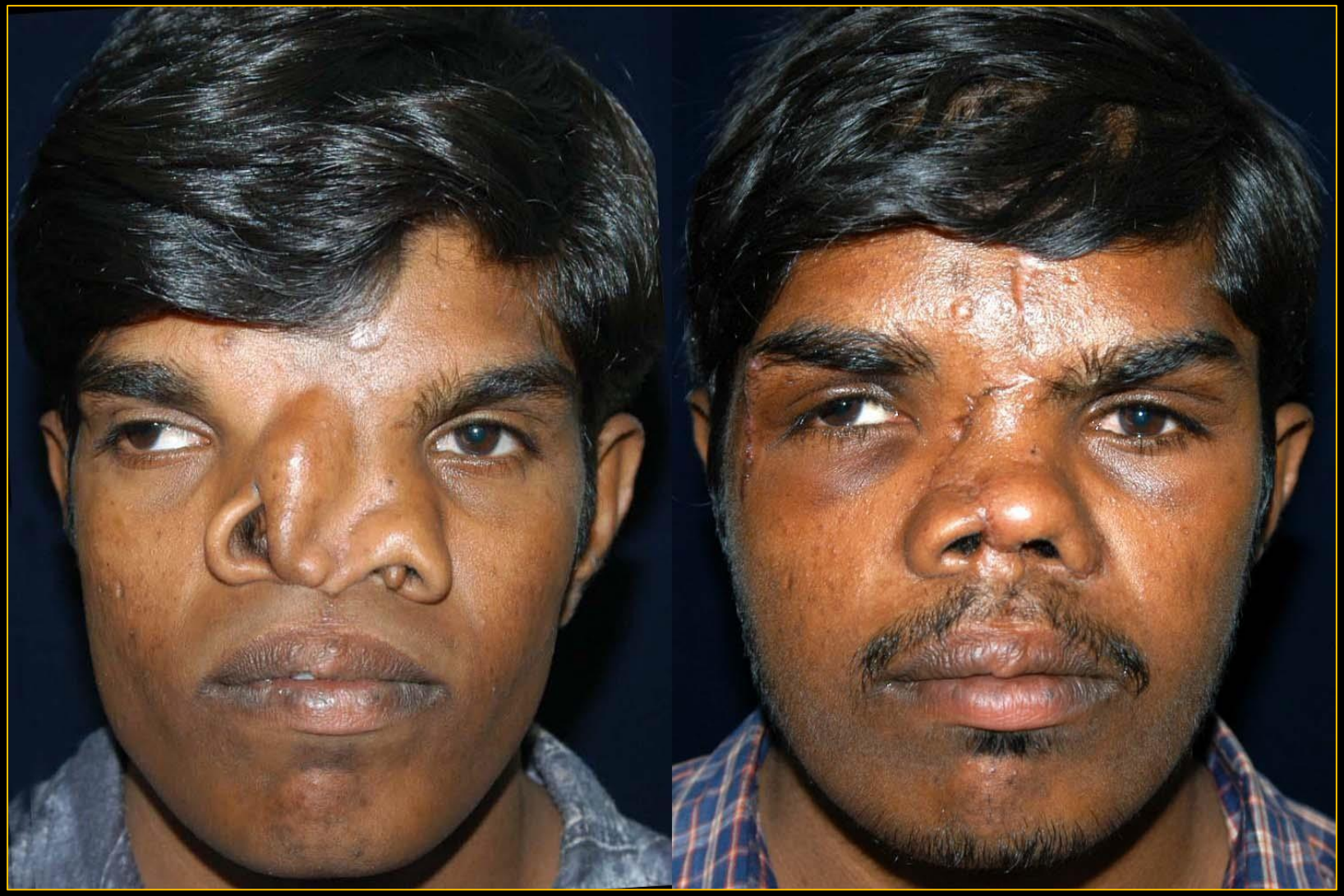

Orbital Hypertelorism: Treatment

Tessier 14 Craniofacial Cleft

Orbital Hypertelorism: Treatment

Encephalocele

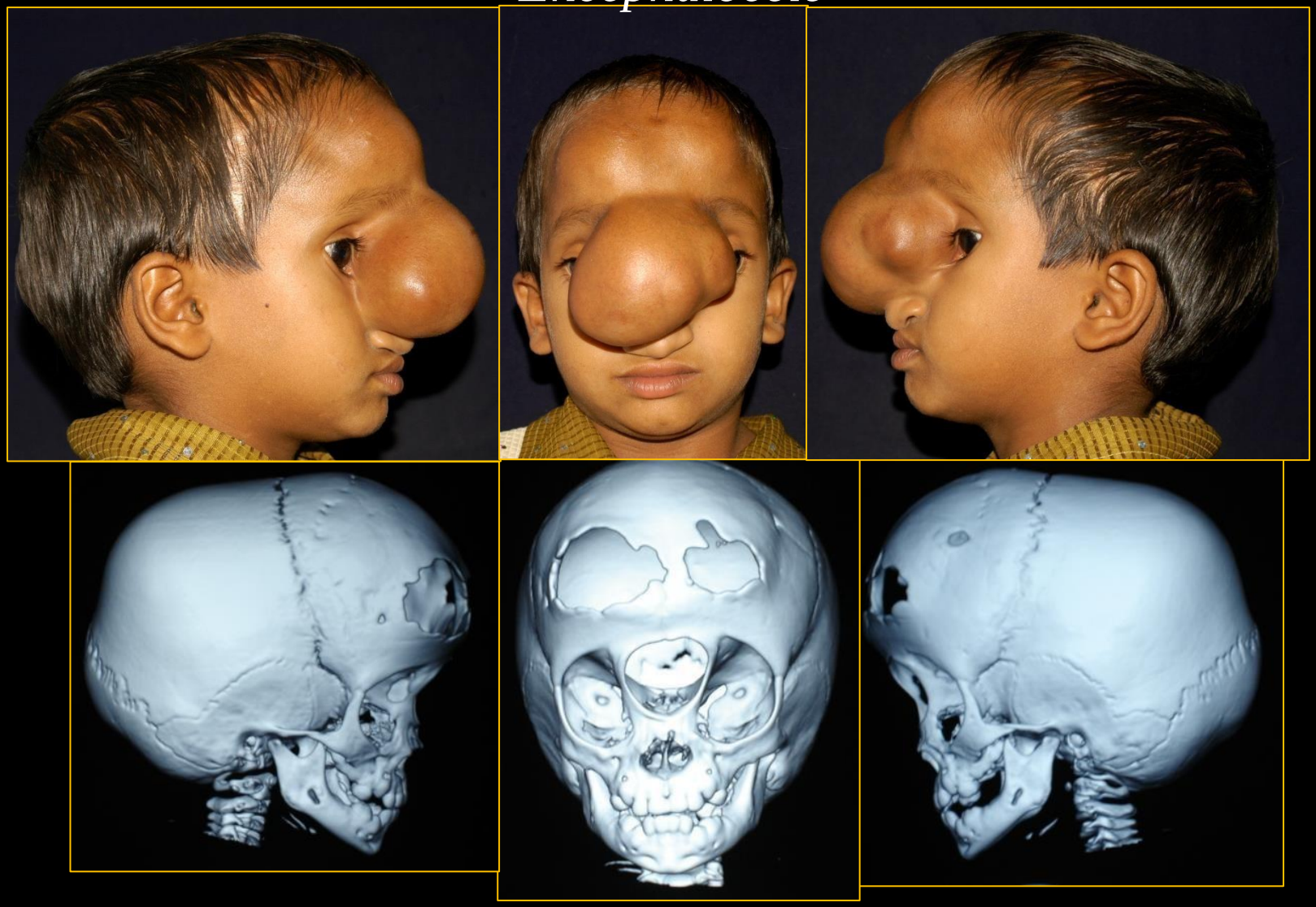

Orbital Hypertelorism: Treatment

Encephalocele

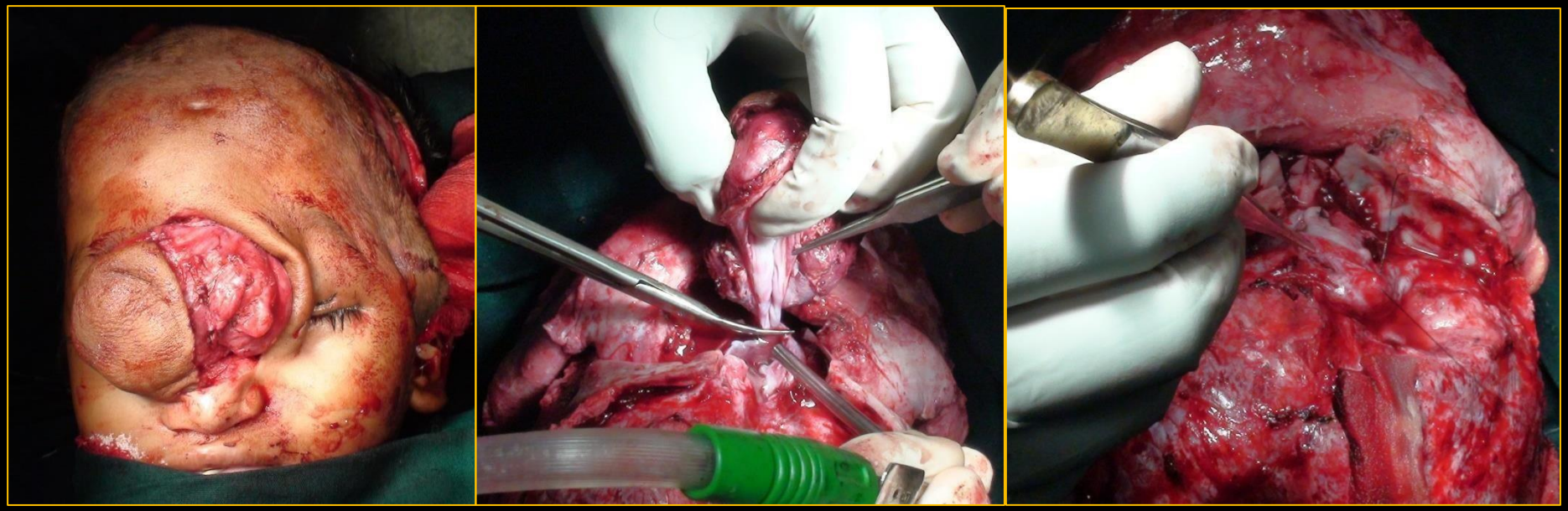

Encephalocele Resection

Orbital Hypertelorism: Treatment

Encephalocele

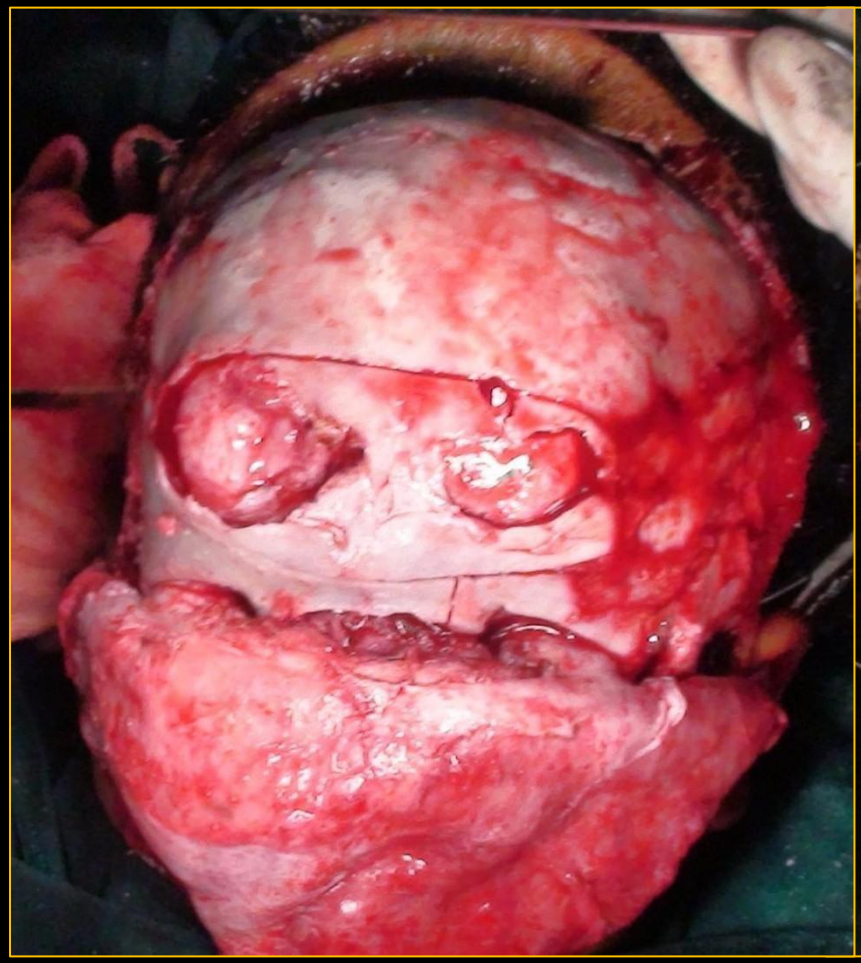

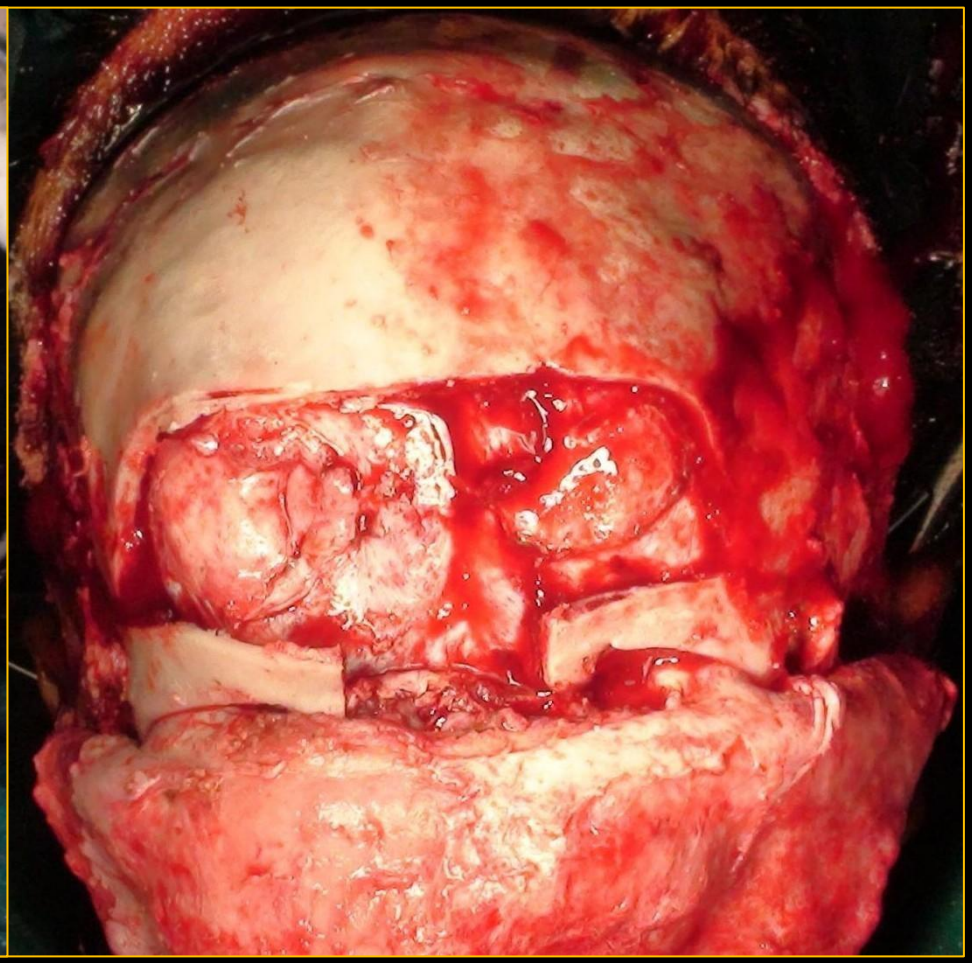

Transfrontal Craniotomy

Orbital Hypertelorism: Treatment

Encephalocele

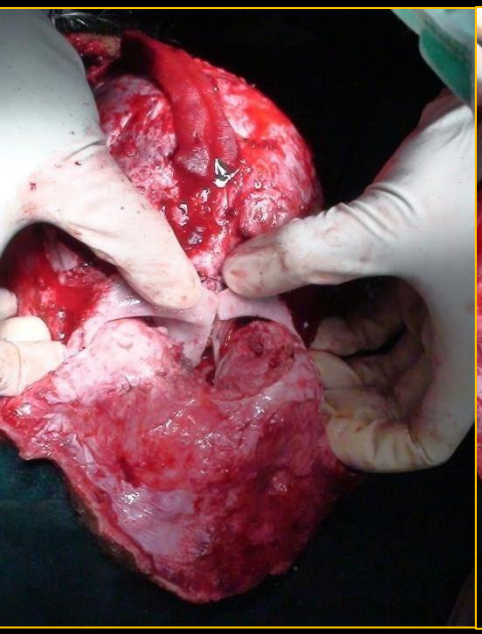

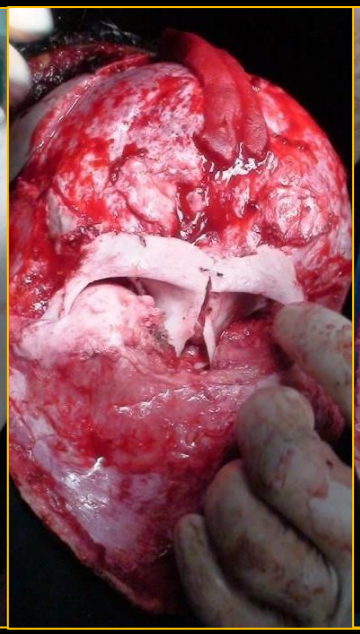

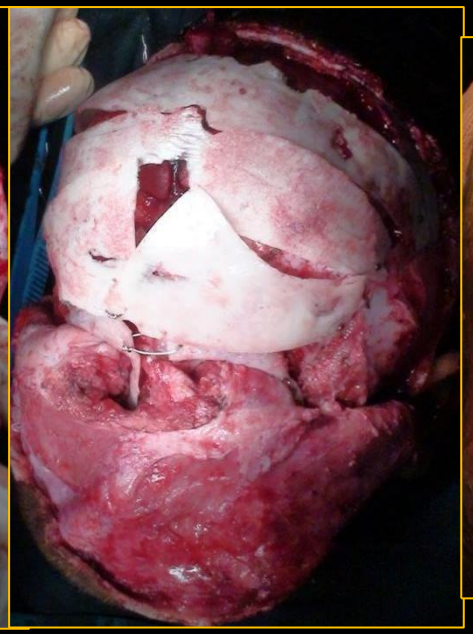

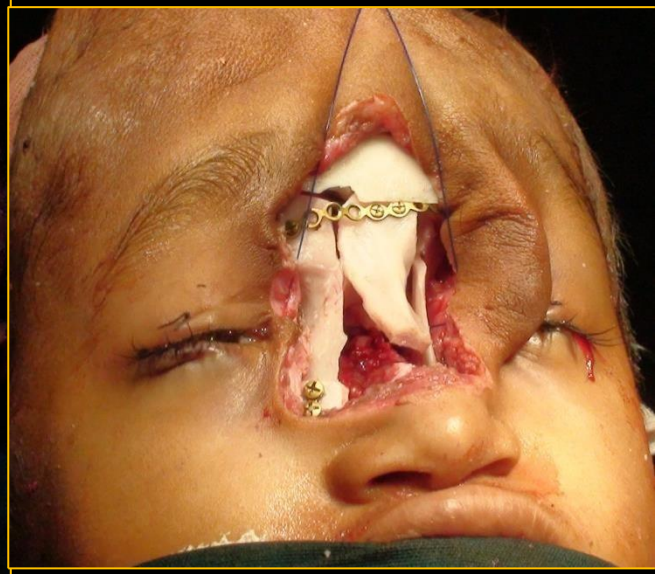

Finishing osteotomy, fixation and closure

Orbital Hypertelorism: Treatment

Encephalocele

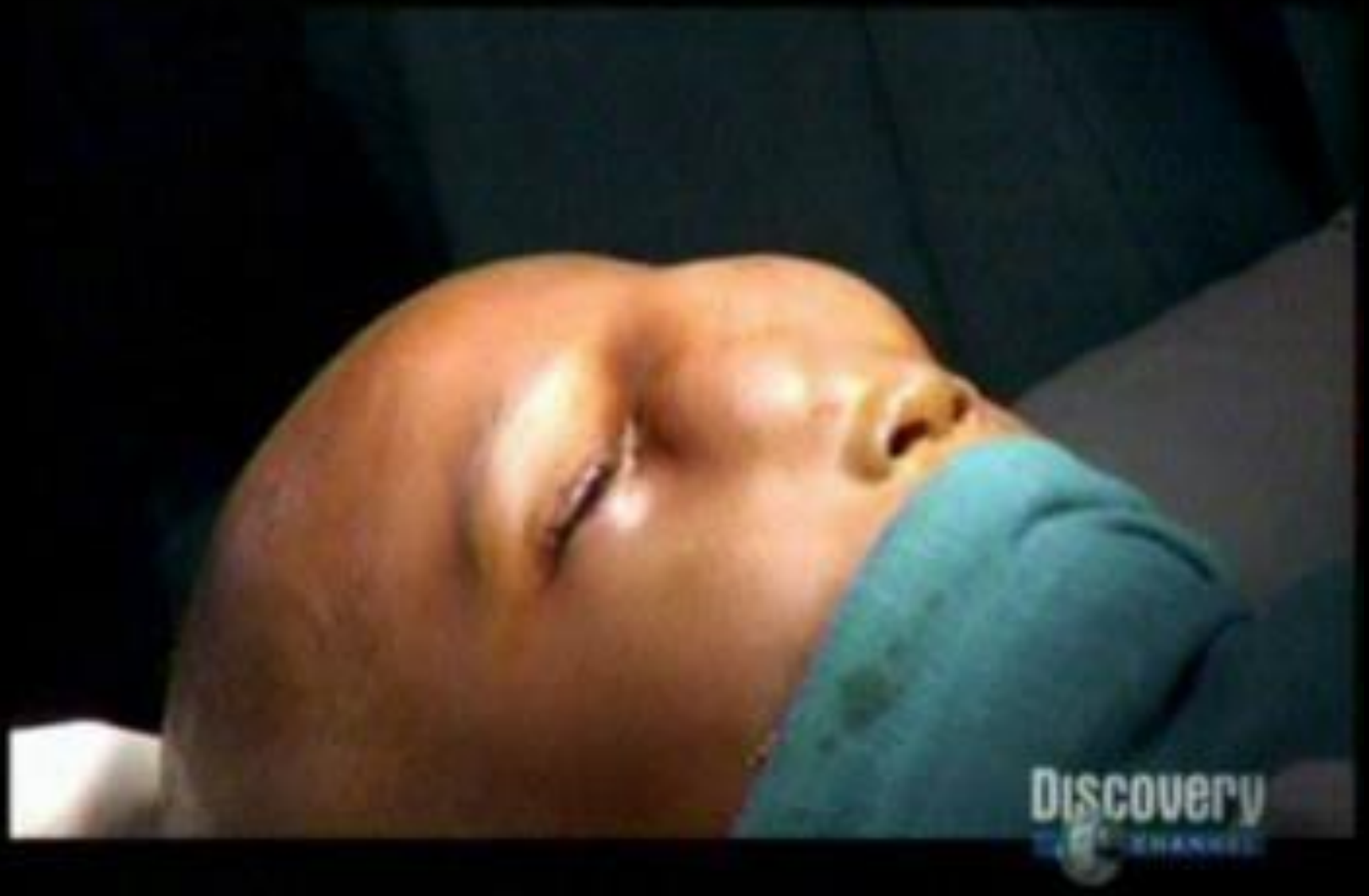

Orbital Hypertelorism: Treatment

Encephalocele

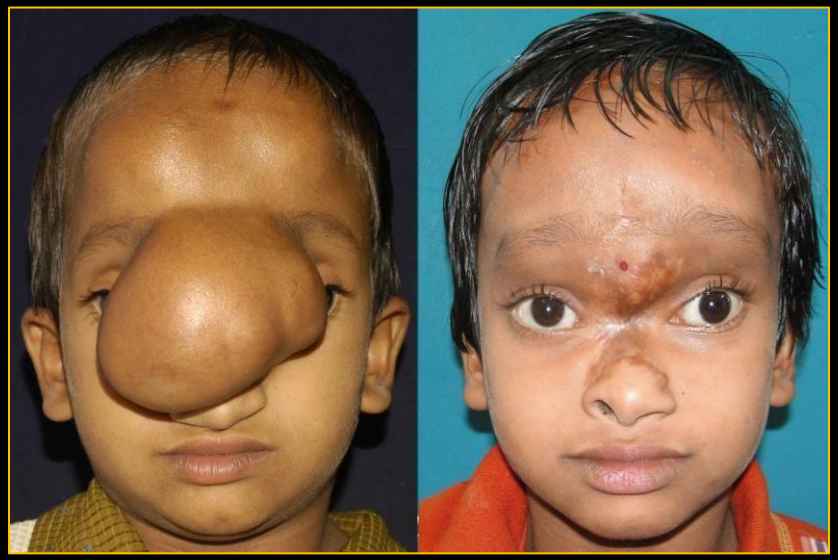

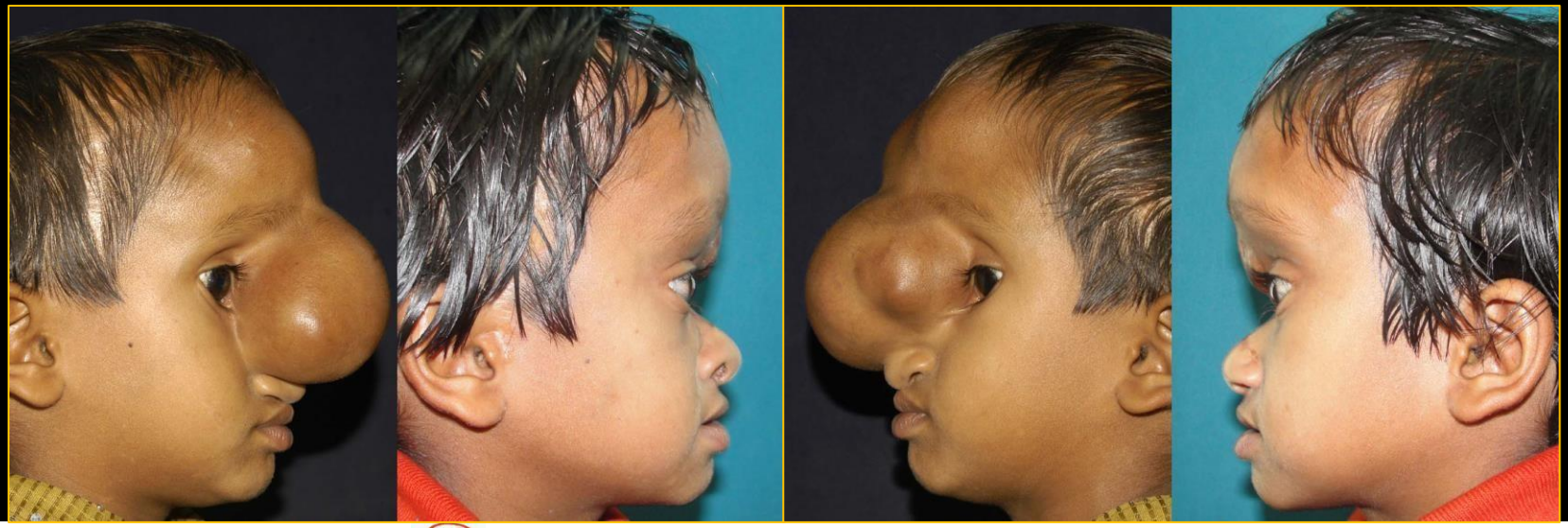

Spectacle Osteotomy

Orbital Hypertelorism: Treatment

Craniofrontonasal Dysplasia

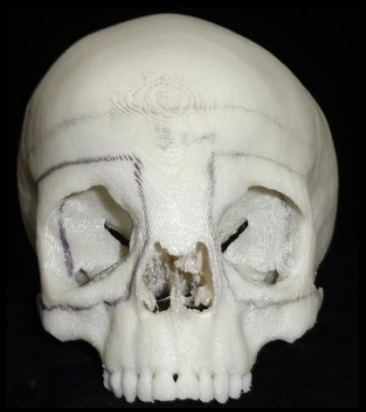

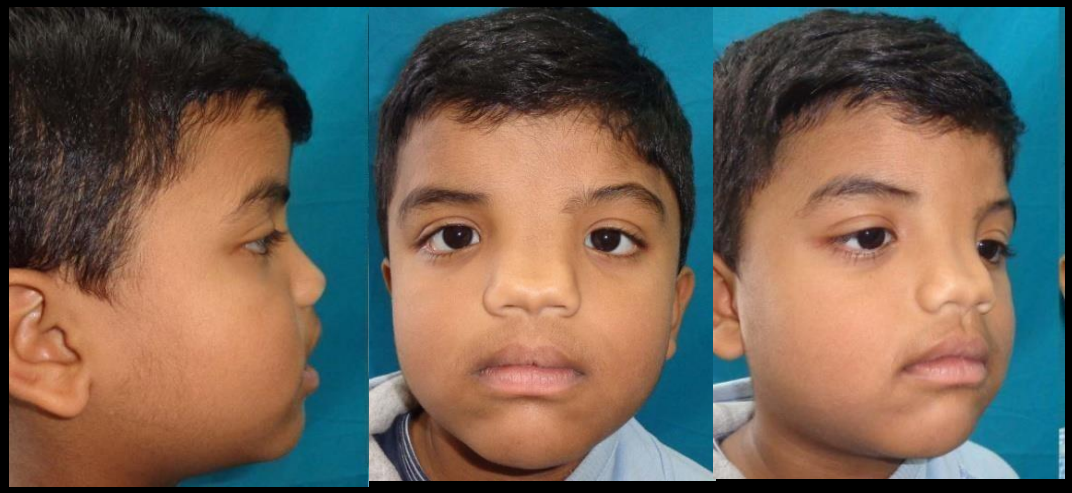

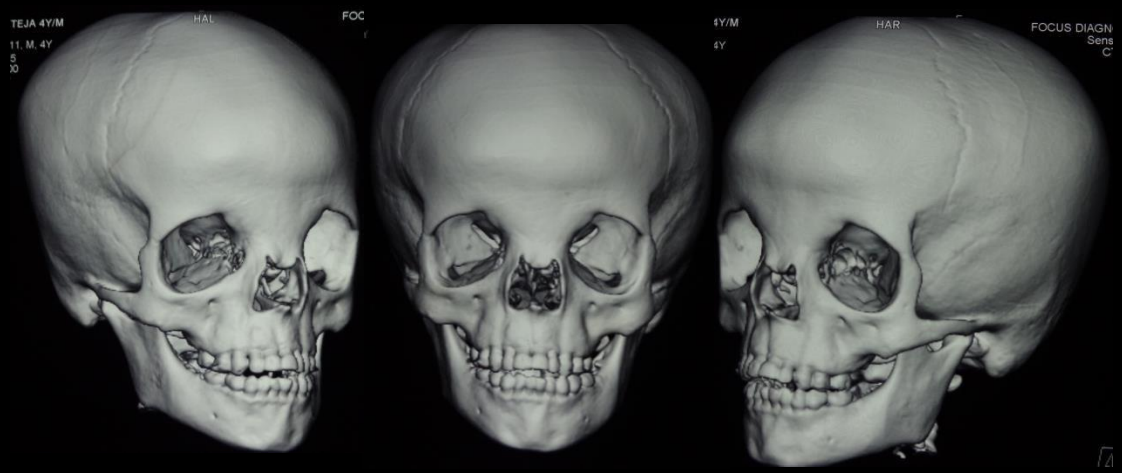

Orbital Hypertelorism: Treatment

Craniofrontonasal Dysplasia

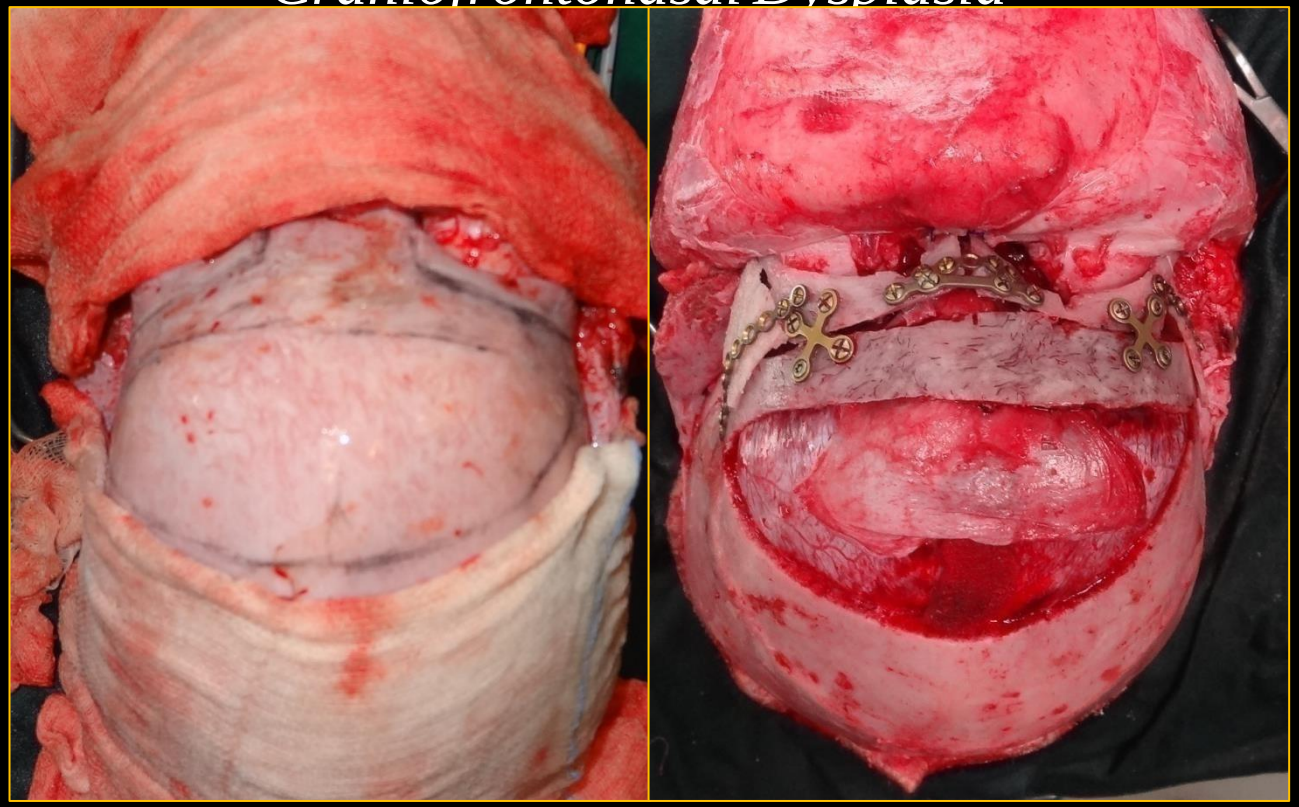

Transfrontal Craniotomy

- The frontal bar results from parallel osteotomies that are at least 1 cm from the supraorbital rims
- Permits orientation of the orbits once they have been mobilized

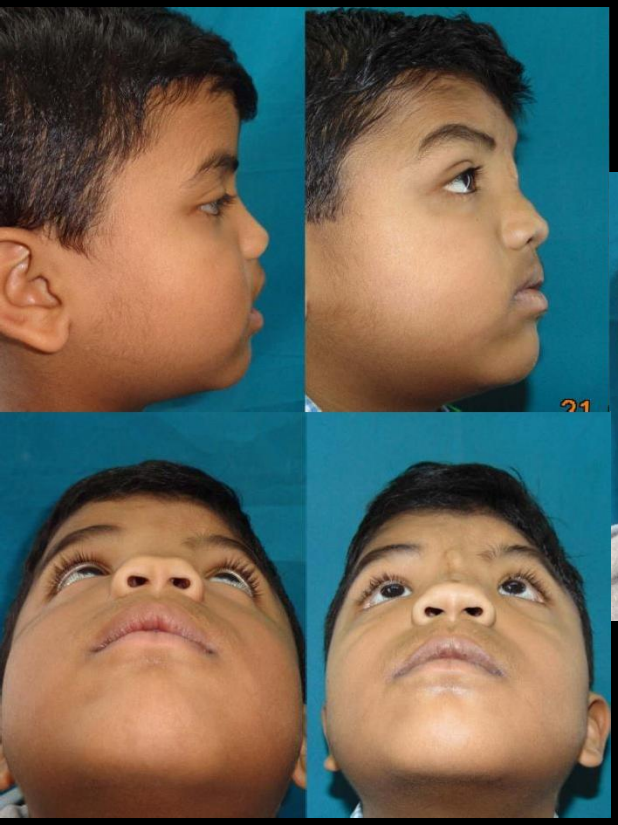

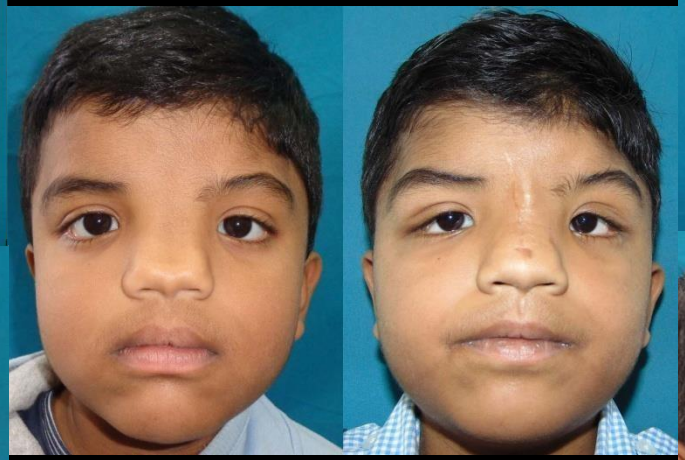

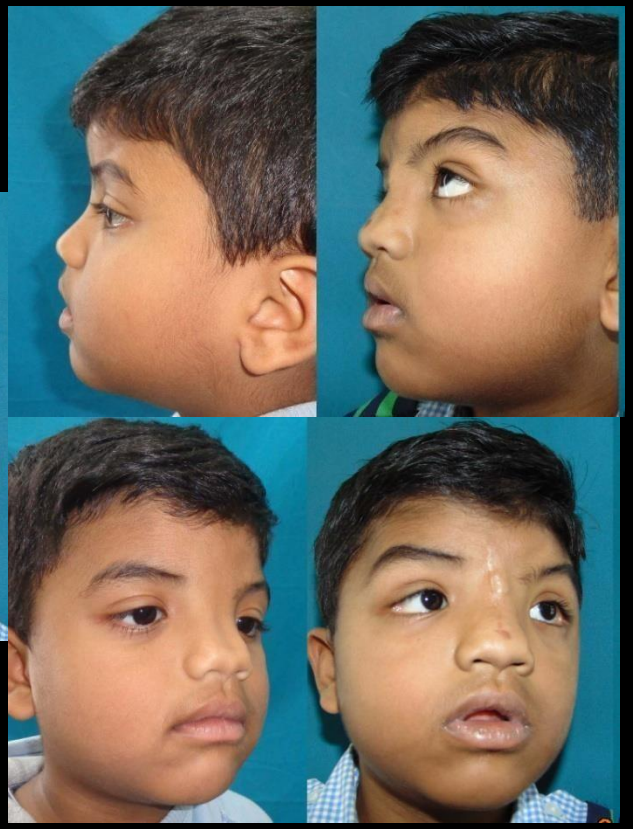

Facial Bipartition

Orbital Hypertelorism: Treatment

Craniosynostosis

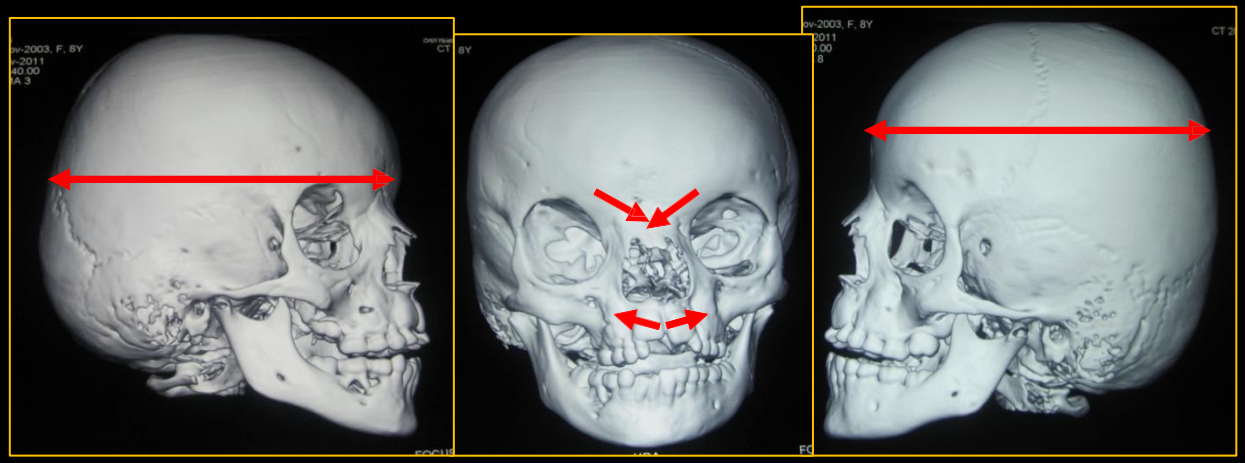

Orbital Hypertelorism: Treatment

Craniosynostosis

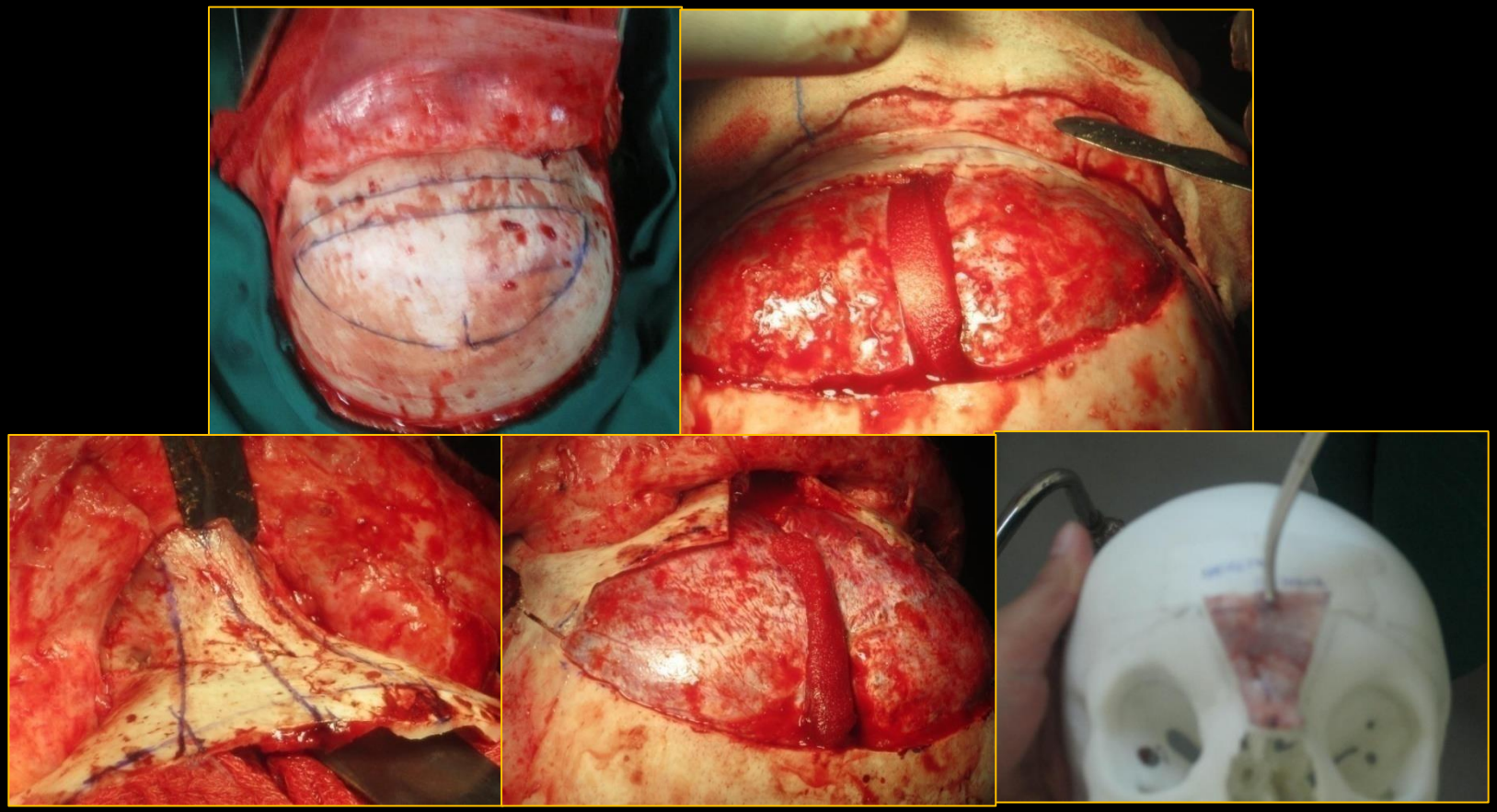

Frontal craniotomy

Orbital Hypertelorism: Treatment

Craniosynostosis

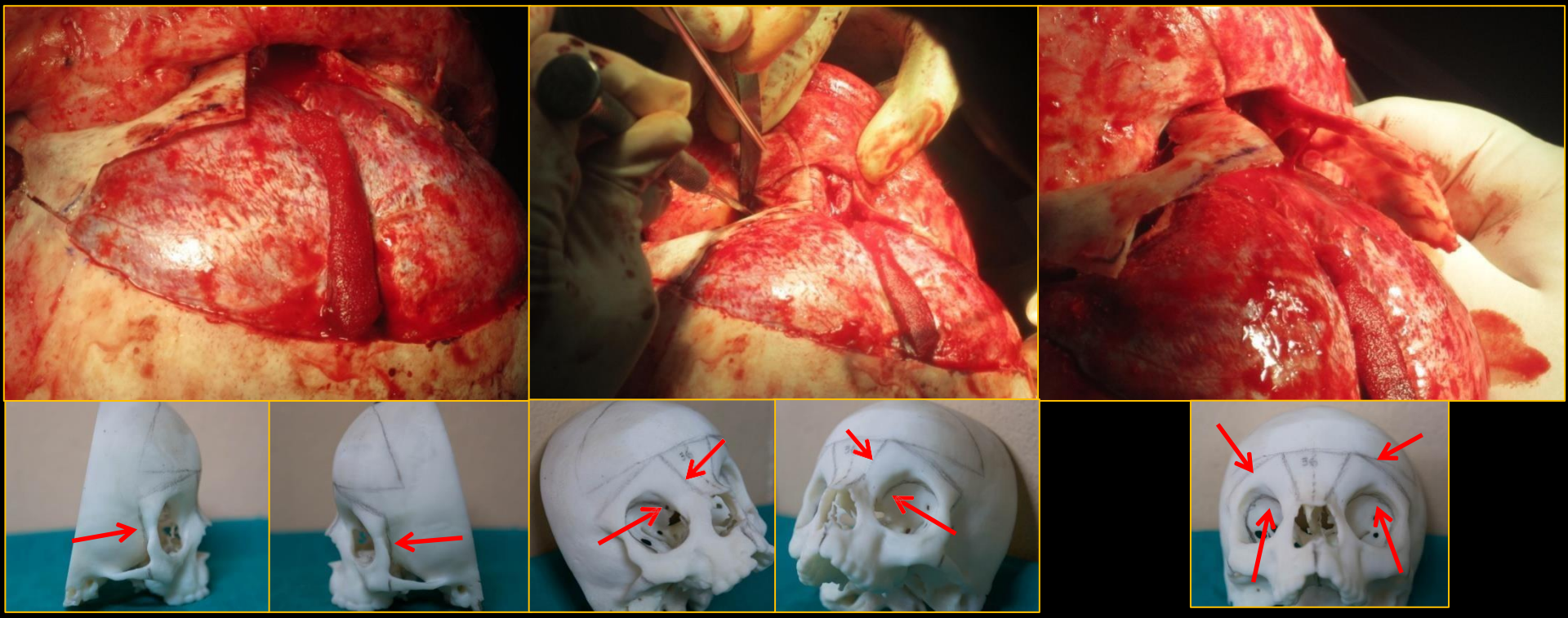

Lateral, Medial and Superior orbital osteotomies

- These osteotomies are done to separate the naso-orbital complex from the temporal and sphenoid bones and also the skull base
- Osteotomy is also done at the zygomatic bone.

Orbital Hypertelorism: Treatment

Craniosynostosis

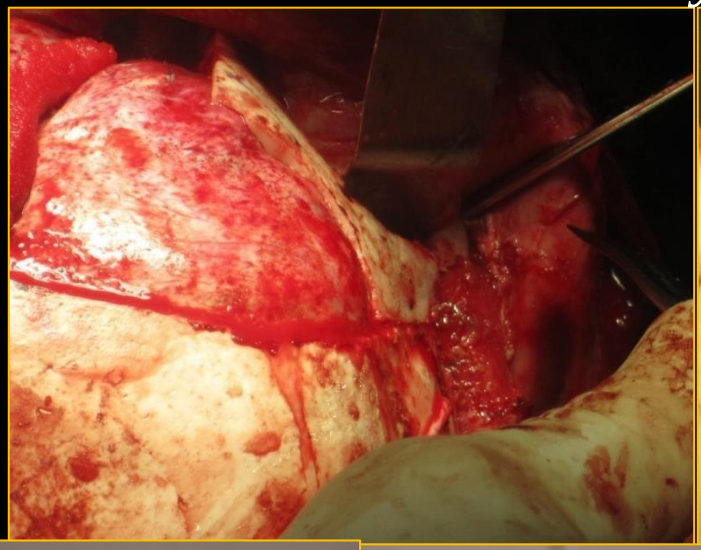

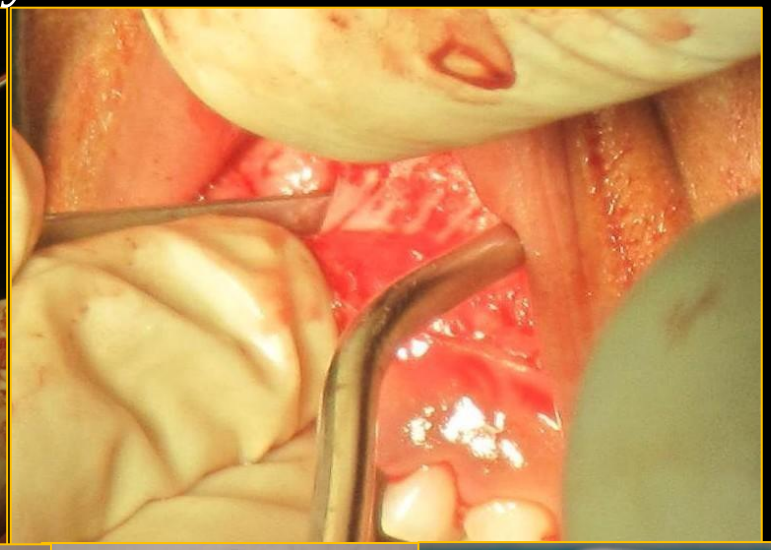

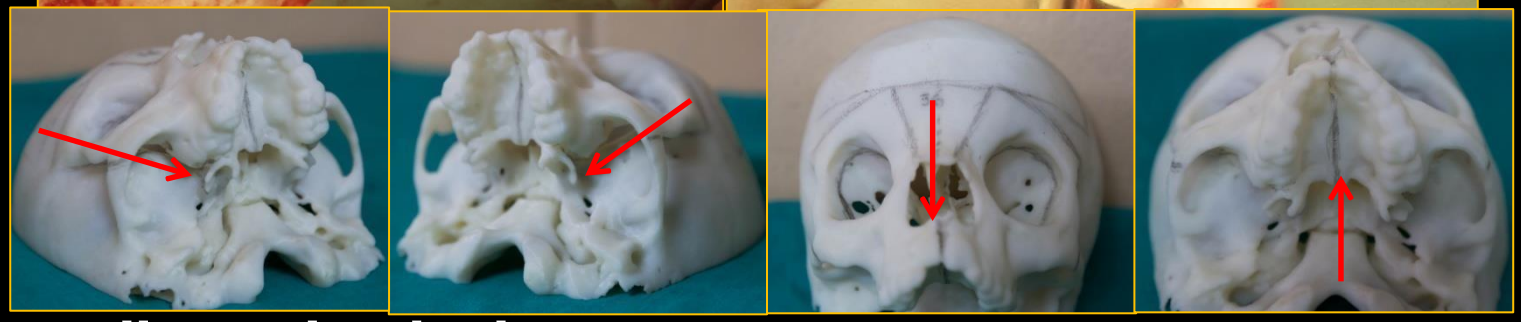

Pterygo-maxillary and mid palatine osteotomies

- Pterygo-maxillary osteotomy done to separate the zygomatico-maxillary complex from the pterygoid bone.
- Mid-palatine osetotomy is done to flatten the maxilla.

Orbital Hypertelorism: Treatment

Craniosynostosis

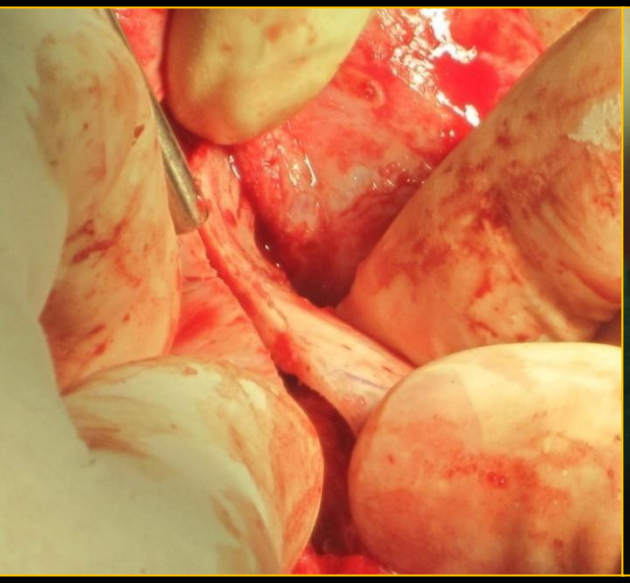
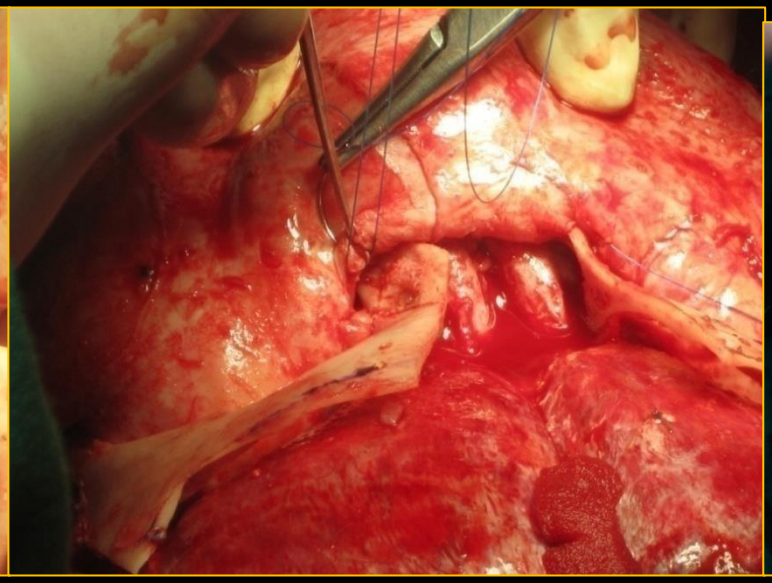
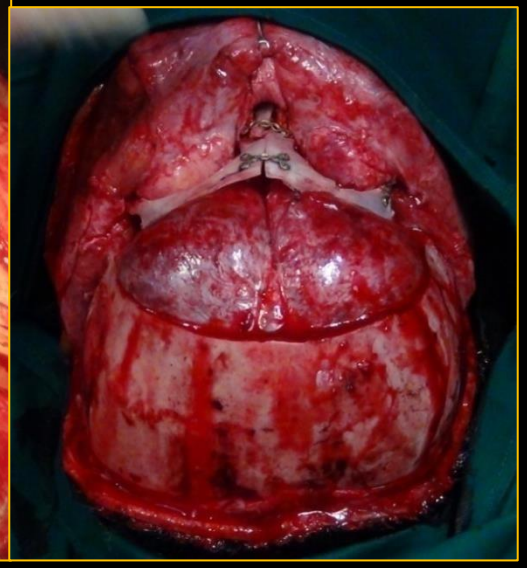

Approximation and fixation

- If the osteotomies are complete the segments will medialise with finger pressure
- Medial and lateral canthal ligaments are re-suspended
- Fixation is done

Orbital Hypertelorism: Treatment

Craniosynostosis

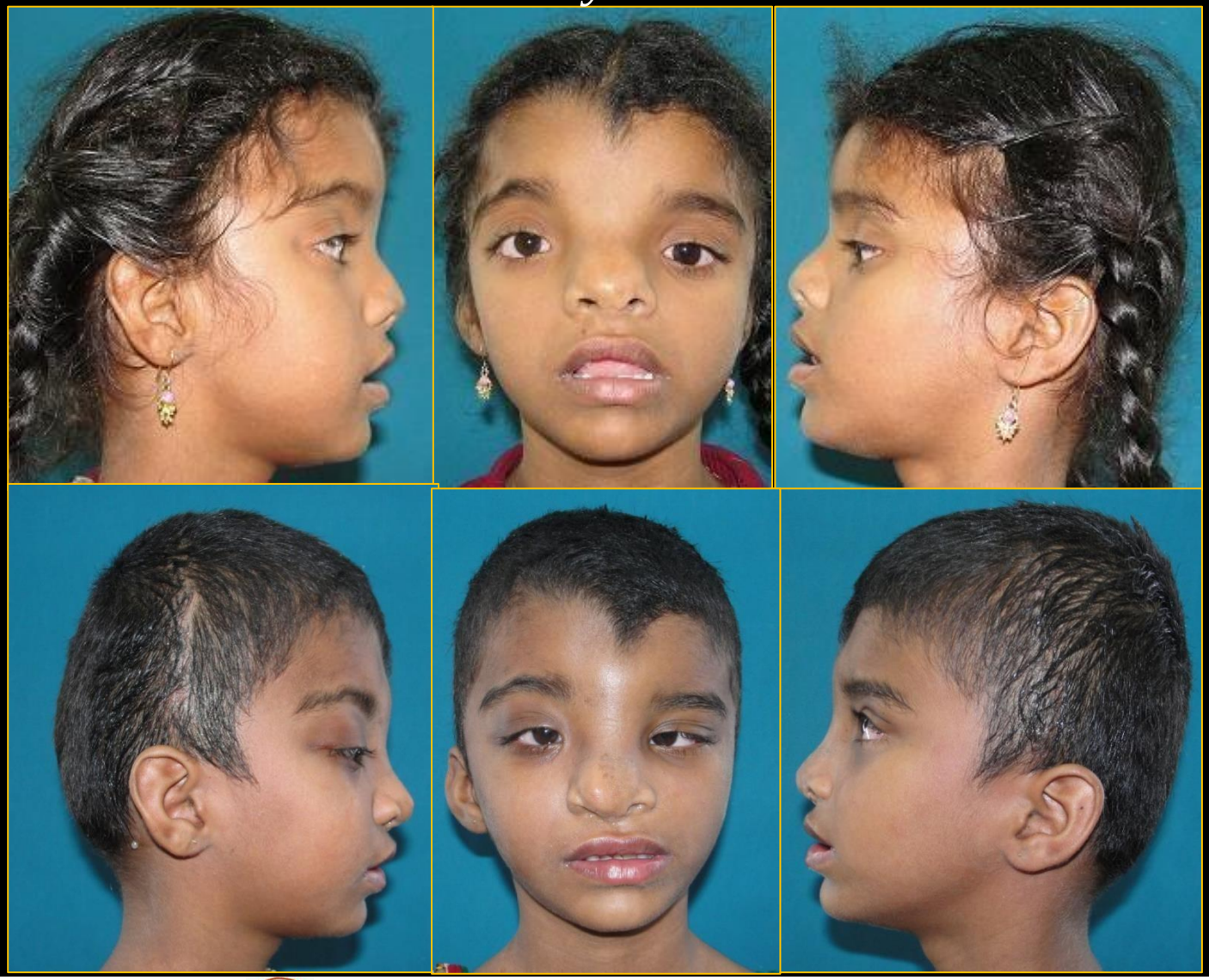

www.craniofacialinstitute.org

Orbital Hypertelorism: Treatment

Unilateral coronal Craniosynostosis(plagiocephaly)

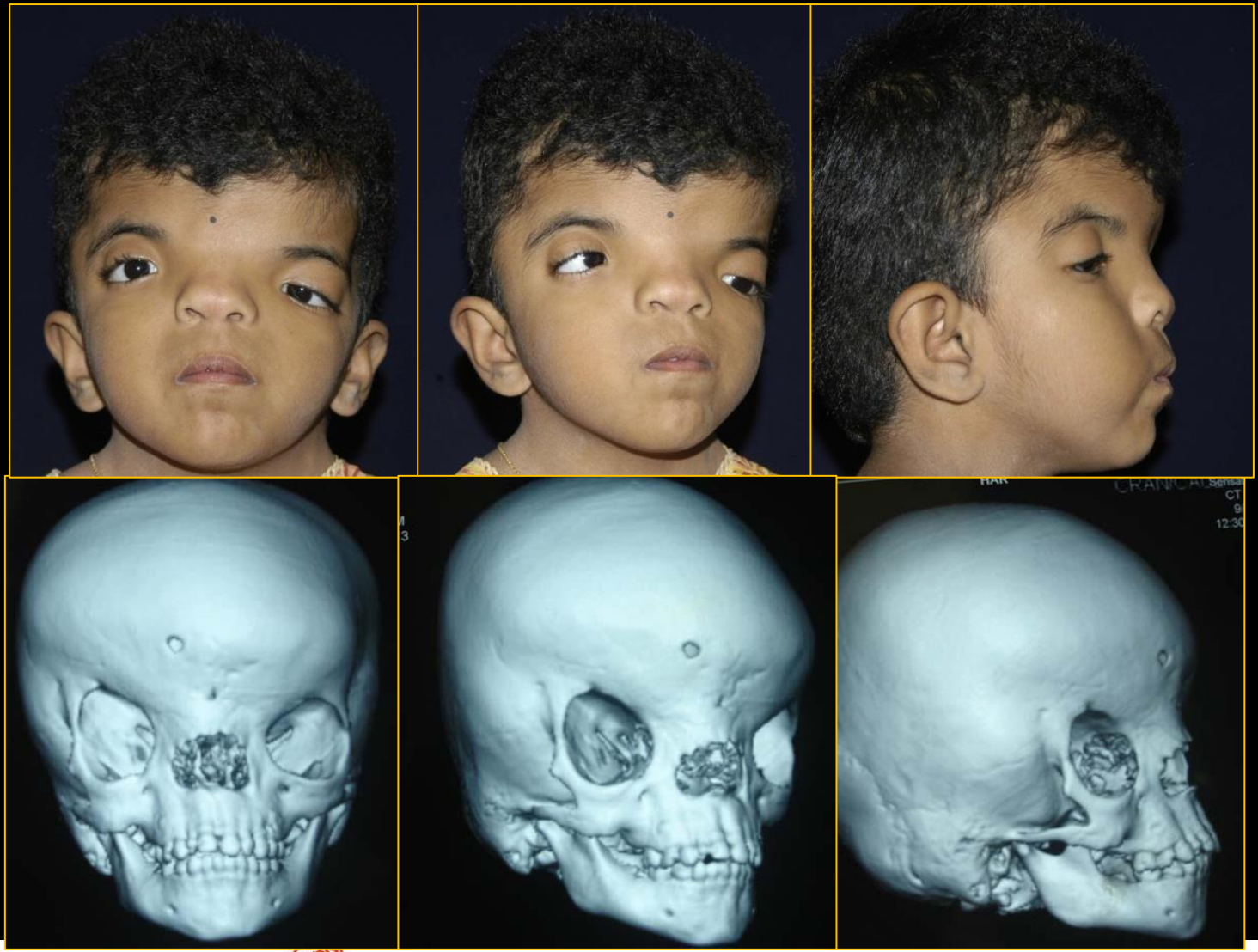

Orbital Hypertelorism: Treatment

Unilateral coronal Craniosynostosis(plagiocephaly)

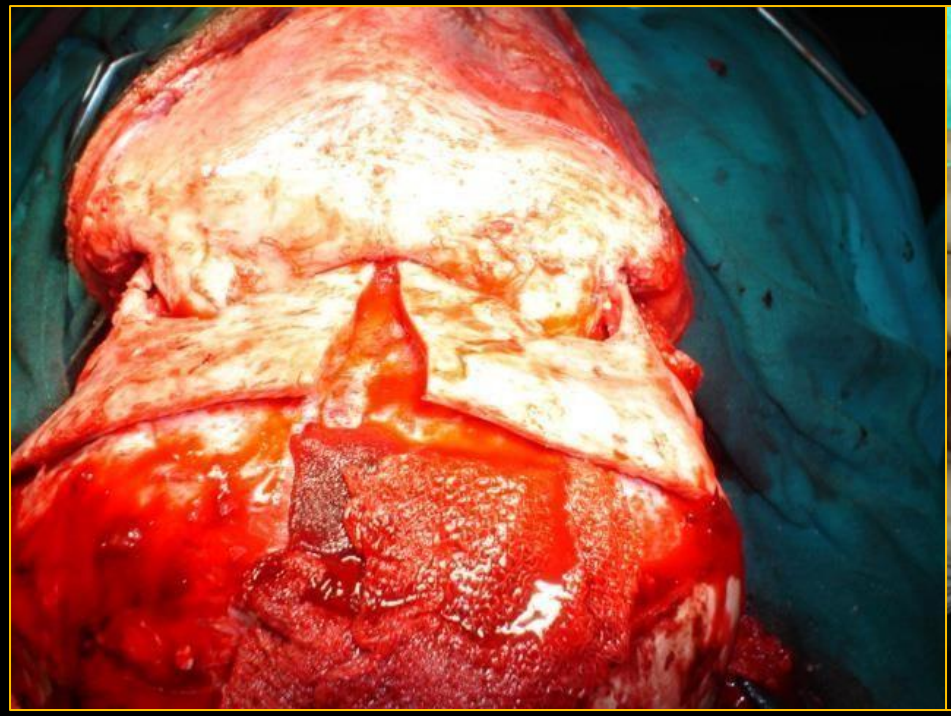

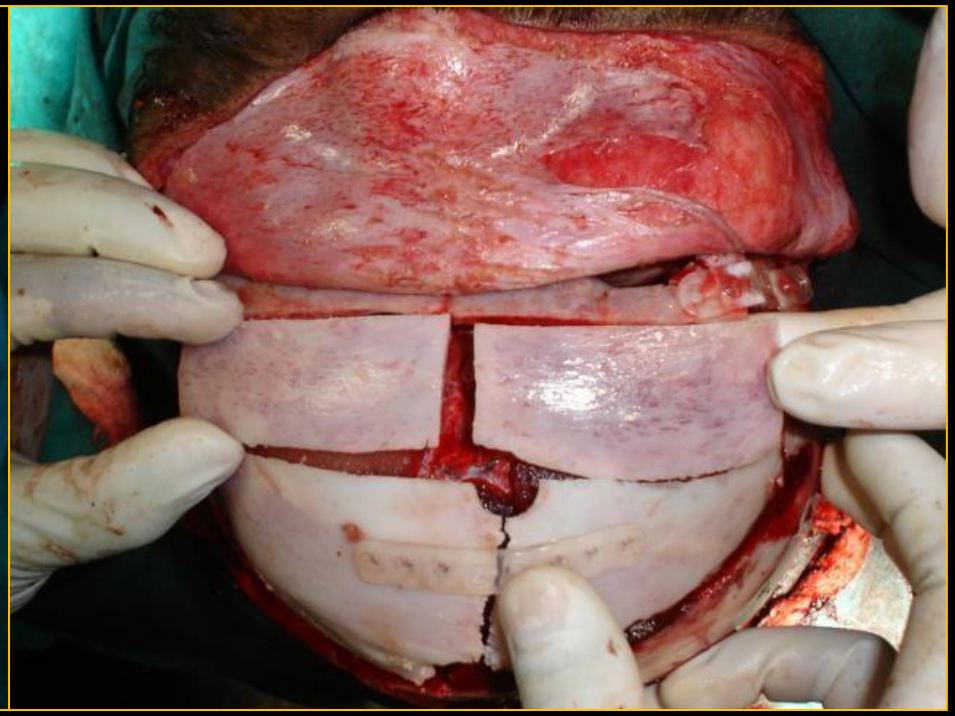

Facial Bipartition

- Right coronal Craniosynostosis release done along with facial bi-partition

Orbital Hypertelorism: Treatment

Unilateral coronal Craniosynostosis(plagiocephaly)

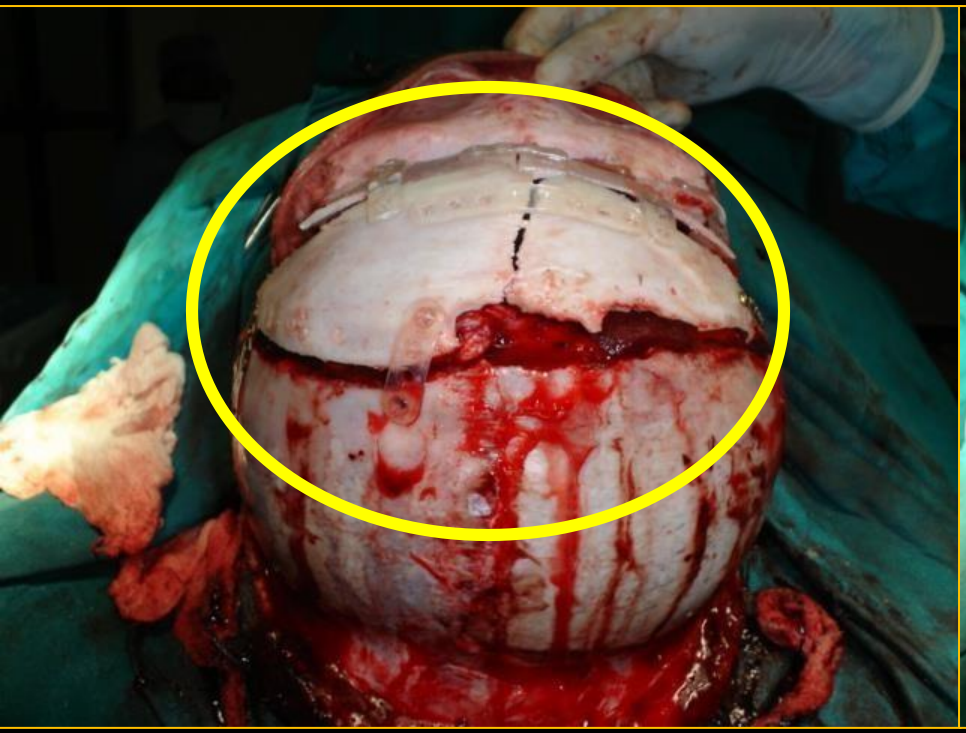

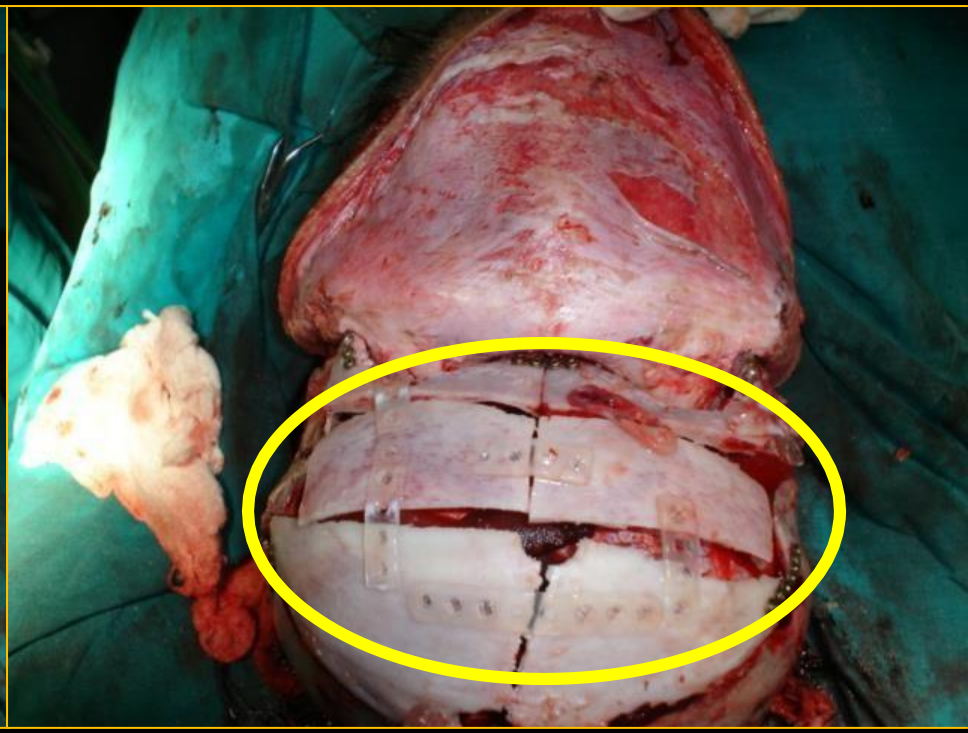

Fixation

- Cranial bone fixation after craniosynostosis release is done with bio-resorbable bone plates

Orbital Hypertelorism: Treatment

Unilateral coronal Craniosynostosis(plagiocephaly)

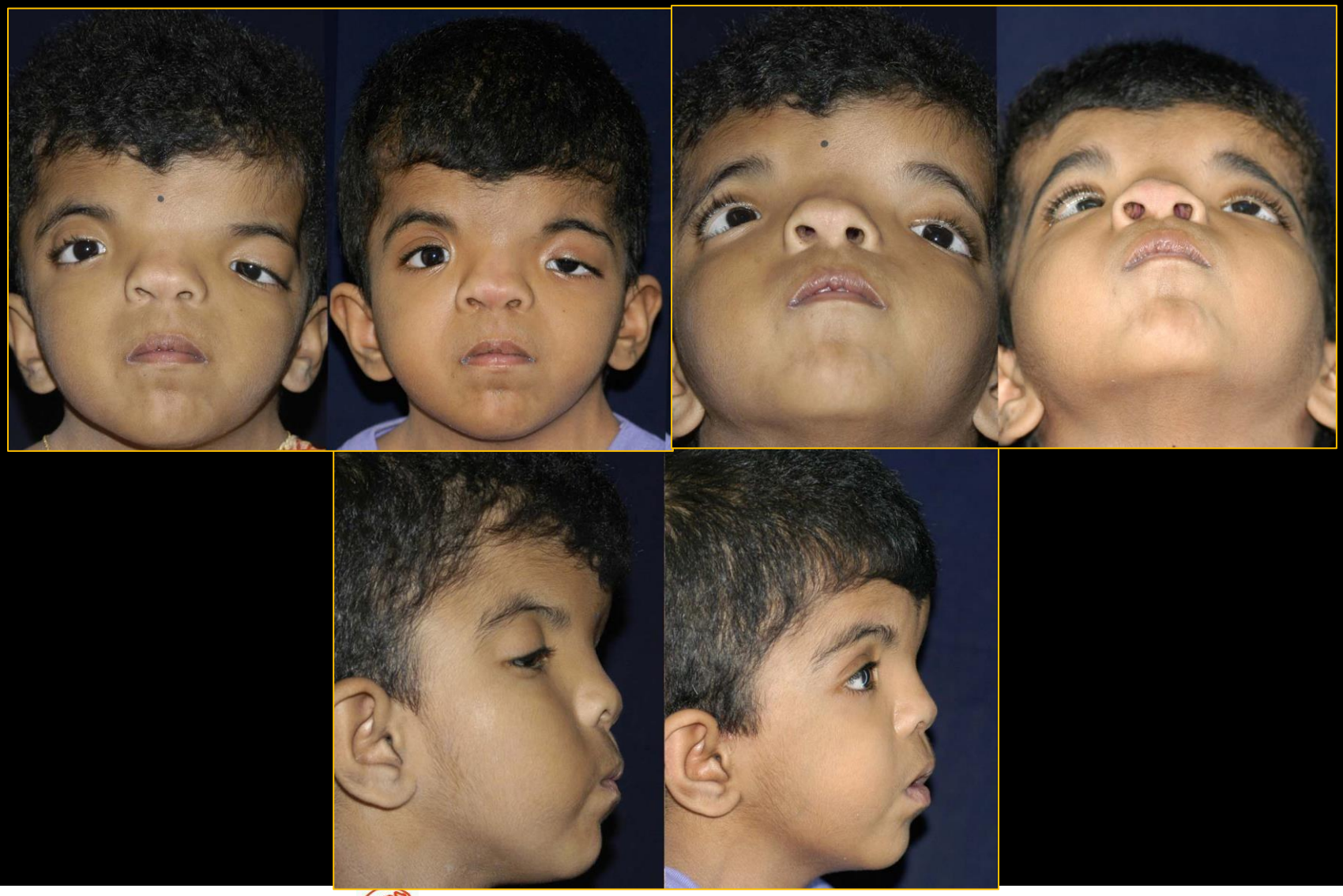

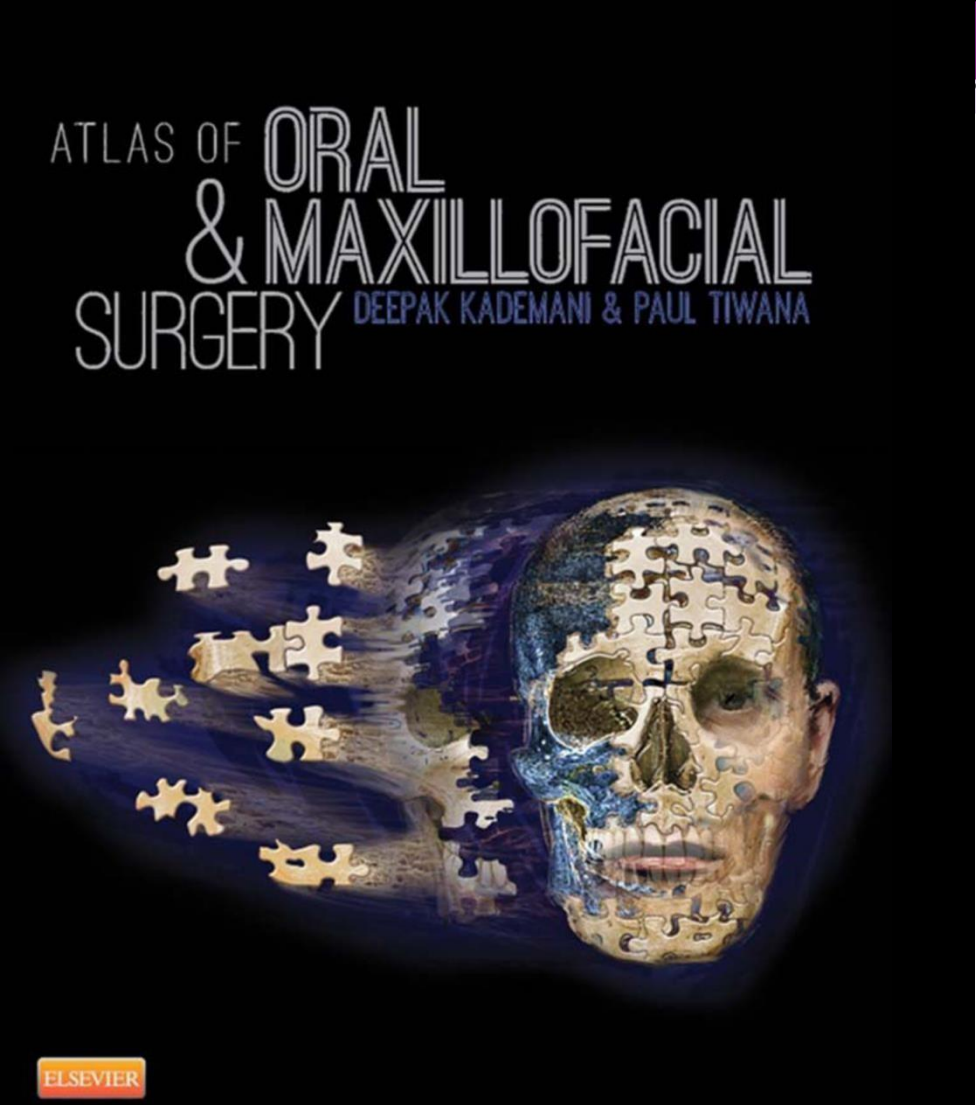

CHAPTER 47

Orbital Box Osteotomy

Likith Reddy and Srinivas Gosla

Armamentarium

- #15 and #10 scalpel blades and handle
- 24-Gauge wire
- Appropriate sutures
- Bipolar cautery
- Bone rongeurs
- Cottle, Freer, and #9 periosteal elevators
- Curved Mayo or curved tenotomy scissors
- Fine side-cutting fissure bur, 1.2 mm
- Hair clippers and hair elastics
- Local anesthetic with vasoconstrictor
- Malleable retractors
- Mayfield headrest
- Midface titanium fixation devices
- Needle electrocautery
- Obwegeser retractors
- Reciprocating saw
- Sewall retractors
- Smith spreaders
- Tessier osteotomes

History of the Procedure

The orbital box osteotomies are used to correct vertical or horizontal malposition of the entire orbit and its contents. The orbital box osteotomy was first performed by Paul Tessier to correct hypertelorism.[1] He described osteotomies that separate the entire bony orbit from the skull and surrounding facial bones by combining both intracranial and facial approaches.[1,2] Converse and Smith described subcranial U-shaped orbital osteotomies to correct hypertelorism; however, these techniques produced limited results.[3] Schmid described circumferential orbital osteotomies to mobilize and translocate the orbits medially by an extracranial approach in patients with pneumatized frontal sinuses.[4]

Indications for the Use of the Procedure

The orbital box osteotomy is used to correct malpositions of the zygoma, orbit, and its contents in all planes.[5] It is primarily indicated to correct hypertelorism.[6] However, the box osteotomy can be used to correct vertical or horizontal dystopia due to congenital, pathologic, or traumatic abnormalities.[7]

Orbital hypertelorism is an abnormally increased distance between the orbits. In this condition, the distance between the medial canthi, medial, and lateral walls of the orbit and the pupils is greater than normal. This is different from telecanthus, where the distance between the medial canthi is greater than normal and the distance between lateral walls of the orbit and pupils is normal (Figure 47-1).

Orbital hypertelorism is an anatomic condition associated with a heterogeneous group of congenital disorders. This can occur as an isolated sporadic anomaly or with conditions such as Edwards syndrome (trisomy 18), basal cell nevus syndrome, craniofrontonasal dysplasia, DiGeorge syndrome, Apert syndrome, and Crouzon syndrome. A heterogeneous collection of frontonasal malformations[8] is the group that most commonly displays hypertelorism (Figure 47-2). The clinical findings in this group are usually symmetric hypertelorism, exaggerated widow's peak onto the forehead, abnormal and wide-set eyebrows, down-slanting eyes, epicanthic folds, amblyopia, strabismus, a wide nose with a short philtrum, increased intrazygomatic distance, lateral and inferior positioned zygomas, median cleft lip, and a high arched palate.[8-10] Other congenital conditions associated with hypertelorism are frontal encephaloceles, craniofacial clefts, and craniofrontonasal dysplasia[11,12] (Figure 47-3).

The other pathologic process for orbital dystopia is a slow-growing tumor such as neurofibromatosis, frontal sinus mucocele, and the like. Also, some of the high-energy injuries or inadequate corrections can cause orbital dystopia in vertical or horizontal positions (Figure 47-4).

The surgery to correct hypertelorism is usually done when the patient is between 5 and 8 years of age. This timing addresses the psychosocial aspects of the developing child in the early school years. The physiologic reasons include the fact that the majority of the interzygomatic width is established by 6 years of age and there is adequate descent of tooth buds into the maxilla, giving space to make an osteotomy below the infraorbital nerve. The disadvantages are that the orbital bones before 5 years of age are thin and fragile and

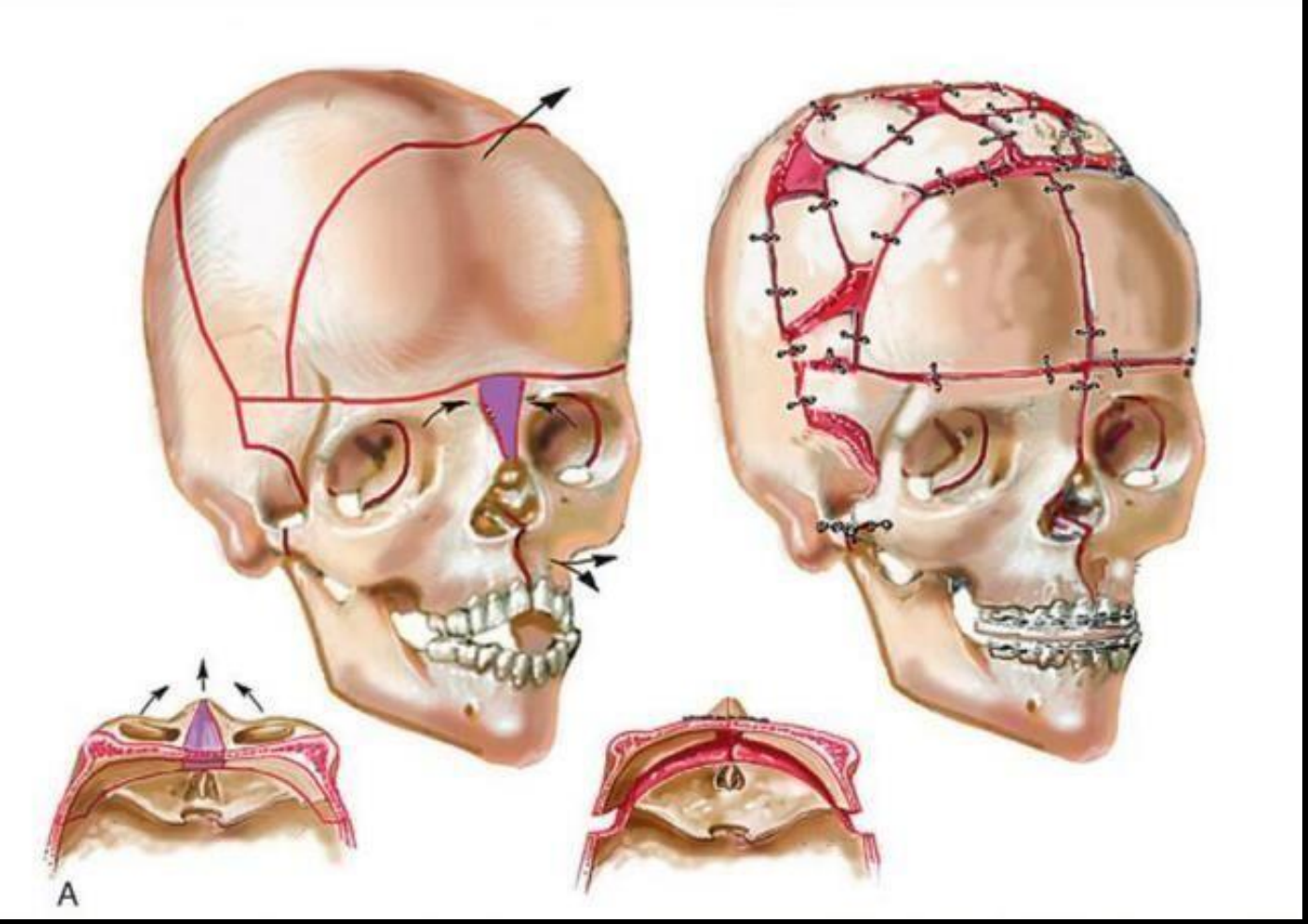

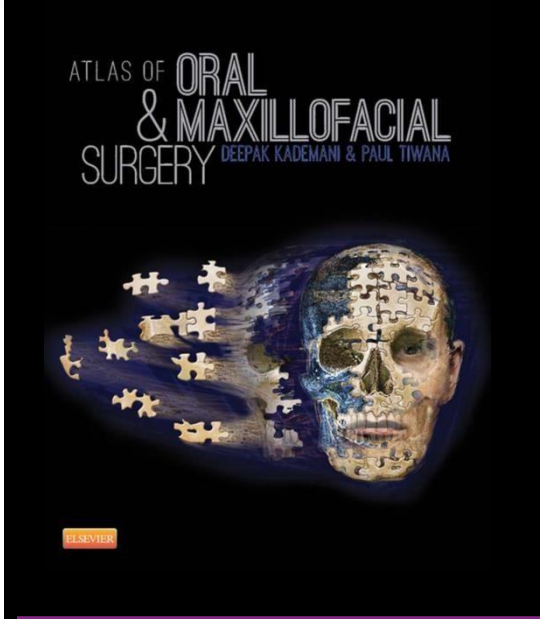

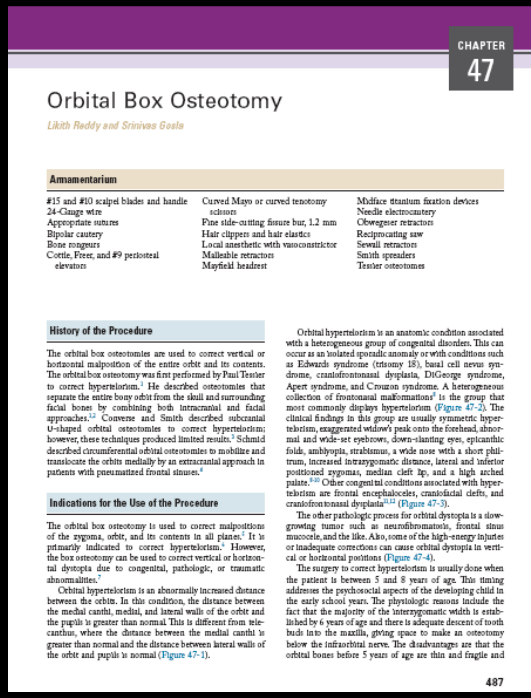

CHAPTER 47

Orbital Box Osteotomy

Likith Reddy and Srinivas Gosla

Armamentarium

#15 and #10 scalpel blades and handle
24-Gauge wire
Appropriate sutures
Bipolar cautery
Bone rongeurs
Cottle, Freer, and #9 periosteal elevators
Curved Mayo or curved tenotomy scissors
Fine side-cutting fissure bur, 1.2 mm
Hair clippers and hair elastics
Local anesthetic with vasoconstrictor
Malleable retractors
Mayfield headrest
Midface titanium fixation devices
Needle electrocautery
Obwegeser retractors
Reciprocating saw
Sewall retractors
Smith spreaders
Tessier osteotomes

History of the Procedure

The orbital box osteotomies are used to correct vertical or horizontal malposition of the entire orbit and its contents. The orbital box osteotomy was first performed by Paul Tessier to correct hypertelorism.[1] He described osteotomies that separate the entire bony orbit from the skull and surrounding facial bones by combining both intracranial and facial approaches.[1,2] Converse and Smith described subcranial U-shaped orbital osteotomies to correct hypertelorism; however, these techniques produced limited results.[3] Schmid described circumferential orbital osteotomies to mobilize and translocate the orbits medially by an extracranial approach in patients with pneumatized frontal sinuses.[4]

Indications for the Use of the Procedure

The orbital box osteotomy is used to correct malpositions of the zygoma, orbit, and its contents in all planes.[5] It is primarily indicated to correct hypertelorism.[5] However, the box osteotomy can be used to correct vertical or horizontal dystopia due to congenital, pathologic, or traumatic abnormalities.[5]

Orbital hypertelorism is an abnormally increased distance between the orbits. In this condition, the distance between the medial canthi, medial, and lateral walls of the orbit and the pupils is greater than normal. This is different from telecanthus, where the distance between the medial canthi is greater than normal and the distance between lateral walls of the orbit and pupils is normal (Figure 47-1).

Orbital hypertelorism is an anatomic condition associated with a heterogeneous group of congenital disorders. This can occur as an isolated sporadic anomaly or with conditions such as Edwards syndrome (trisomy 18), basal cell nevus syndrome, craniofrontonasal dysplasia, DiGeorge syndrome, Apert syndrome, and Crouzon syndrome. A heterogeneous collection of frontonasal malformations[6] is the group that most commonly displays hypertelorism (Figure 47-2). The clinical findings in this group are usually symmetric hypertelorism, exaggerated widow's peak onto the forehead, abnormal and wide-set eyebrows, down-slanting eyes, epicanthic folds, ambiopia, strabismus, a wide nose with a short philtrum, increased intrazygomatic distance, lateral and inferior positioned zygomas, median cleft lip, and a high arched palate.[7,8] Other congenital conditions associated with hypertelorism are frontal encephalocoles, craniofacial clefts, and craniofrontonasal dysplasia[9,10] (Figure 47-3).

The other pathologic process for orbital dystopia is a slow-growing tumor such as neurofibromatosis, frontal sinus mucocele, and the like. Also, some of the high-energy injuries or inadequate corrections can cause orbital dystopia in vertical or horizontal positions (Figure 47-4).

The surgery to correct hypertelorism is usually done when the patient is between 5 and 8 years of age. This timing addresses the psychosocial aspects of the developing child in the early school years. The physiologic reasons include the fact that the majority of the interzygomatic width is established by 6 years of age and there is adequate descent of tooth buds into the maxilla, giving space to make an osteotomy below the infraorbital nerve. The disadvantages are that the orbital bones before 5 years of age are thin and fragile and

487

Courtesy :
Dr Srinivas Gosla Reddy, Dr Likith Reddy
Kademani D, Tiwana P.Atlas of Oral and Maxillofacial Surgery , Elsevier Health Sciences - US; 1 edition. 2015

Post operative Complications

Common postoperative problems and complications specific to this challenging surgery include

- relapse,
- canthal drift,
- enopthalmos,
- injury to the nasolacrimal apparatus,
- disappointing aesthetics with an unnatural appearance of the upper face.

Post operative Complications

- Injuries to cranial nerves
- Brain injury
- Injury to blood vessels
- Eye injuries
- Postoperative infections
- Dural tears
- Cardiopulmonary complications

Bring the Smile Back

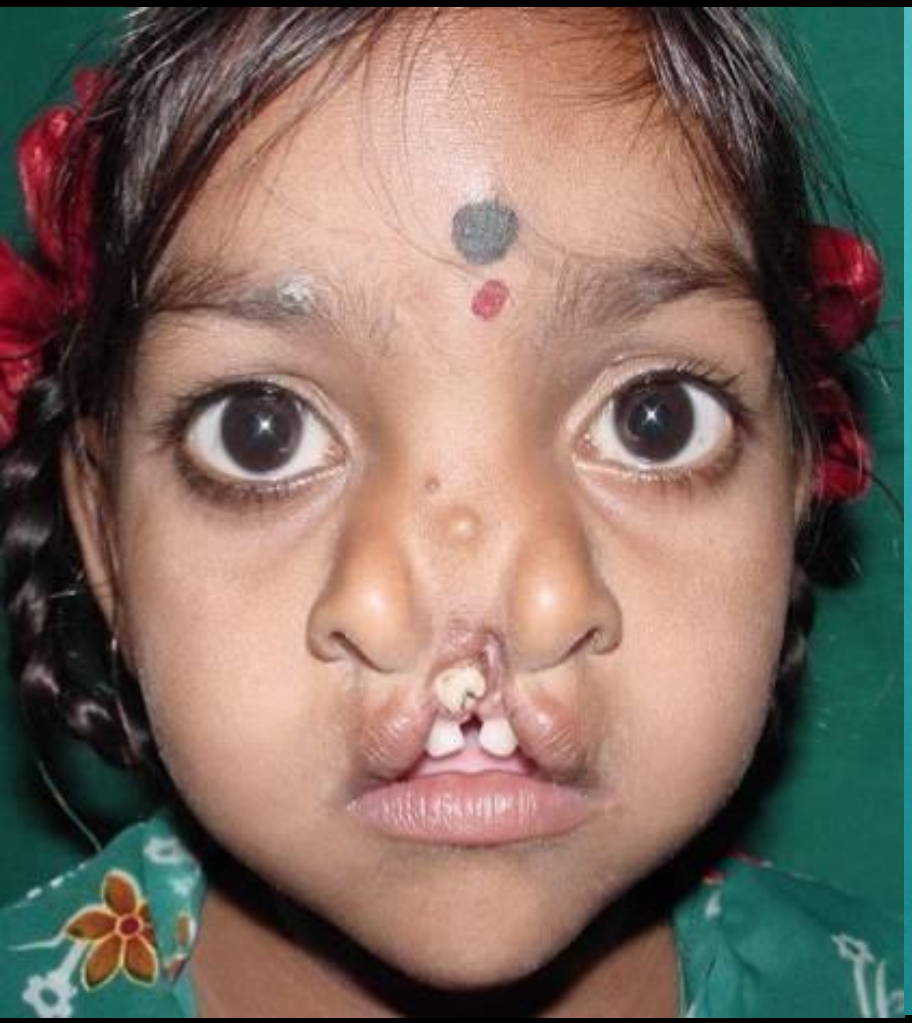

Thank You

www.craniofacialinstitute.org