

SECONDARY ALVEOLAR BONE GRAFTING

Prof. Dr. Dr. Srinivas Gosla Reddy

MBBS, MDS, FRCS (Edin.), FDSRCS (Edin), FDSRCS (Eng.), PhD

Dr. Rajgopal R. Reddy

MBBS, BDS, FDSRCPS (Glasg.), PhD

Dr. Ashish Fanan M.D.S

Dr. Avni Pandey M.D.S.

Dr. Madhav Thumati M.D.S

**GSR Institute of Craniofacial Surgery,
Hyderabad India**



www.craniofacialinstitute.org

Clefting of the alveolus is a less obvious component of the cleft defect; this has resulted in a paucity of ancient historical references to alveolar cleft repair.

It has been only in the not so distant past that pioneers have been successful with alveolar cleft repair.



The Past



- The **first** reported case of bone grafting to the alveolus is by **Von Eiselberg** - he used **pedicled osteocutaneous flap** to cover the **palatal defect**
- The first successful bone graft to an alveolar defect was by Drachter in 1914 - he utilized **tibial bone graft** with periosteum.

The Era of “Early Bone Grafting” - Primary bone grafting

In 1962 a group of surgeons and orthodontists proposed “**early bone grafting**”

- The authors believed that - the **alveolar cleft** was a **bridge** between the **retruded cleft side** and **growth promoting septum** on the non cleft side
- The early bridging of alveolus would allow for normal growth of cleft side
- This approach of “**early bone grafting**” continued **throughout 1970s**

Coots BK. Alveolar bone grafting: past, present, and new horizons. Semin Plast Surg. 2012 Nov;26(4):178-83.



The Present



- Since 1964 many publications have been suggesting that **grafting at this early stage causes serious growth disturbances** of the middle third of the facial skeleton.
- Though very few centers still perform early bone grafting it's a has been abandoned in most centers dealing with cleft lip and palate
- **Secondary bone grafting**, meaning bone grafting in the mixed dentition, became an established procedure after abandoning primary bone grafting.

A follow-up study of cleft children treated with primary bone grafting. 1. Orthodontic aspects. *Friede H, Johanson B*
Scand J Plast Reconstr Surg. 1974; 8(1-2):88-103.



Rationale and Indications for SABG

- Allowing **tooth eruption** through grafted bone
- **Stabilization of maxillary arch**, improving the condition for prosthodontic treatment such as crown, bridges and implants
- Providing **bony support** for **orthodontic closure** of teeth in **cleft region**
- Speech problems caused by escape of air from **oronasal communication** can also be improved
- It can also be used to **augment the alar base** to achieve **symmetry** with non-cleft side, thereby improving facial appearance



Graft Sources



Cortical Bone

- Cortical bone takes a **longer time to incorporate** as it relies upon vascular ingrowth by **creeping substitution**
- A cortical graft will usually be replaced by invasion of bone cells originating from the recipient site.
- The **metabolic turnover and remodeling** of cortical bone are **much slower** than in cancellous bone.
- Remains as component of new and necrotic bone
- More susceptible to infection



Cancellous Bone

- Cancellous bone is **more vascular**, has **more space**, **contains more bone regeneration** and has better ingrowth of new bone from the adjacent bone segments.
- The cancellous autografts heal primarily by **osteogenesis - Osteo-conduction and Osteo-induction**
- The cancellous grafts are also found to **better enable tooth eruption**
- It is completely replaced by new bone and provides **greater mechanical strength**



Iliac Crest

- Iliac bone is the **most commonly used bone in bone grafting**
- It provides a large amount of cancellous bone
- **2 surgeon approach** is taken and the cleft side can be prepared at the same time as that of harvesting
- No growth disturbances

Disadvantages

- Possible scarring
- Transient post operative pain
- Delayed ambulation and mild transient gait disturbances



To reduce complication

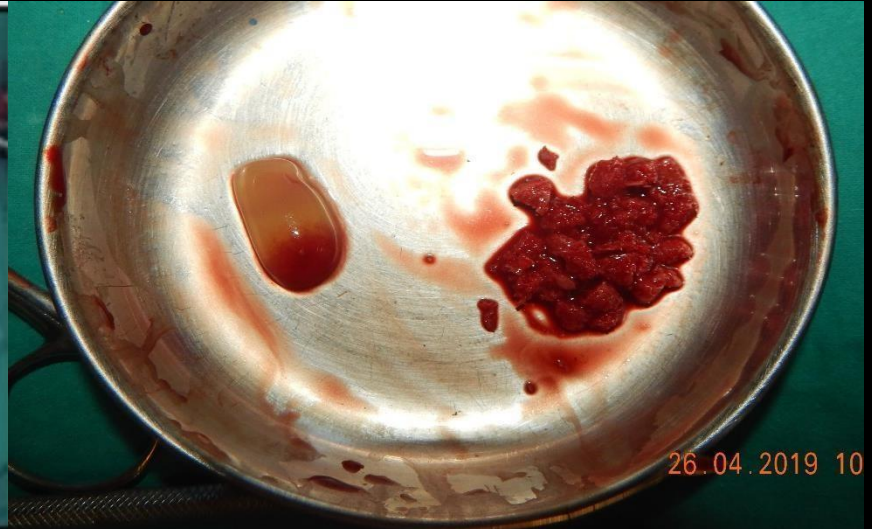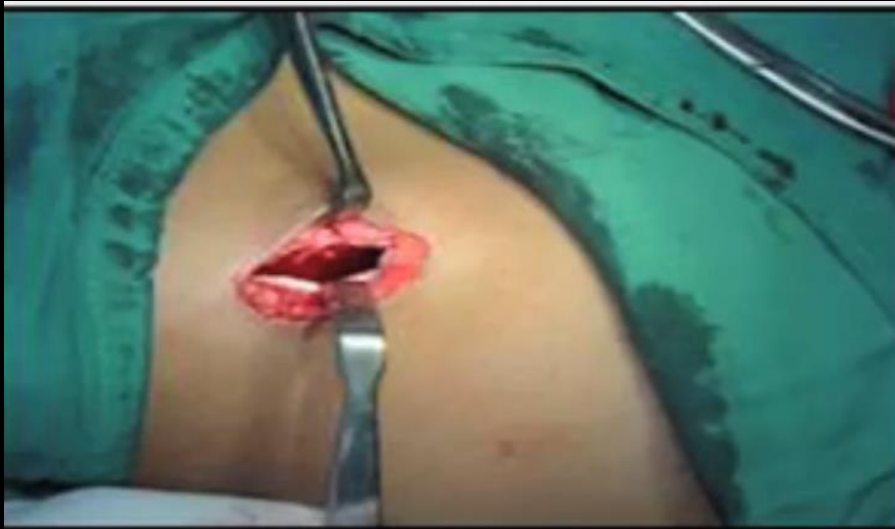- Make limited incision
- Minimal musculature elevation
- Meticulous haemostasis
- Re-approximation of cartilage cap
- Adequate pain control with early ambulation



Trephine technique should be employed to harvest maximum cancellous bone to avoid complication

T Ilankovan V, Stronczek M, Telfer M, et al. A prospective study of trephined bone grafts of the tibial shaft and iliac crest. *Br J Oral Maxillofac Surg* 1998;36:434-9.





Cortico cancellous bone graft from iliac
crest

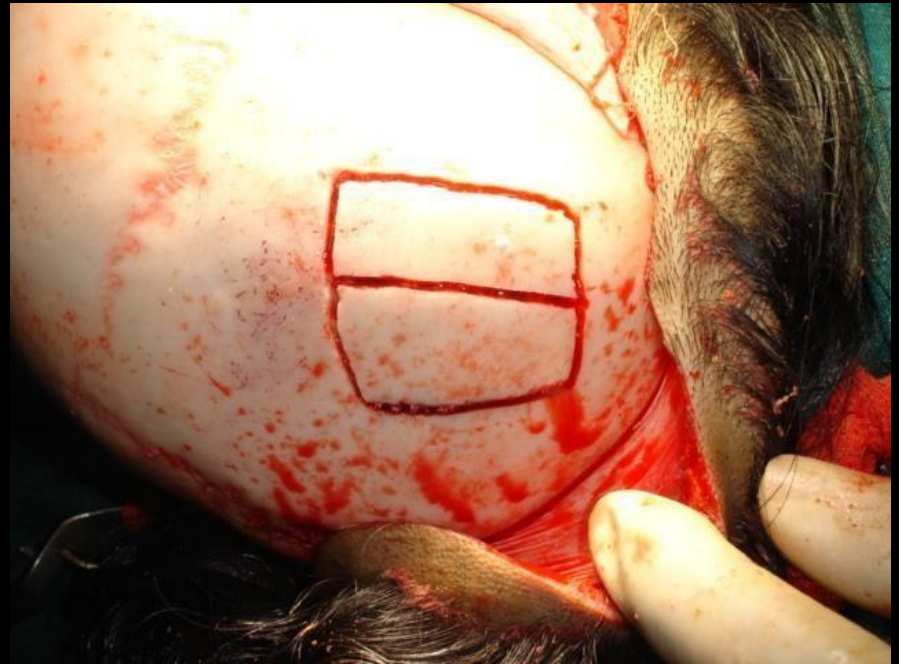

Cranium

- Advantage of a concealed scar
- Less post operative pain
- Less resorption

Disadvantage

- Sparse cancellous bone
- Increased operative time
- Increased risk of post operative complication - Dural tear, CSF leak, hematoma, dura exposure

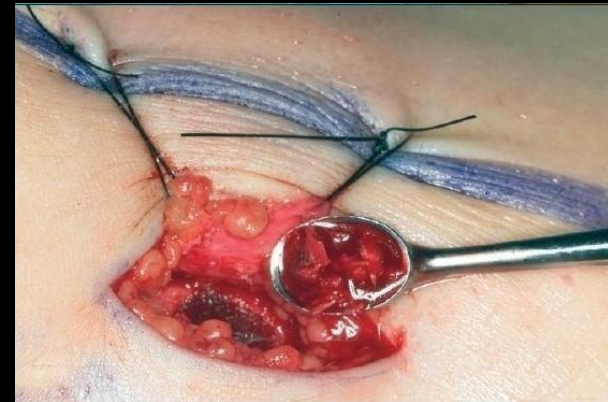
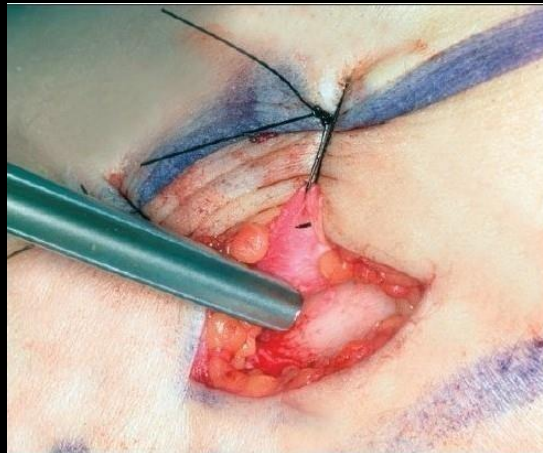
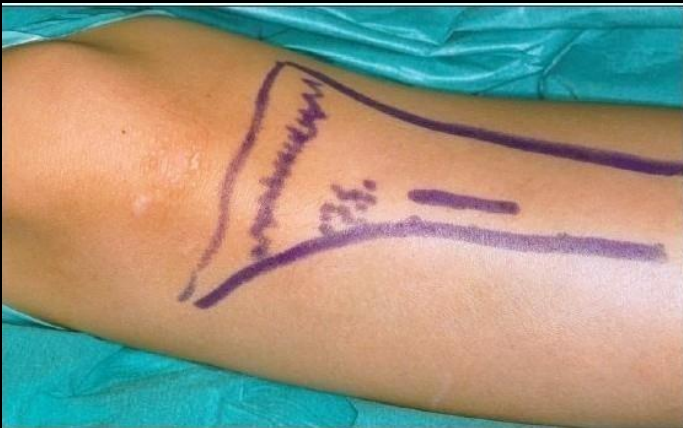


Tibia

- The use of tibia results in less - bleeding, post operative time, post operative pain and also allows early ambulation

Disadvantages

- Possible growth disturbances because of injury to epiphyseal plate growth centre
- Less quantity of cancellous bone as compared to Iliac rest so the other leg tibia is often used



Source - Internet



Mandibular Symphysis

- The mandible has **same embryonic origin** as that of maxilla
- Because it's a **membranous bone**, the **resorption is low and** revascularization is fast
- Surgery can be performed in the same operative field and thus discomfort is less with lesser hospital stay
- **Disadvantages**
 - The amount of bone that can be collected depends on the mandibular development
 - Risk of mental nerve, central and lateral incisors roots damage



RIB

- Rib has also been utilized to close the alveolar cleft; however, it is considered to be of limited use by many due to its **donor site morbidities, including visible scarring and pain.**
- Rib grafts have also been criticized for difficulties in orthodontic tooth movement

Kuijpers-Jagtman AM, Stoelinga PJ. Letters to the editor. Cleft Palate Craniofacial Online Journal 2000;37:421



The Future?



- Because of the donor site morbidity and complications associated, there are many ongoing efforts to find alternate source for graft material

BMP

- One of these sources is **bone morphogenic protein (BMP)** delivered on a collagen sponge
- Reports have shown some success with the application of this product.
- It is important to note that this product has substantial cost and for some its availability is limited thereby increasing the “**burden of care**”

Fallucco MA, Carstens MH. Primary reconstruction of alveolar clefts using recombinant human bone morphogenic protein-2: clinical and radiographic outcomes. J Craniofac Surg 2009;20 (Supl 2):1759–1764 Seminars




DBFB and FDB

- DFDB (demineralized freeze - dried bone) and FDB (freeze - dried bone) possess a high osteoconductive property.
- Francis et al. compared the results in various ways and suggested the possibility of **substituting an iliac bone graft** for a bone graft by adding **recombinant human bone morphogenetic protein rh BMP** to the **DBM scaffold**.
- These substitutes have the advantage of reducing donor-site morbidities, infection, disease transmission, and host incompatibility have been reported
- In animal studies, premature fusion and growth restriction of the suture line have been reported



PRP and PRF



PLATELET RICH PLASMA (PRP)

PLATELET RICH FIBRIN (PRF)

Recently addition of PRP and PRF to the graft bone have been put into practice but its usefulness is still questionable and more research is warranted for the same.



β-TCP

- **Microstructured Beta Tri calcium Phosphate** has also being used as a substitute to autologous bone grafts.
- Janssen NH et al reported that - Secondary alveolar grafting using microporous β-TCP can safely be used in the clinical situation.
- **Residual calcified tissue, canine eruption, and complication rates** at the recipient site are **comparable** to those **with autologous grafts**.

Janssen NG, Schreurs R, de Ruiter AP, Sylvester-Jensen HC, Blindheim G, Meijer GJ, Koole R, Vindenes H. Microstructured beta-tricalcium phosphate for alveolar cleft repair: a two-centre study. Int J Oral Maxillofac Surg. 2019 Jun;48(6):708-711. doi: 10.1016/j.ijom.2018.11.009



rhBMP-2

- Literature review shows of all the bio-materials Recombinant human bone morphogenic protein-2 (rhBMP-2) has been best studied and showed comparable efficacy to iliac crest bone graft in terms of volume of bone regeneration, bone density, and capacity to accommodate tooth eruption within the graft site.
- The balance between innovation and safety is a complex process requiring constant vigilance and evaluation.
- A lot of study and research is still required before we can safely consider replacing autologous bone grafts with bone substitutes and allografts

Alternatives to Autologous Bone Graft in Alveolar Cleft Reconstruction: The State of Alveolar Tissue Engineering. J Craniofac Surg. 2018 May;29(3):584-593.



www.craniofacialinstitute.org

Although there are a few studies and literature reviews reporting different compatible bio materials to replace autologous bone grafts, **there are no systematic reviews and meta analysis done to conclusively suggest the most appropriate biomaterial.**

As of now alveolar cleft defect grafting must include autologous bone grafts as none of the current modalities in practice can replace autologous bone graft

Further studies are required to search for idea bone graft substitute.

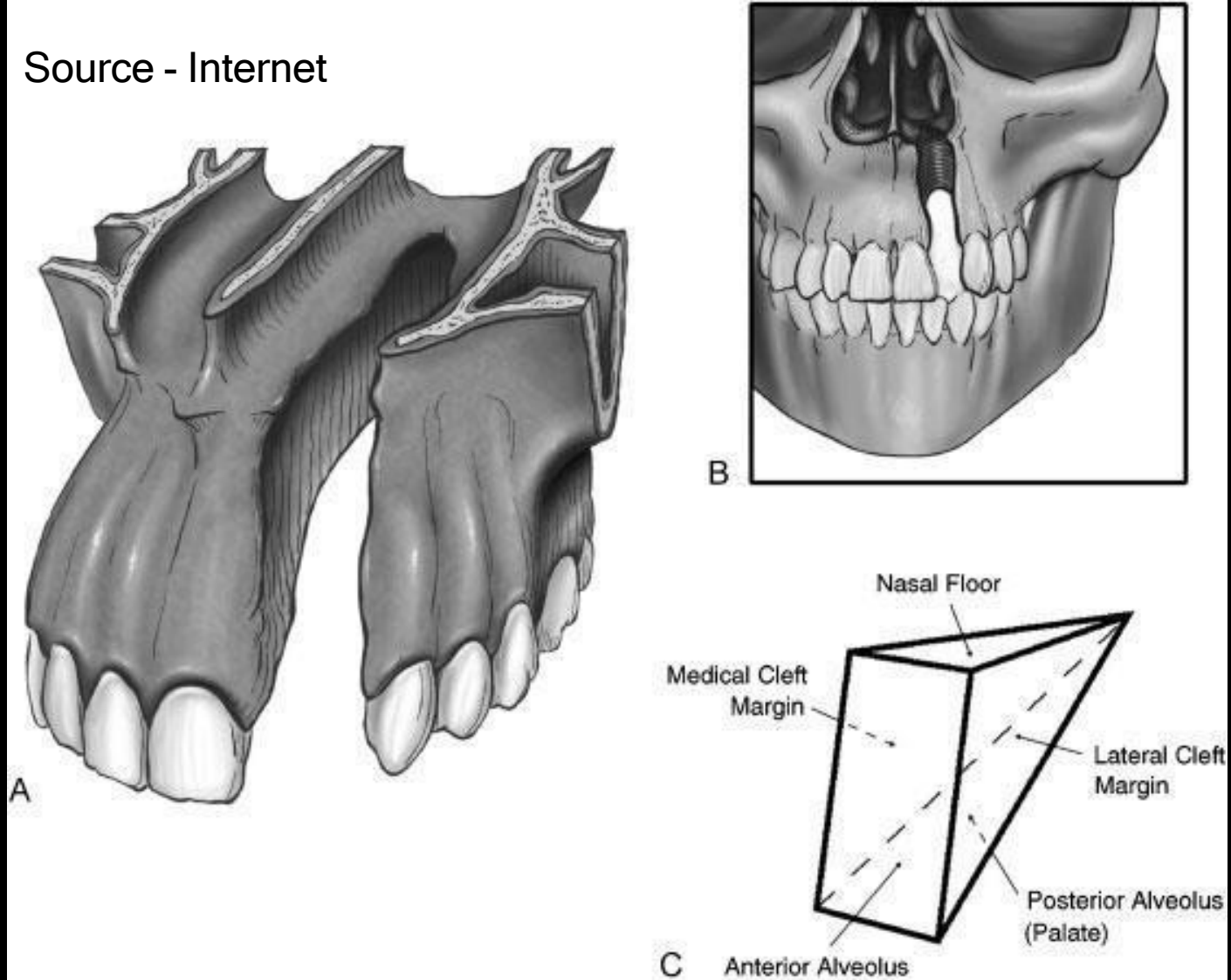


Our Technique

Morpho-functional Alveolar Bone Grafting

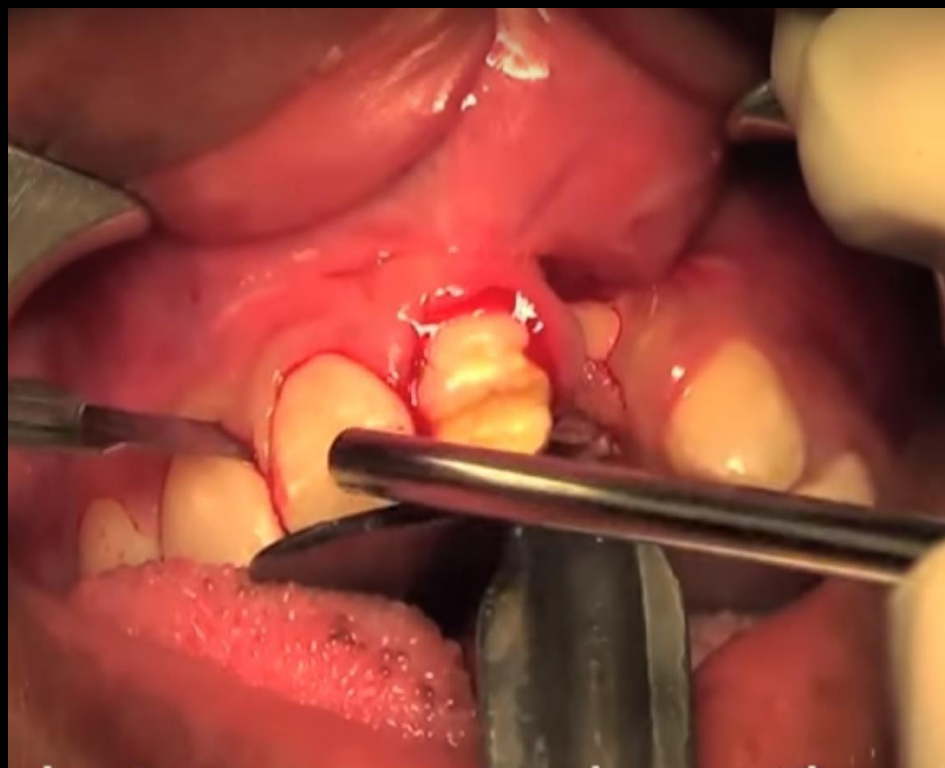


Source - Internet

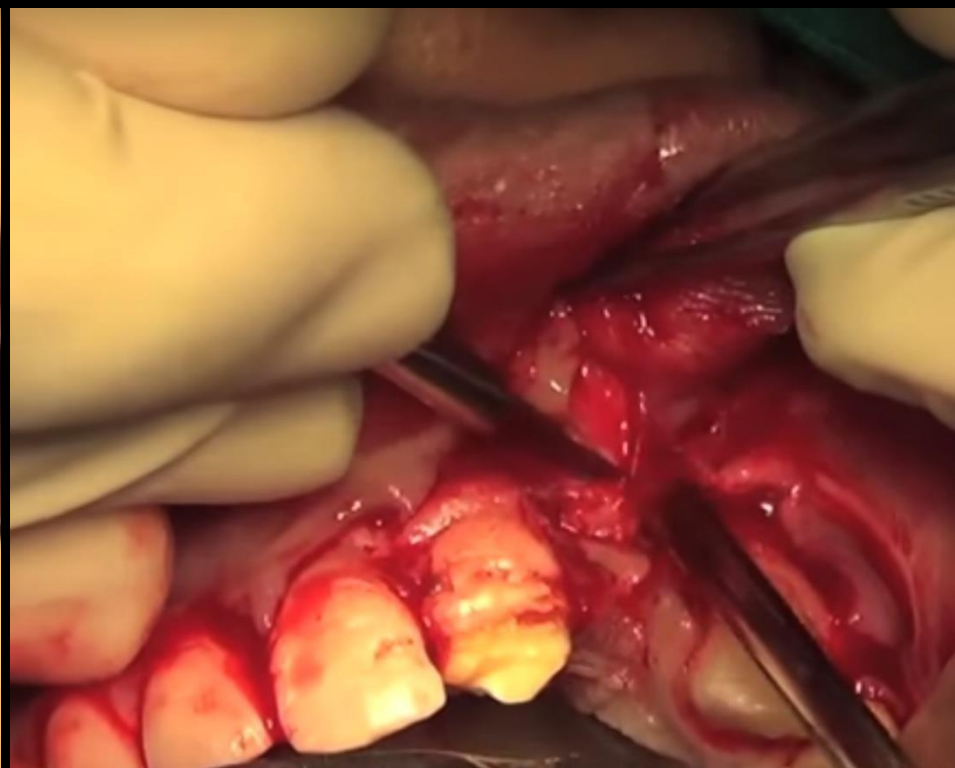


Morphology of the defect - The defect when viewed in 3 dimensional appears, Triangular or Pyramidal



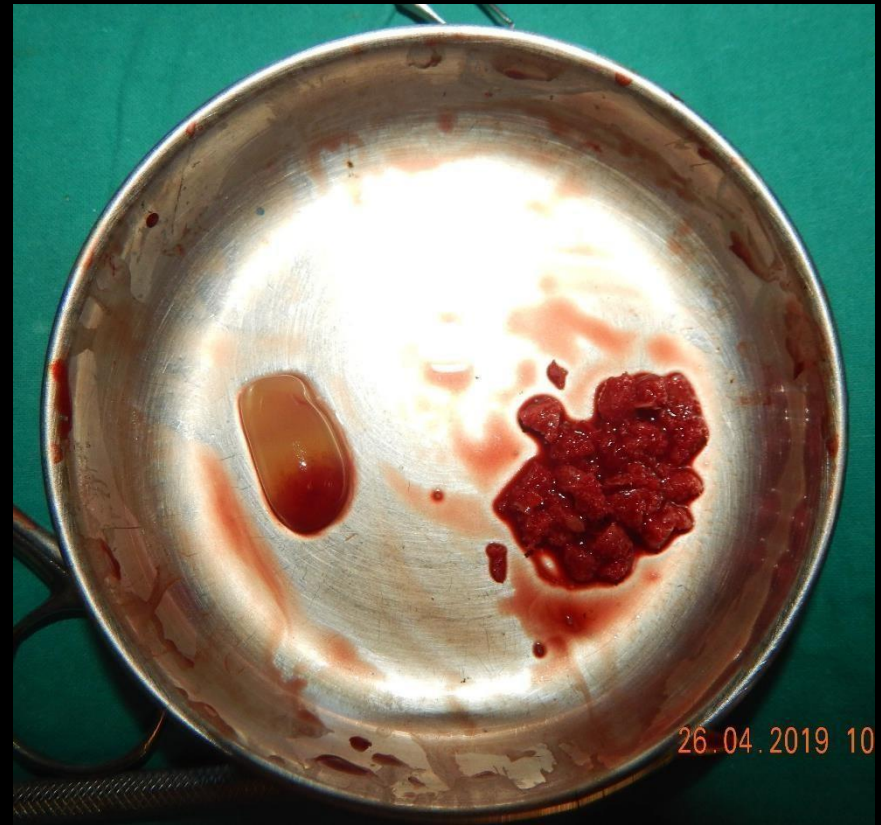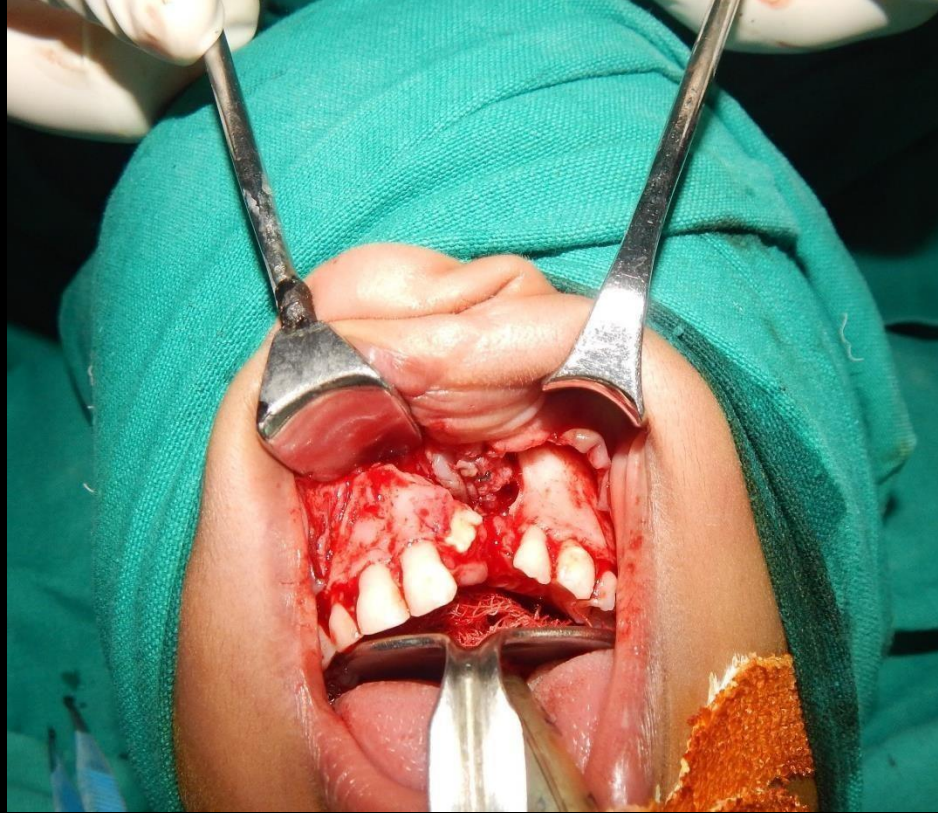


- Crevicular Incision extending around the defect to reflect the mucoperiosteum



- Sharp dissection to separate the nasal layer from oral layer

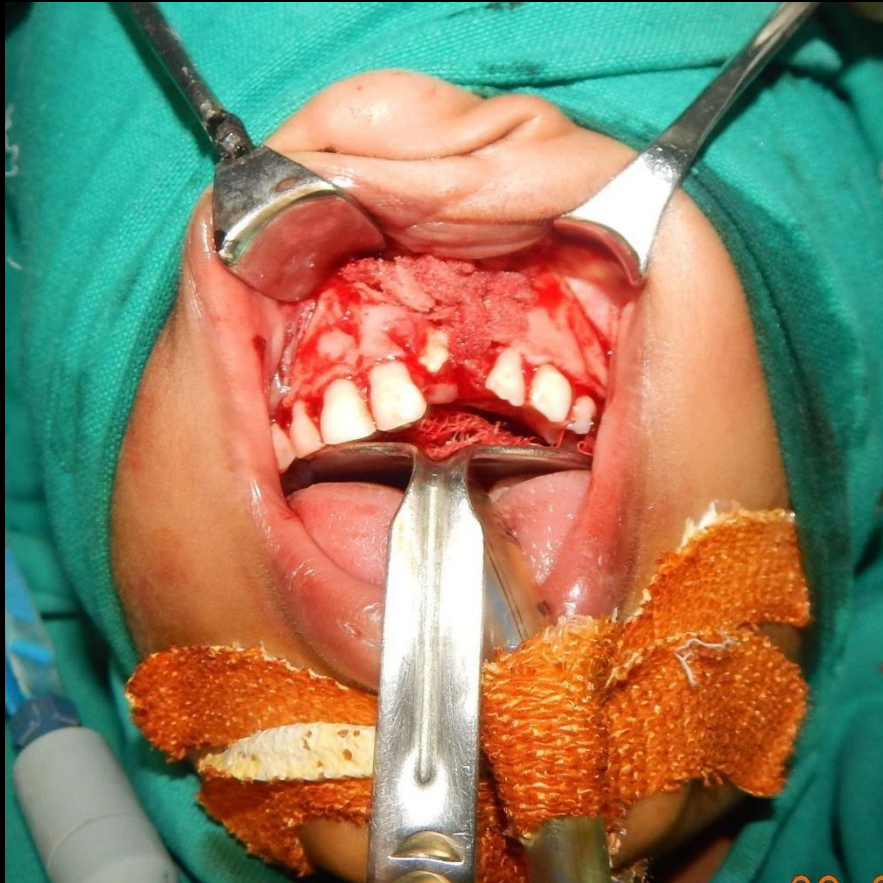




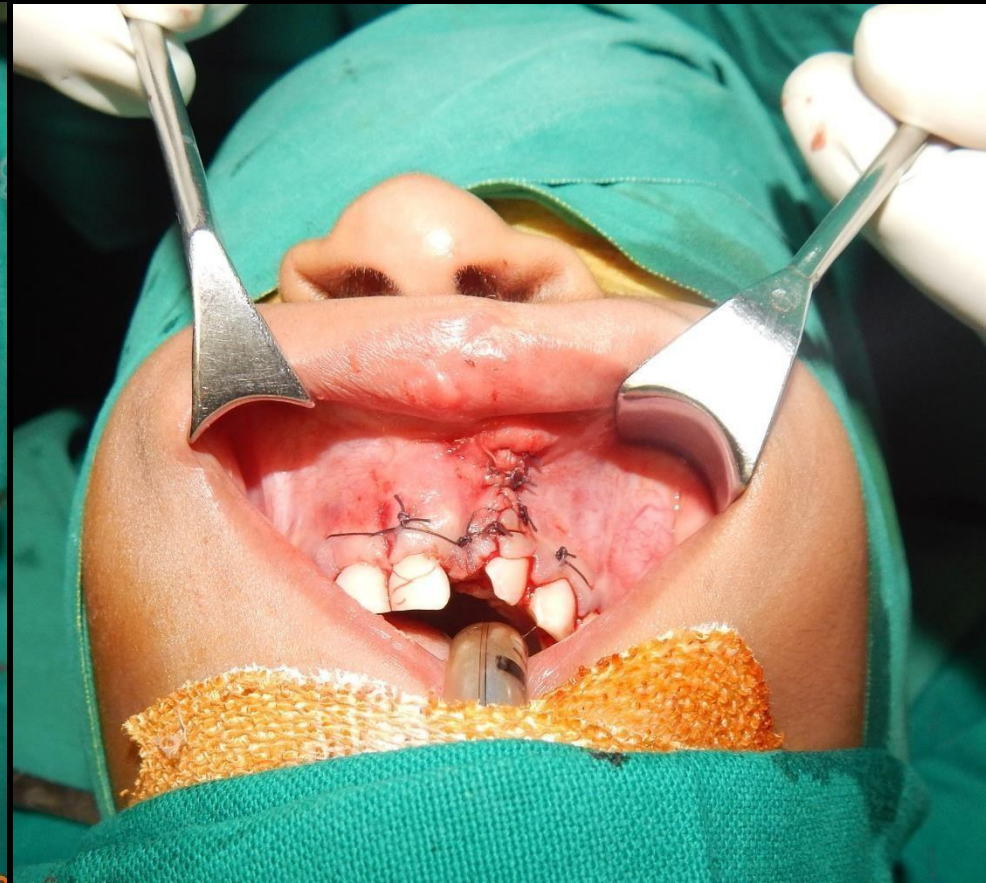- Nasal layer is elevated in cephalad direction from palatal floor, and palatal floor is sutured
- Perforations if any, in nasal layer is sutured using 4-0 Vicryl

Bone graft harvested from iliac crest and PRP



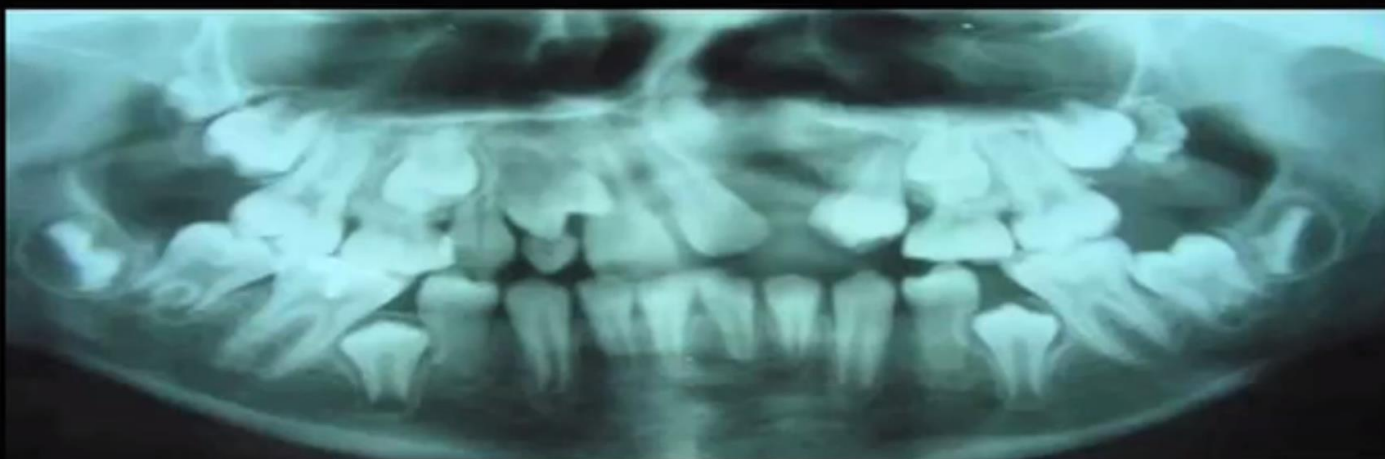
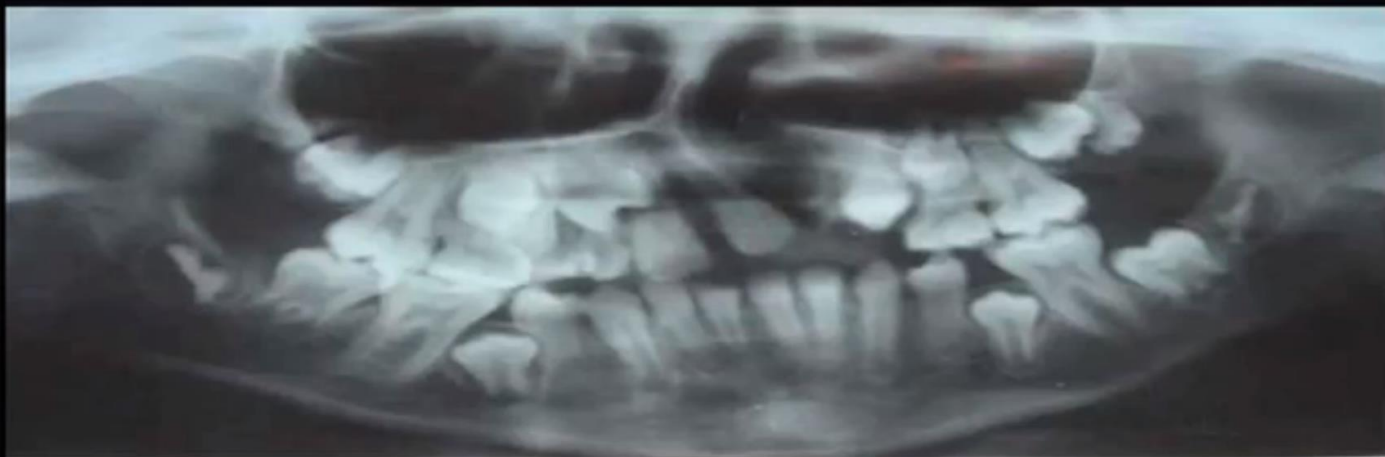

Cortico-cancellous Bone mixed with PRP, grafted into the defect.



V-Y Closure increase vestibular length with water tight suturing





Pre- and post- op OPG x-rays



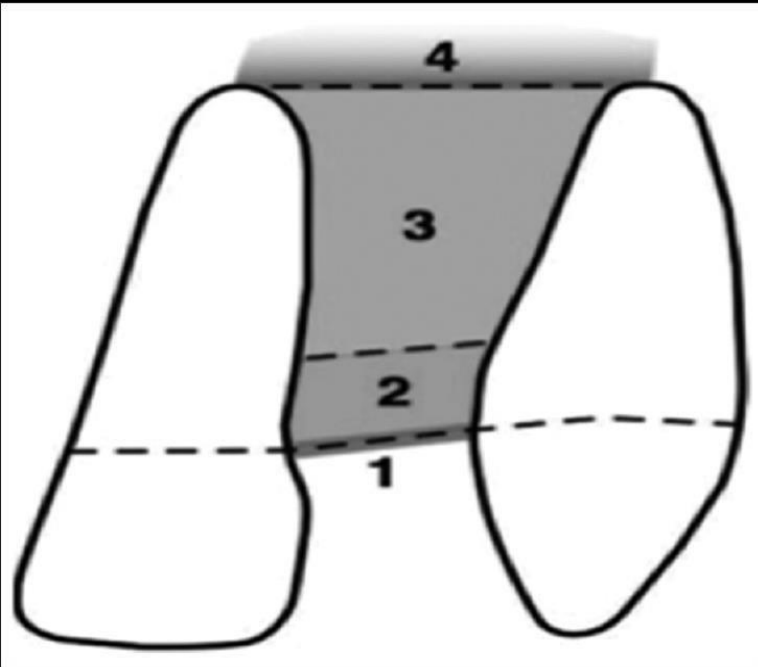
Radiographic assessment of Alveolar Bone Grafting

- Bergland Scale
- Chelsea Scale
- Kindelan Scale



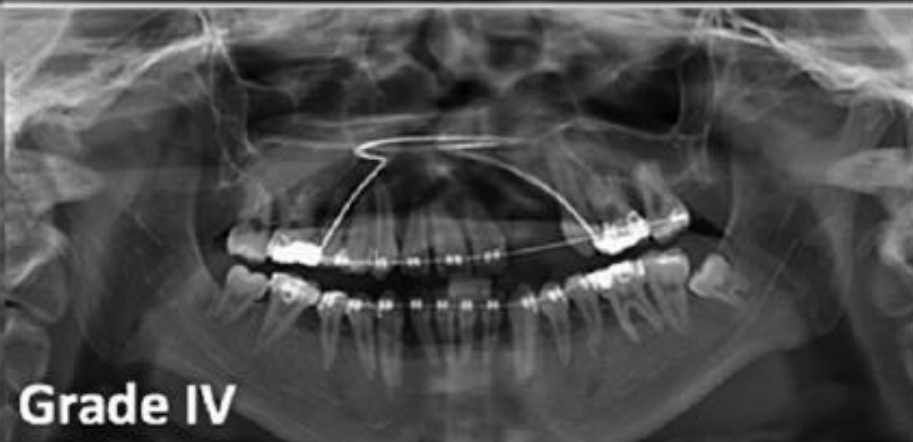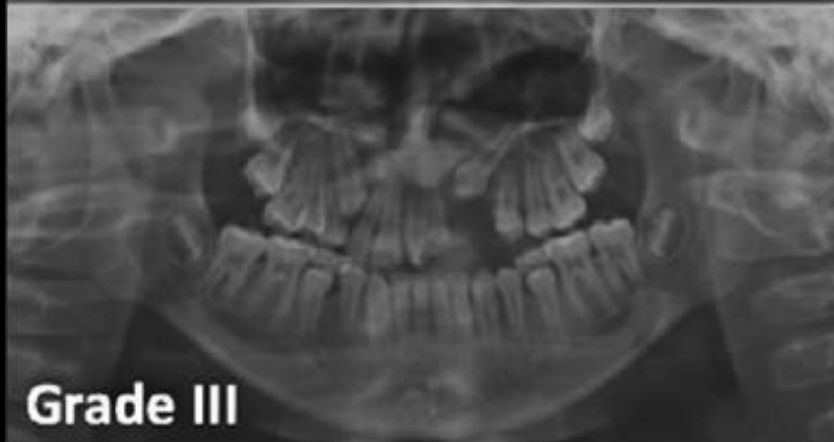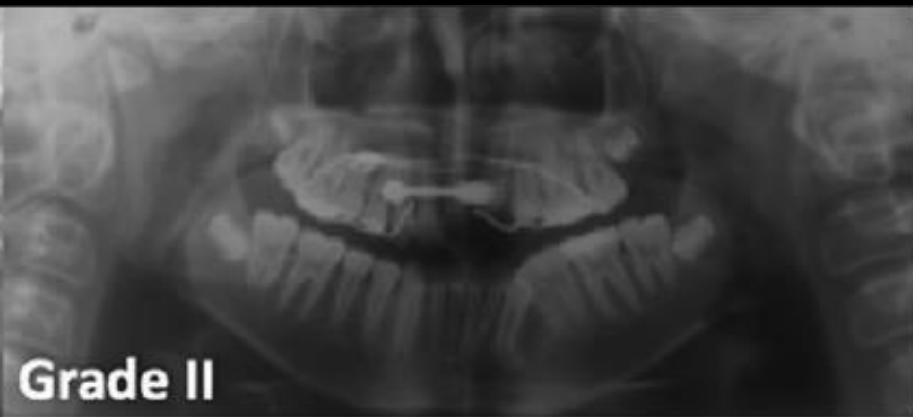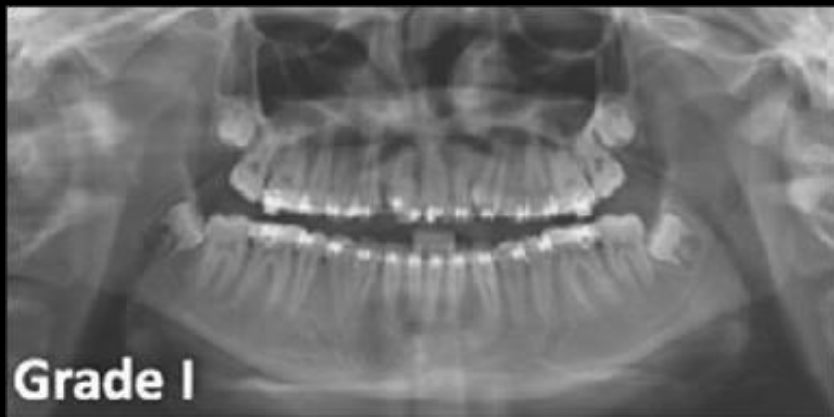Bergland Scale

- 4 point scale
- Semi quantitative scale
- Measure interdental bone height
- Requires post operative peri apical X-ray



- Grade I: Ossification equals the height of the interdental septum
- Grade II: Ossification at least at 75% of the interdental septum
- Grade III: Ossification is <75% of the interdental septum height
- Grade IV: No evidence of bone integration.





Perez-Gonzalez A, Shinji-Pérez K, Theurel-Cuevas A, Jimenez-Murat Y, Carrillo-Córdova JR. *Autologous alveolar bone graft integration based on the Bergland scale in patients with primary lip and palate cleft: Experience in a third level hospital in Mexico City.* J Cleft Lip Palate Craniofac Anomal 2017;4:154-7



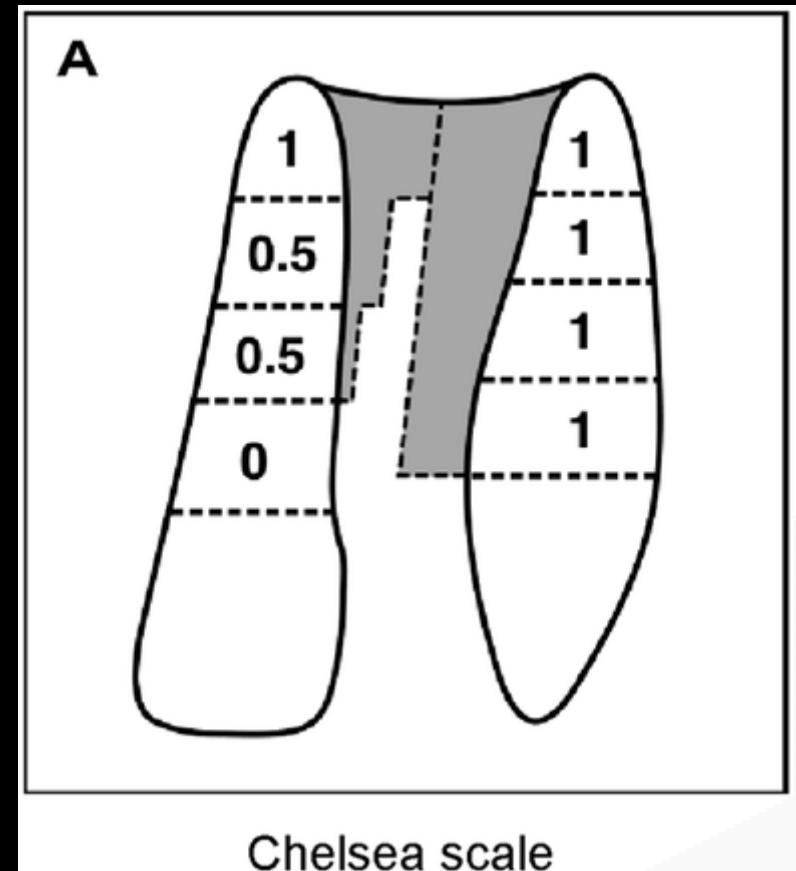
Kindelan scale

- Similar to Bergland technique - 4 Point Scale
- Measure bone formation on a 4 point scale between Pre-op and Post-Op X-rays
- Uses oblique **Occlusal view** X-rays instead of peri-apical view



Chelsea Scale

- 8 Point Scale
- Assesses position of bone in relation to entire root length in cleft and cleft midline
- Partial bone fill between root and midline is given 0.5 value
- Full bone fill gets a value of 1



Comparative reproducibility of three methods of radiographic assessment of alveolar bone grafting

Claire Nightingale*, Helen Witherow**, Fiona D. A. Reid*** and Raymond Edler*

*Department of Orthodontics and **Norman Rowe Maxillofacial Unit, Queen Mary's University Hospital, Roehampton and ***Department of Public Health, St George's Hospital Medical School, London, UK

- None of the three scales were more reproducible than the others
- The agreement between examiner were also similar across the three scale
- Neither occlusal nor peri-apical radiographs were found to enable greater reproducibility for assessment



Questionnaire

ESSAY

Management of Cleft Alveolus

Long Questions

- Different types of Alveolar Bone Grafting.

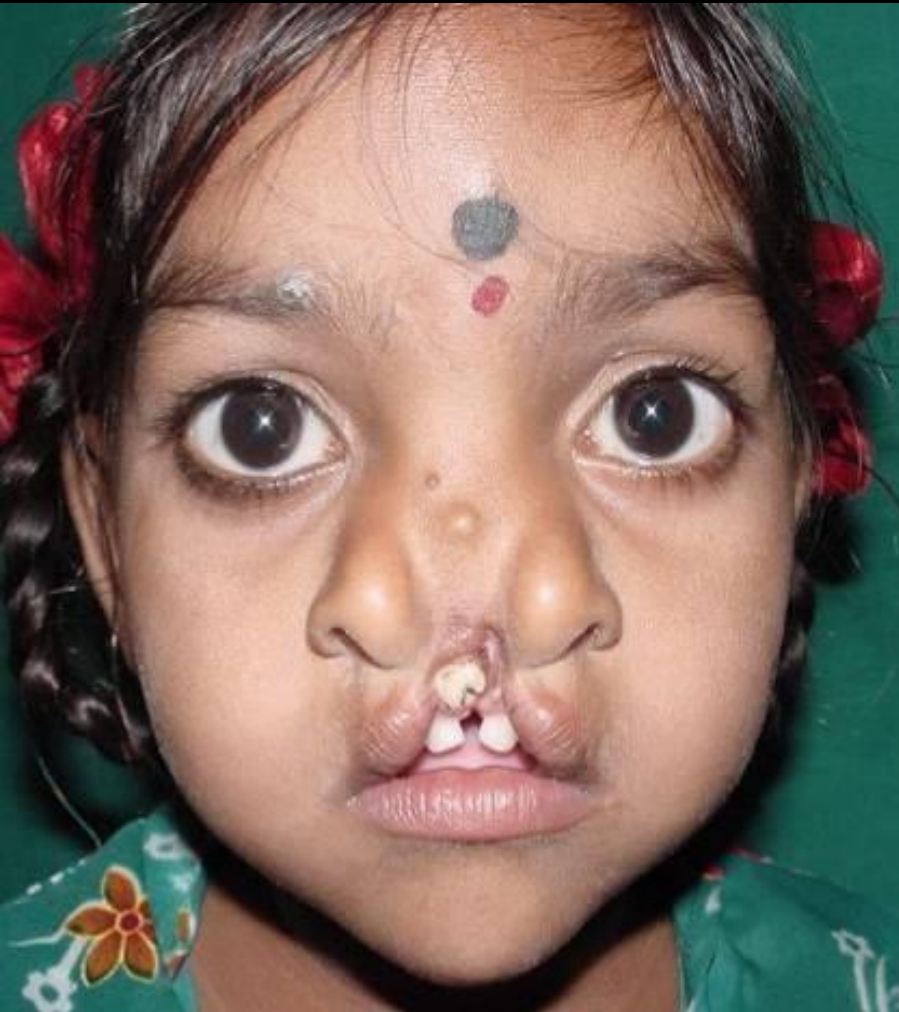

Viva Voce

- Types of Approaches for Harvesting of Iliac Bone
 - Surgical Anatomy of Iliac Region
 - Graft Sources for Bone Grafting
- Radiographic assessment of Alveolar Bone Grafting
 - Complications of Donor site
 - Reasons for Bone Grafting



Bring the Smile Back



Thank You



www.craniofacialinstitute.org