

Midface Distraction-significance and technical consideration

Prof. Dr. Dr. Srinivas Gosla Reddy
MBBS, MDS, FRCS (Edin.), FDSRCS (Edin), FDSRCS (Eng), PhD

Dr. Rajgopal R. Reddy MBBS, BDS, PhD Prof. Dr. S. B. V.

Ramana Reddy
MDS M.OrthoRCS (Lond.) (Glas.)
Dr. Mallikarjun Reddy
MDS (Ortho)
Dr. Hemwati Nandan
MDS (Ortho)

Dr. Ashish Fanan MDS
Dr. Avni Pandey MDS
Dr. Madhav Thumati, MDS

GSR Institute of Craniofacial Surgery Hyderabad, India



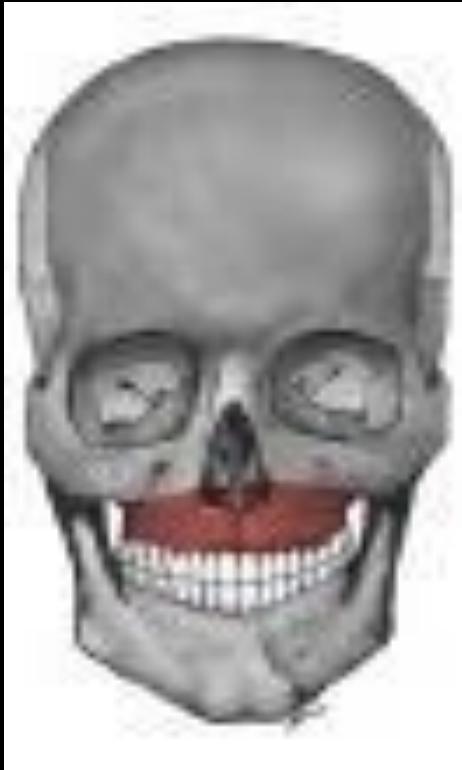GSR Institute of Facial Plastic Surgery



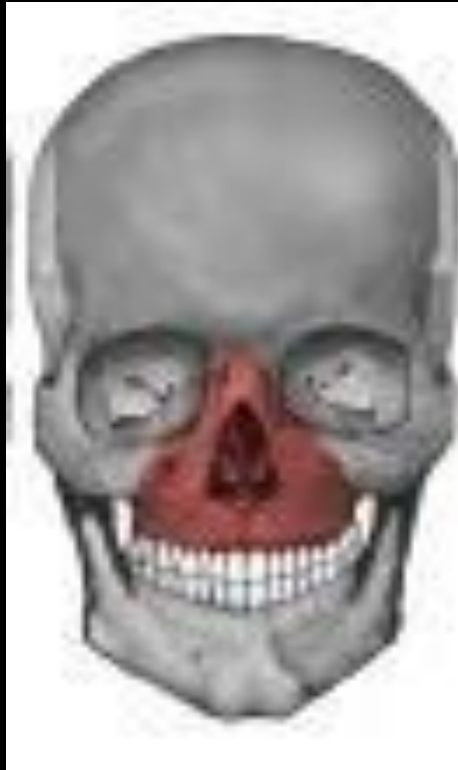- Non-profit hospital established in 1996
- Dedicated Cleft & Craniofacial Centre of Excellence
- Presently 1,600 cleft and craniofacial surgeries are done every year
- 3 surgeons and 4 fellows with full support team
- More than 30,000 documented cleft & craniofacial surgeries have been performed since 1996
- 600 primary new born cleft children are registered every year

Osteotomy of the Maxillary Complex

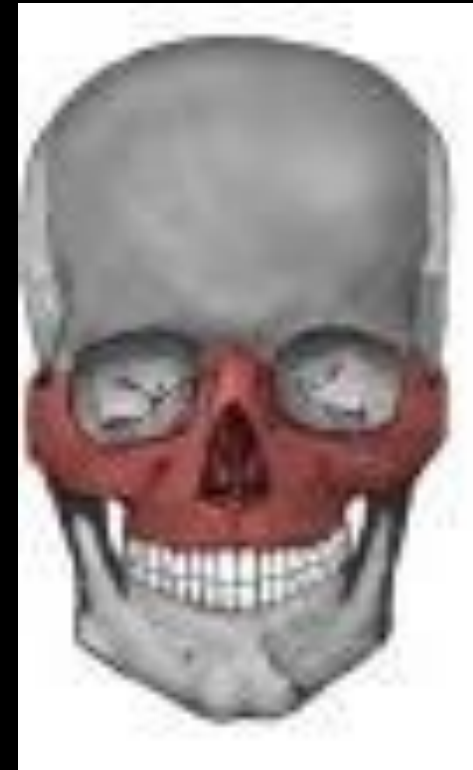AMD



LeFort I Osteotomy

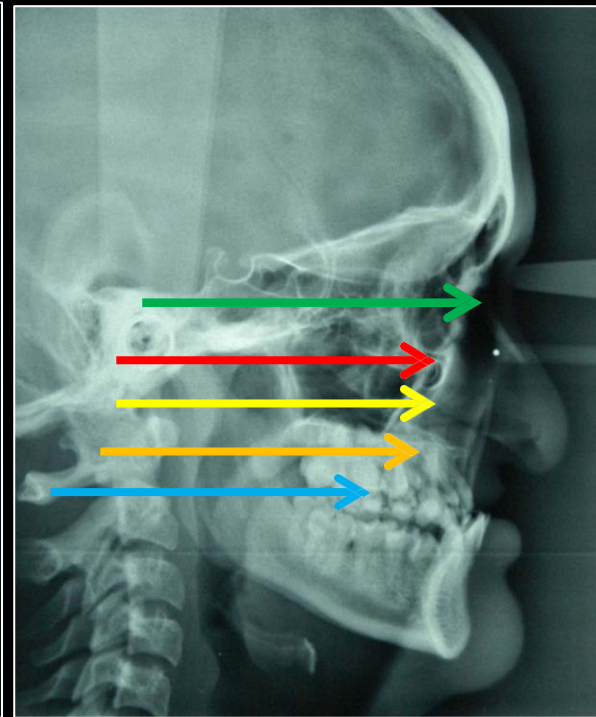
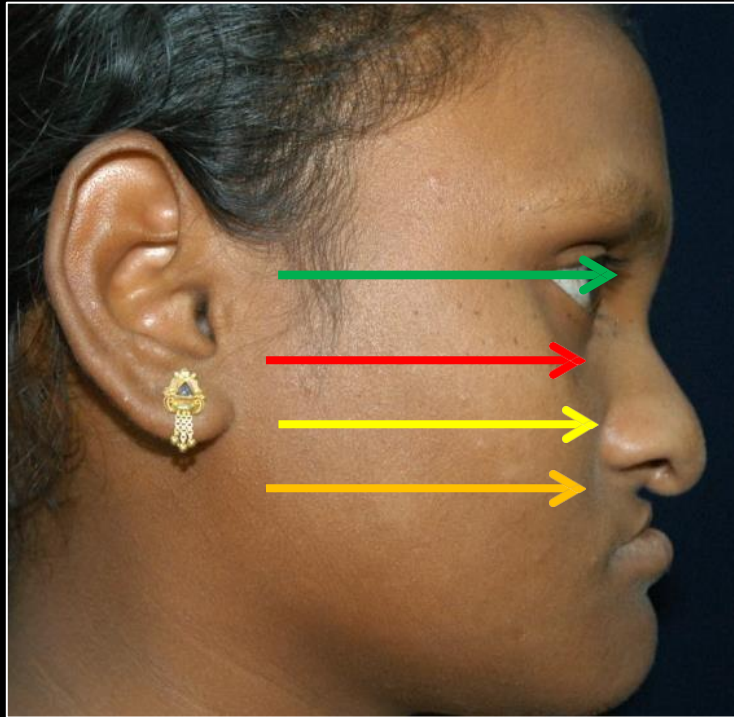


LeFort II Osteotomy



LeFort III Osteotomy

Fronto
monobloc



Skeletal Considerations

- Midfacial Skeletal Hypoplasia

Frontonasal FRONTOMONO BLOC

Infraorbital LEFORT III

Nasolabial HIGH LEFORT I OR LEFORT II

Maxilla LEFORT I

Dentoalveolar AMD



How to decide the treatment
plan

Distraction

vs.

Orthognathic surgery??



Distraction vs Osteotomy????

	Distraction	Osteotomy
Need for bone grafting	Not necessary even for defects > 20 mm	Necessary for defects >10 mm
Control over movement	3 Dimensional	2 Dimensional
On infants and children	Can be done	Think about permanent teeth and sufficiency of bone
Distortion and loading of the TMJ	Does not cause	Risk of causing
Damage to the inferior alveolar nerve	Does not cause	Risk of causing
Increasing ramus height	Possible	Not Possible
Cost	Expensive (distractors and equipment)	Relatively inexpensive
Time	Takes time	Quick Fix Method



How to decide the treatment
plan

Total maxillary

Distraction

vs.

Anterior maxillary
distraction??



Total maxillary distraction vs Anterior maxillary distraction????

	Total	Anterior
Need for alveolar bone grafting	Required	Required
Control over movement	3 Dimensional	2 Dimensional
On infants and children	Can be done	Think about permanent teeth and sufficiency of bone
Distortion and loading of the TMJ	Does not cause	Does not cause
Damage to the infraorbital nerve	Does not cause	Does not cause
Cost	Expensive (distractors and equipment)	Relatively inexpensive
Time	Takes time	Quick Fix Method



Indications of Lefort Osteotomy

- Scarring of the palate is **minimal**.
- Amount of movement required **less than 6 mm**
- When pharyngeal flap is not present.

Indications of Distraction

- Scarring of the palate is **present**
- Amount of movement required **more than 6 mm**
- When pharyngeal flap is present.
- Tongue flap or any local flap done for Fistula Closure.

INDICATIONS

TOTAL MAXILLARY DISTRACTION

- For **MIDFACE SKELETAL DEFORMITY** correction
- Scarring of the palate is **present**
- Amount of movement required **more than 6 mm**
- When pharyngeal flap is present.
- Tongue flap or any local flap done for Fistula Closure.

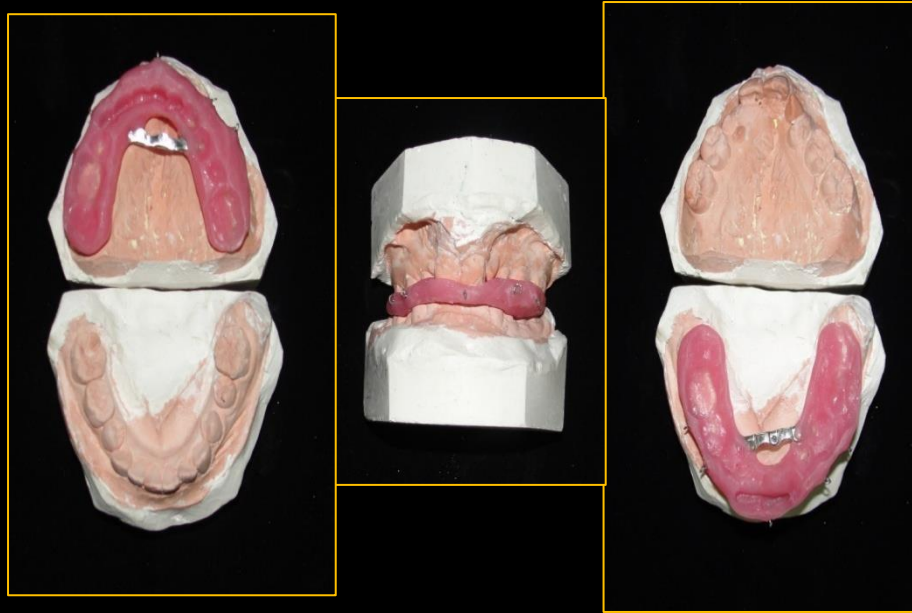
ANTERIOR MAXILLARY DISTRACTION

- For **DENTAL & MILD DENTOALVEOLAR SKELETAL DEFORMITY** correction
- Unilateral or bilateral cleft with normal transverse relation at the molars
- Anterior transverse collapsed arches
- Class I molar relation but anterior reverse overjet.
- In cases where maxillary length are severely compromised to work with in orthodontic perspective



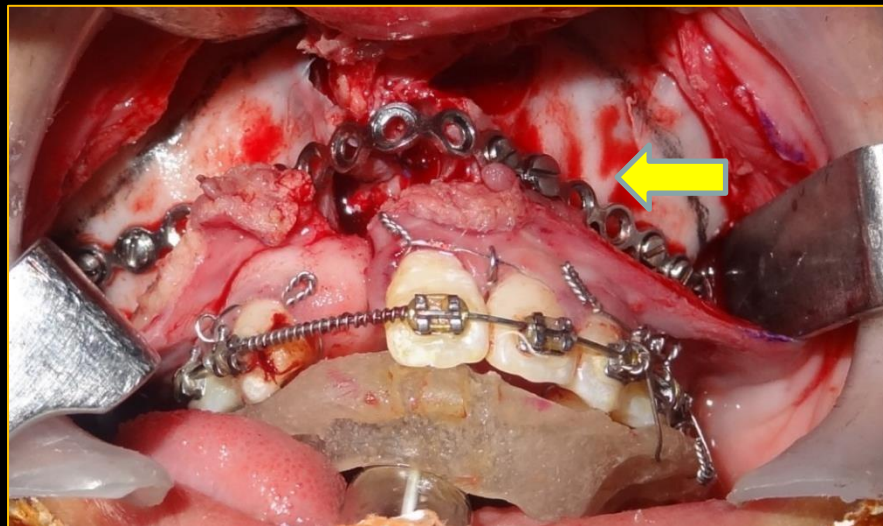
Planning

It remains **same** for either Distraction or Orthognathic surgery.



Splint

- To guide the maxilla into the desired occlusion.
- To counter the unfavorable movements due scar formation.
- Cross bar prevents posterior collapse of the arch.
- Fixation of the long rigid plate for arch stability.



Anterior Maxillary Distraction



Anterior Maxillary Distraction by Tooth-Borne Palatal Distractor

Rajan Gunaseelan, BDS, MB, FDSRCS(Eng),*

Lim K. Cheung, BDS, PhD, FRACDS(OMS), FCDSEHK(OMS),†

Rangarajan Krisnaswamy, MDS, MOrth RCS(Edin),‡ and

Muthusubramanian Veerababu, BDS, MDS§

Anterior maxillary osteotomy is mainly indicated for the correction of maxillary dentoalveolar protrusion. It is commonly used to retrude and may also impact the anterior maxilla if the diagnoses include vertical maxillary excess as well. Three techniques are currently practiced to achieve the anterior maxillary osteotomy: Wassmund osteotomy,¹ Wunderer osteotomy,² and anterior maxillary downfracture osteotomy.^{3,4} The osteotomy cuts are essentially the same but vary from each other only in the incision design, access to the maxillary bone, and the direction of maxillary mobilization. Advancement of the anterior maxilla by osteotomy is technically difficult because of the tight palatal mucosa; this advancement is likely to be complicated by oronasal or oronasal fistula. Only 1 case is reported where the anterior maxilla was advanced by osteotomy, and this was in 1968 by William Bell.⁵ Bell essentially used a Wassmund osteotomy to correct anterior maxillary retrusion and Class III malocclusion. The dental alveolar gap created from the advancement of the anterior maxilla had to be bone grafted and was later fitted with a partial removable denture.

The clinical application of distraction osteogenesis to correct hypoplastic maxilla is a relatively recent development, and this procedure is mainly used to correct cleft lip and palate deformities. The gradual advancement of the maxilla is normally achieved via a cranially attached distractor⁶ or orthodontic face

mask.⁷ More recently, internal distractors have also been used.⁸ However, this procedure mostly involves movement of the whole maxilla at Le Fort I level rather than the anterior maxilla alone.

Traditionally, tooth-borne palatal distractors have been used for rapid maxillary expansion in children and surgically assisted maxillary expansion in adults.⁹ Expansion has always been in the transverse dimension, and aims to correct the collapsed buccal occlusion, particularly in cases of cleft palate.¹⁰ The use of tooth-borne palatal distractor was confirmed feasible in dogs to distract the anterior maxilla forward and generate new bone and palatal mucosa.¹¹ However, a follow-up radiographic study¹² indicated that tooth-borne distractor tended to produce greater dental movement than skeletal movement. Bone-borne palatal distractors have recently been developed, which ensure that the transverse expansion is derived from the expansion of the palatal bone rather than the buccal tilting of the posterior teeth.¹²⁻¹⁴ The use of a palatal distractor in the anteroposterior direction to advance a retruded maxilla after an alveolar osteotomy in a noncleft patient has been reported once.¹⁵ The aim of this article is to describe an alternative technique involving the distraction of the entire segment of the cleft anterior maxilla by a tooth-borne palatal distractor. This technique is illustrated with 2 cases of clinical cleft lip and palate.

Materials and Methods

INDICATIONS

This technique is indicated for patients presenting with maxillary hypoplasia in the anteroposterior and transverse planes, particularly in the case of cleft lip and palate deformities. The dental crossbite is preferably restricted to the anterior and premolar teeth, with the molars in the normal buccal occlusion. The technique is particularly suitable for dental crowding in the anterior maxilla. As new bone is generated by the distraction, the displaced teeth can be aligned into occlusion by orthodontics following surgery.

Rajan Gunaseelan et al:

J Oral Maxillofac Surg 65:1044-1049, 2007

American Association of Oral and Maxillofacial Surgeons
0278-2391/07/6505-0034 doi:10.1016/j.joms.2005.12.049

This technique is not expected to be widely used, but would be of particular interest to surgeons on specific indications such as existing crowding of the dental arch in a Class III malocclusion from a retruded maxilla.

As the technique generates more space at the buccal segment, it would enable a crowded dental arch to be properly aligned by orthodontics without a need for dental implants.

The forward movement of the entire anterior maxillary segment also improves upper lip and paranasal prominence in cleft lip and palate patients.

*Professor, Oral and Maxillofacial Surgery, Ragas Dental College and Hospital, Chennai, India.

†Chair Professor, Oral and Maxillofacial Surgery, Faculty of Dentistry, University of Hong Kong, Hong Kong SAR, China.

‡Professor, Orthodontics, Ragas Dental College and Hospital, Chennai, India.

§Associate Professor, Oral and Maxillofacial Surgery, Ragas Dental College and Hospital, Chennai, India.

Address correspondence and reprint requests to Dr Cheung: Oral and Maxillofacial Surgery, 2/F Prince Philip Dental Hospital, 34 Hospital Road, Hong Kong SAR, China; e-mail: lkcheung@hku.hk
© 2007 American Association of Oral and Maxillofacial Surgeons
0278-2391/07/6505-0034\$22.00/0
doi:10.1016/j.joms.2005.12.049



Anterior Maxillary Distraction

Indications

- For Dental & Mild Dentoalveolar skeletal deformity correction
- Unilateral or bilateral cleft with normal transverse relation at the molars
- Anterior transverse collapsed arches
- Class I molar relation but anterior reverse overjet.
- In cases where maxillary length are severely compromised to work with in orthodontic

Contraindications

- Unilateral or bilateral cleft with posterior cross bite
- With missing anchor teeth
- Clefts with anterior open bite
- Severe maxillary deficiency
- Cases with adequate arch length
- Cases with severe scarring.

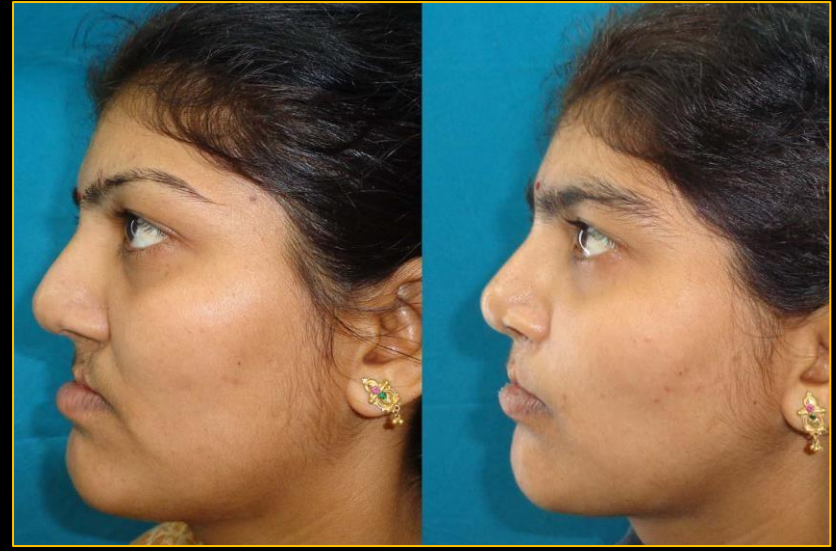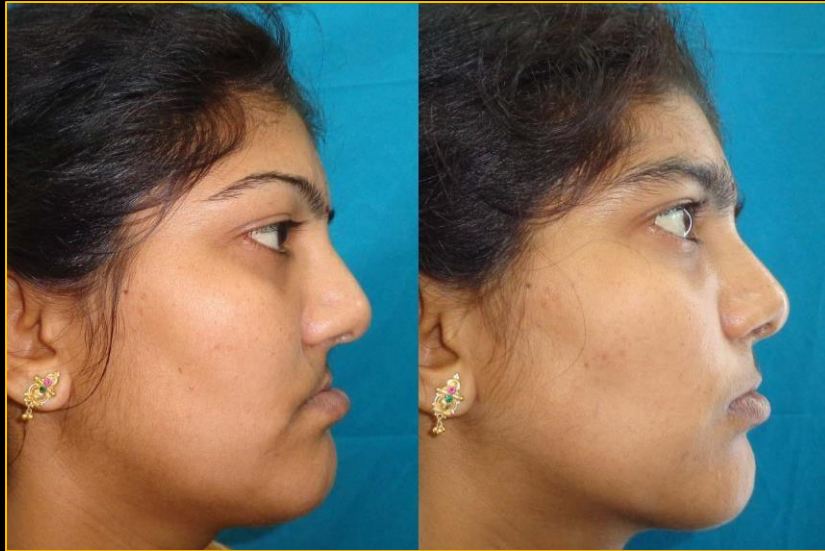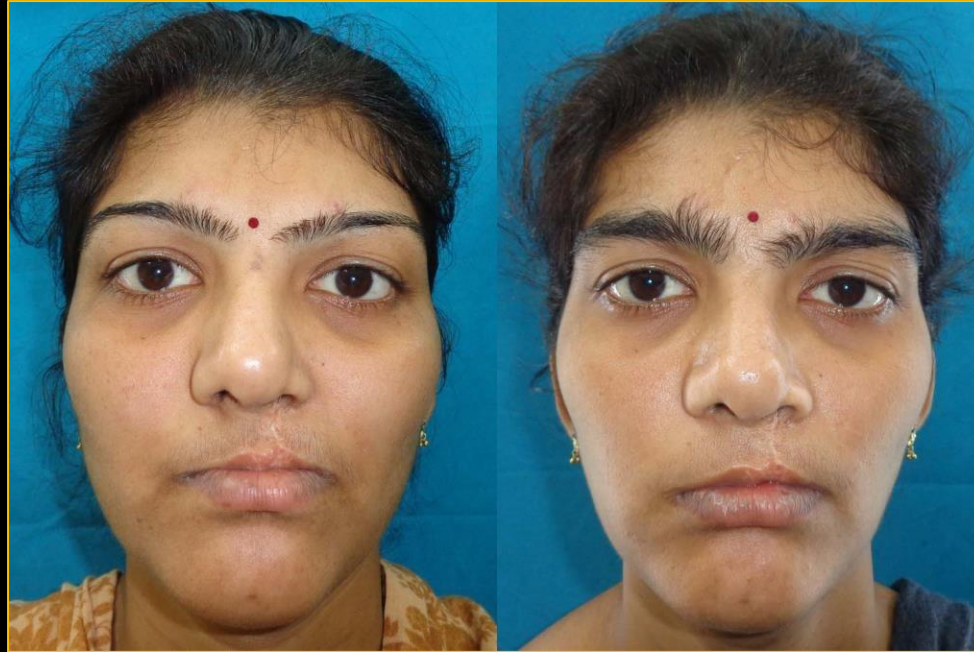Eg-

Anterior fistula closure with tongue flap,

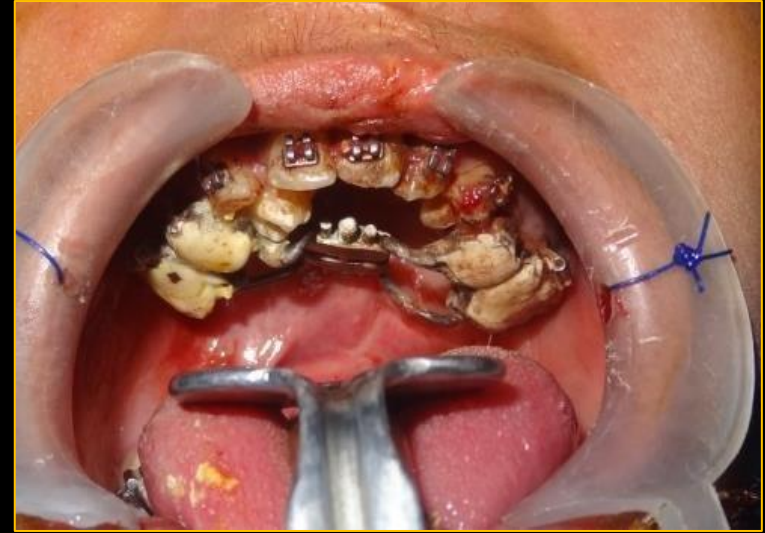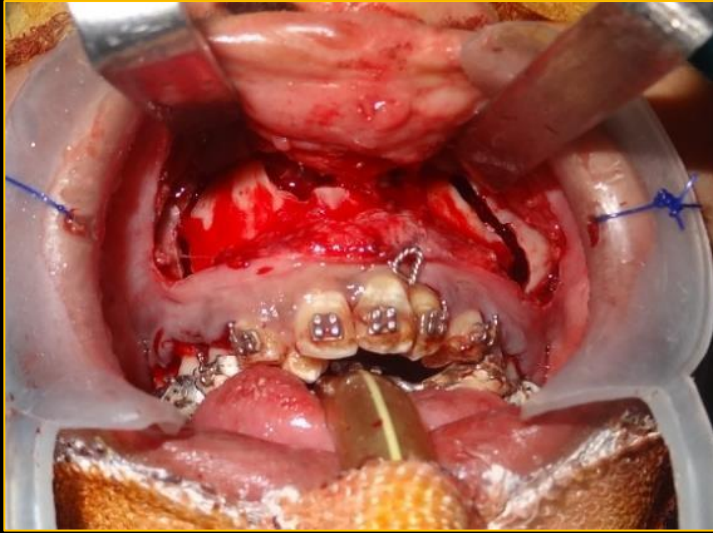Buccal myomucosal flap.



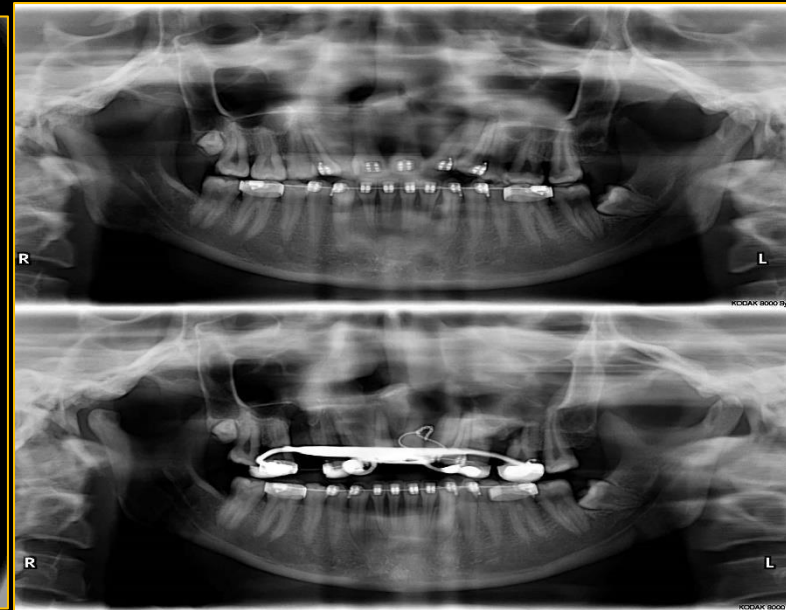
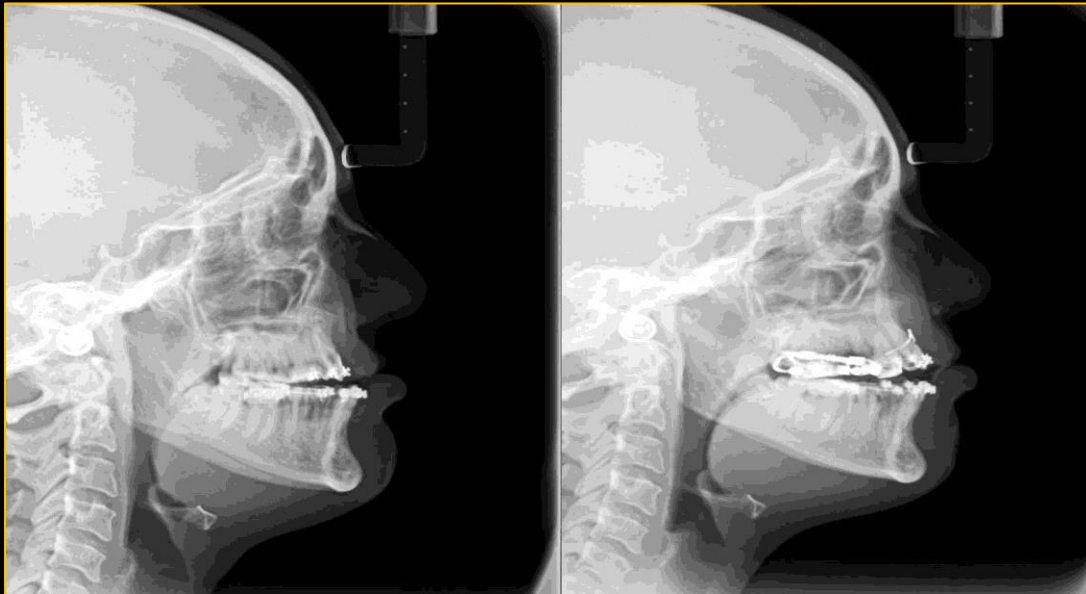
Pre and Post-Op



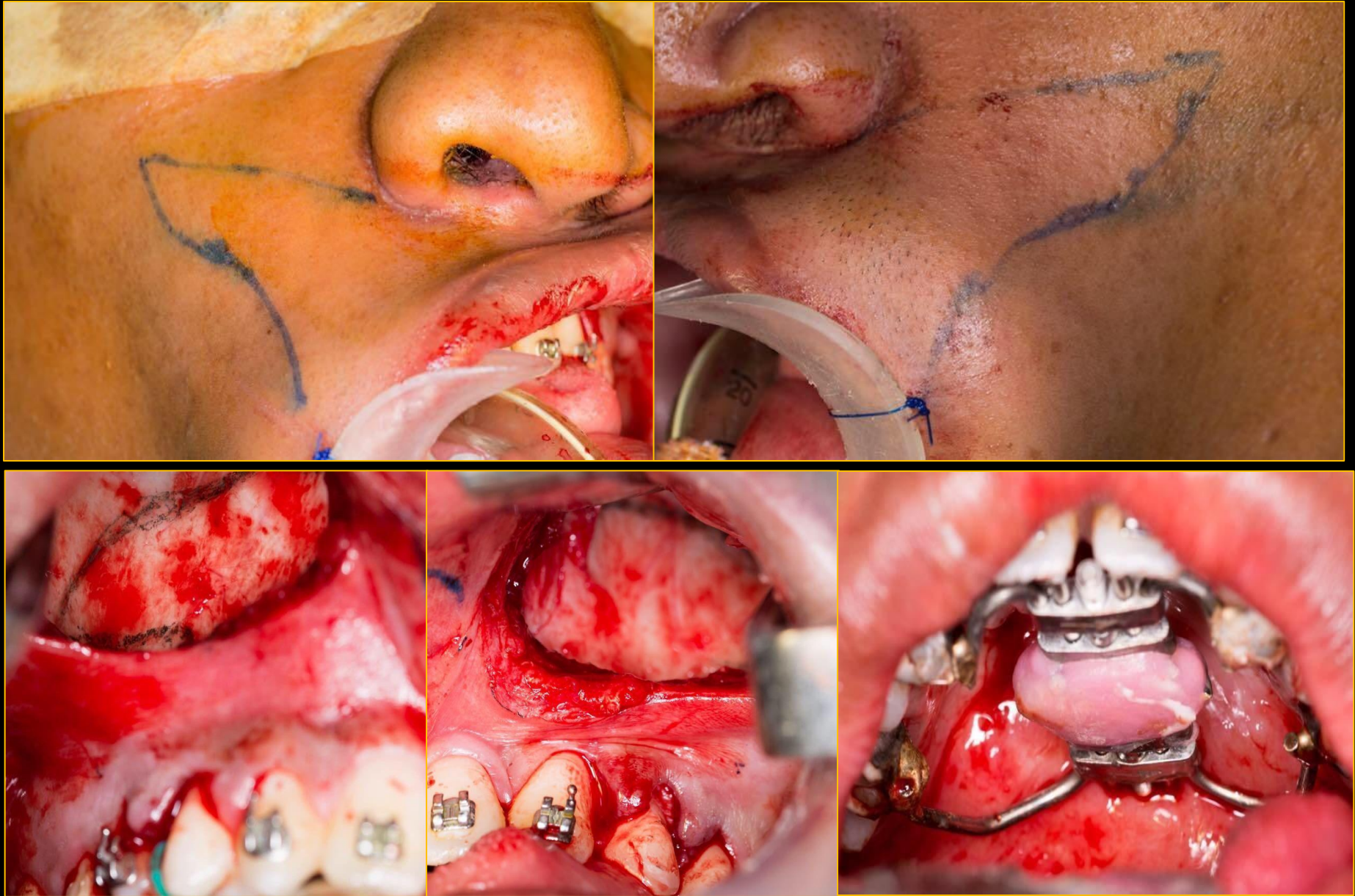
Intraop



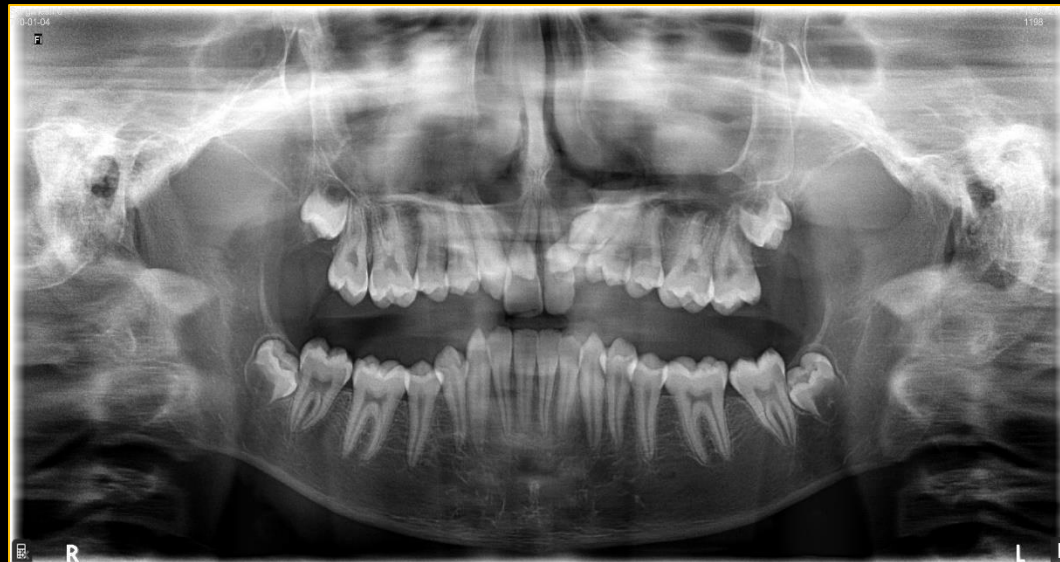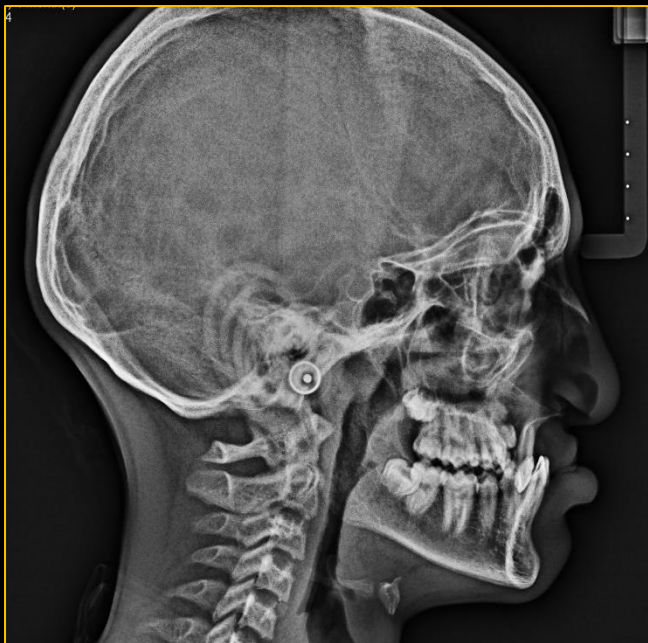Pre and Post-Op X- rays



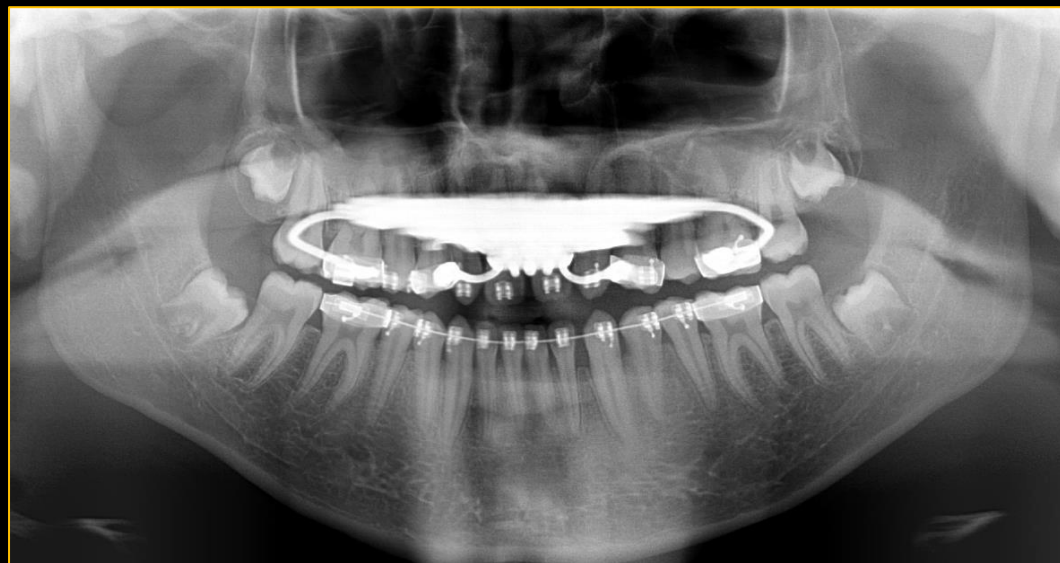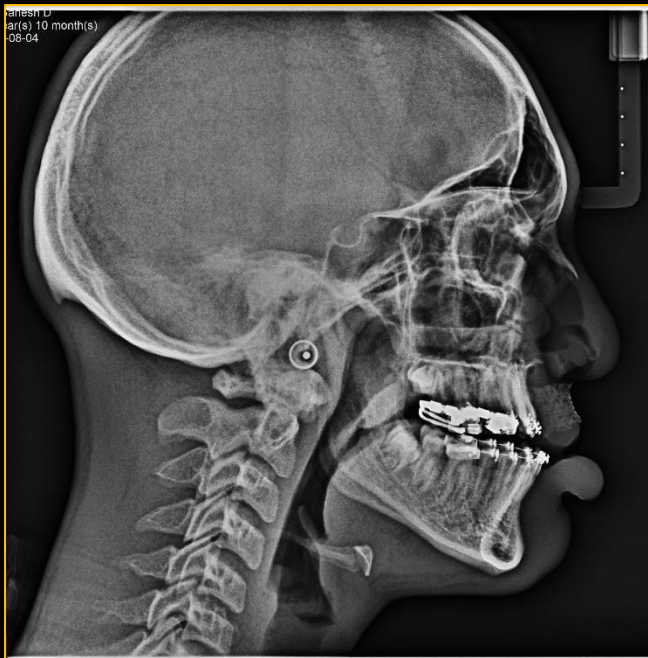Modified AMD with winged osteotomy



P
R
E
O
P



P
O
S
T
O
P





Contents lists available at ScienceDirect

Journal of Oral Biology and Craniofacial Research

journal homepage: www.elsevier.com/locate/jobcr



Modified anterior maxillary distraction using “Winged Osteotomy”: A technical note



Srinivas Gosla Reddy^{a,*}, Adity Bansal^{a,*}, Nisha Sharma^b, Ashi Chug^a

^a Department of Dentistry (Cranio-maxillofacial Surgery), AIIMS Rishikesh, Uttarakhand, 249203, India

^b GSR Institute of Craniomaxillofacial and Facial Plastic Surgery, Vinay Nagar Colony, Saroor Nagar West, Saidabad, Sarvornagar, Telangana, Hyderabad, 500059, India

ARTICLE INFO

Keywords:

Cleft maxilla

Anterior maxillary distraction

Winged osteotomy

Maxillary hypoplasia

Modified anterior maxillary distraction

ABSTRACT

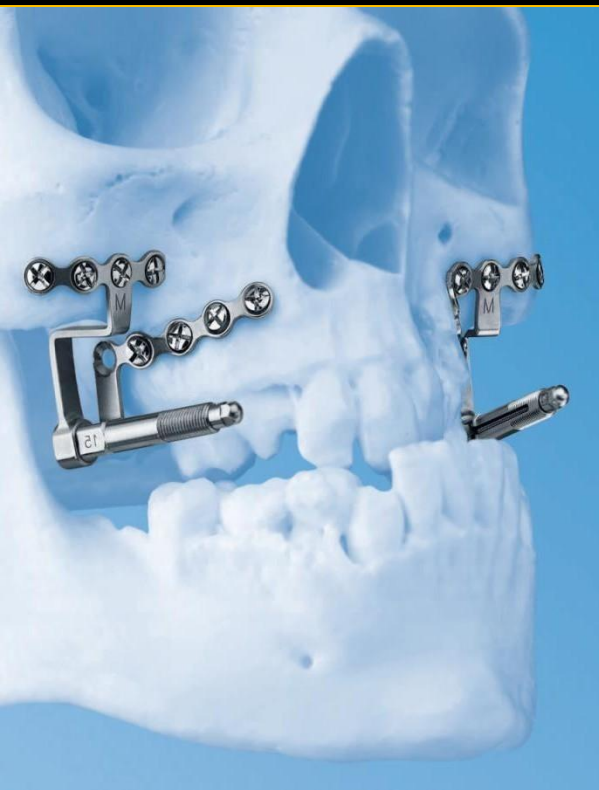Hypoplasia of the maxilla is common in cleft lip and palate (CLP) deformities. Orthognathic surgery has been the traditional method of correction in such developmental anomalies since 1970's, with Le-Fort I advancement as its long-established management modality, which results in significant speech alteration and relapse rate. In contrast, anterior maxillary distraction (AMD) has the advantage of lesser chances of relapse, velopharyngeal insufficiency, and alteration of speech. This modified AMD technique carries a handful of its advantages as it is an easier procedure compared to the Le-Fort I osteotomy as it gives positive soft tissue changes by improving the projection of the nose and the upper lip, normalizes naso-labial angle, and changes the facial prominence from concave to convex simultaneously as it gives nasolabial and sub-malar prominence post-operatively due to the extension of horizontal cuts up to the zygomatic region, leading to lesser complications. Also, the hollowing caused by the conventional AMD osteotomy cuts is eliminated by the extension of the winged osteotomy.

* Corresponding author. Department of Dentistry (Cranio-maxillofacial Surgery), AIIMS Rishikesh, Uttarakhand, 249203, India. E-mail addresses: goslareddy@gmail.com (S. Gosla Reddy), aditybansal@rediffmail.com (A. Bansal), sharmanishaashok@gmail.com (N. Sharma), ashichug@gmail.com (A. Chug). <https://doi.org/10.1016/j.jobcr.2021.05.005> Received 25 February 2021; Received in revised form 2 May 2021; Accepted 4 May 2021 Available online 8 May 2021 2212-4268/© 2021 Craniofacial Research Foundation. Published by Elsevier B.V. All rights reserved

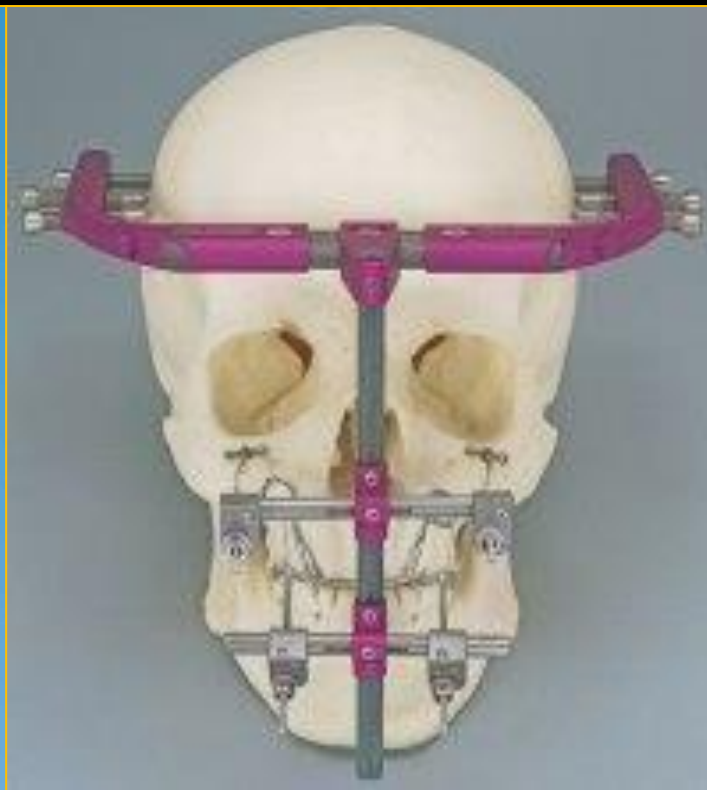


Midface Distraction for Maxilla

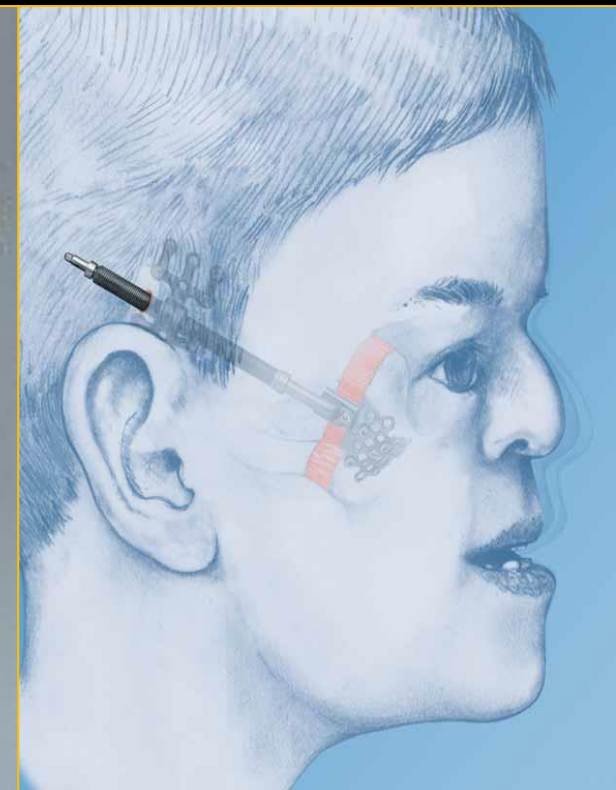




Internal Pull
Distraction



External Pull
Distraction



Internal Push
Distraction

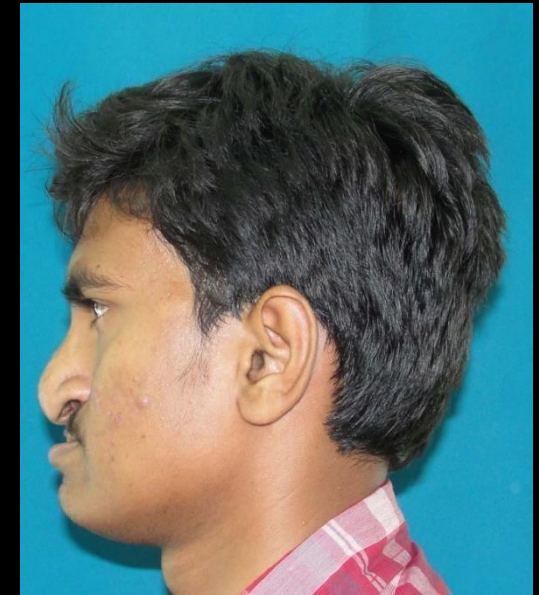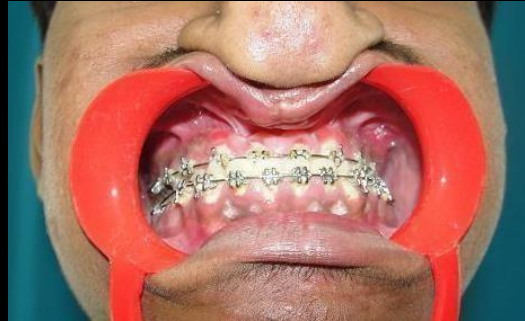	Advantages	Disadvantages
External device	Multidirectional lengthening with angular adjustment possible during distraction	Patient apprehension to wear bulky external devices
	Relatively simple to apply intraoperatively	Potential permanent facial scarring
	Easy for patient to activate	
	Can be removed without the need for second operative procedure	
Internal device	Absence of facial scars	Design limitations due to limited size of device and restricted access to oral cavity
	Inconspicuous nature of device	
	Better stability of device to bone	

Distraction Osteogenesis in Oral and Craniomaxillofacial Reconstructive Surgery DOI: <http://dx.doi.org/10.5772/intechopen.81055>

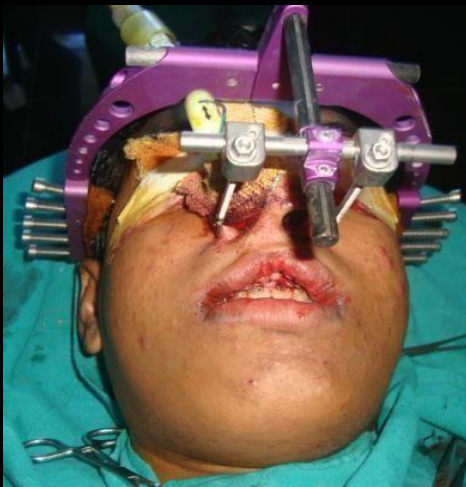




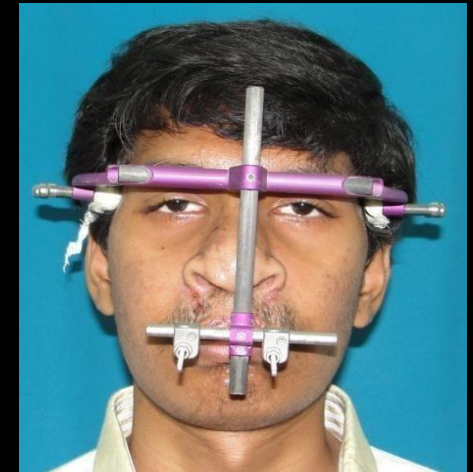Pre-op



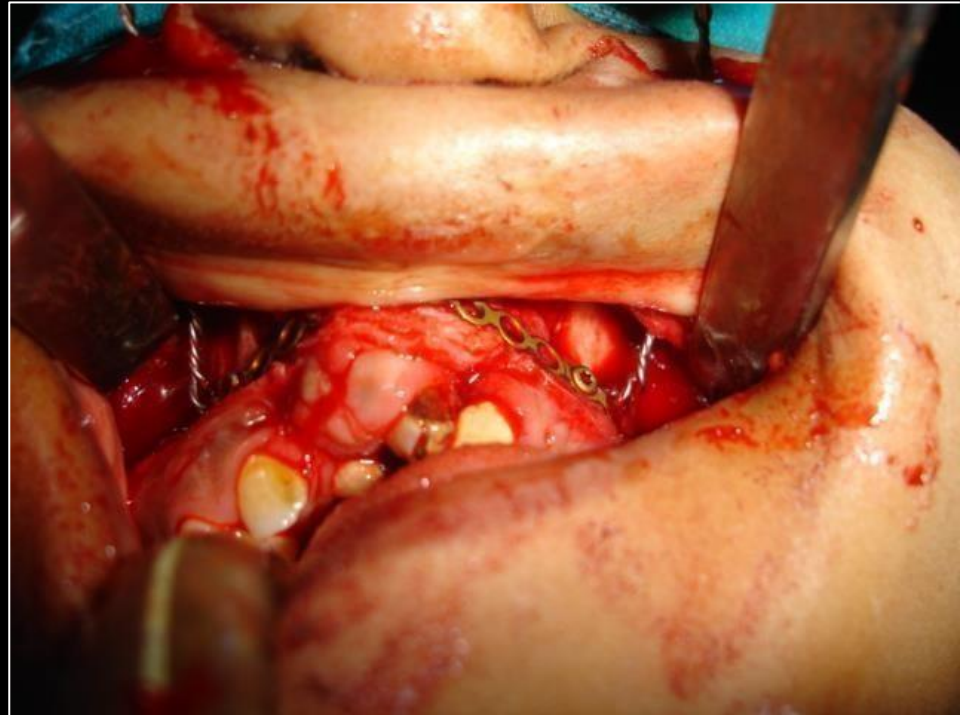
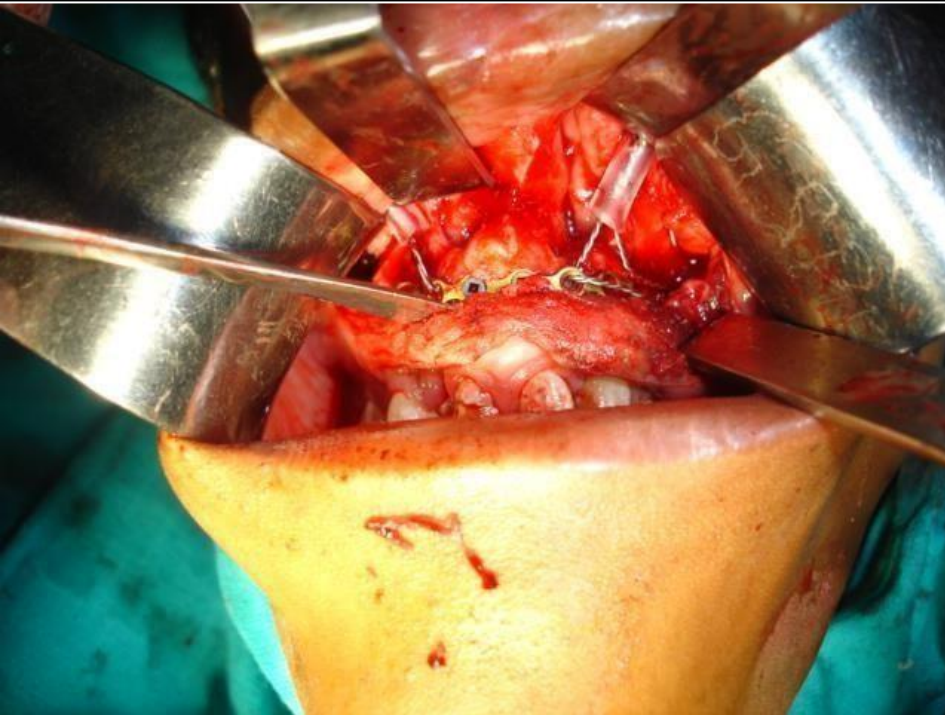
Intra-op



With Frame



Surgical Procedure Distraction

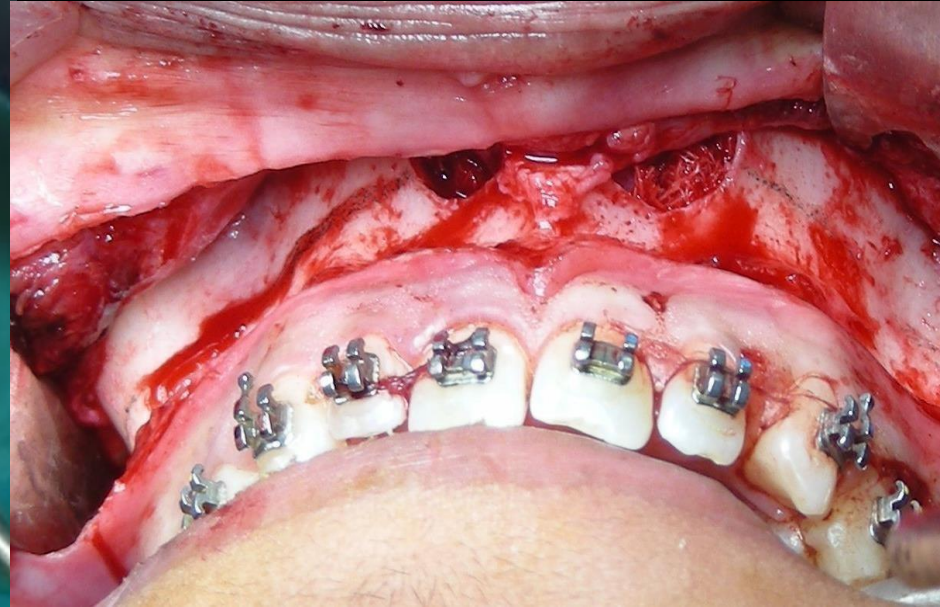
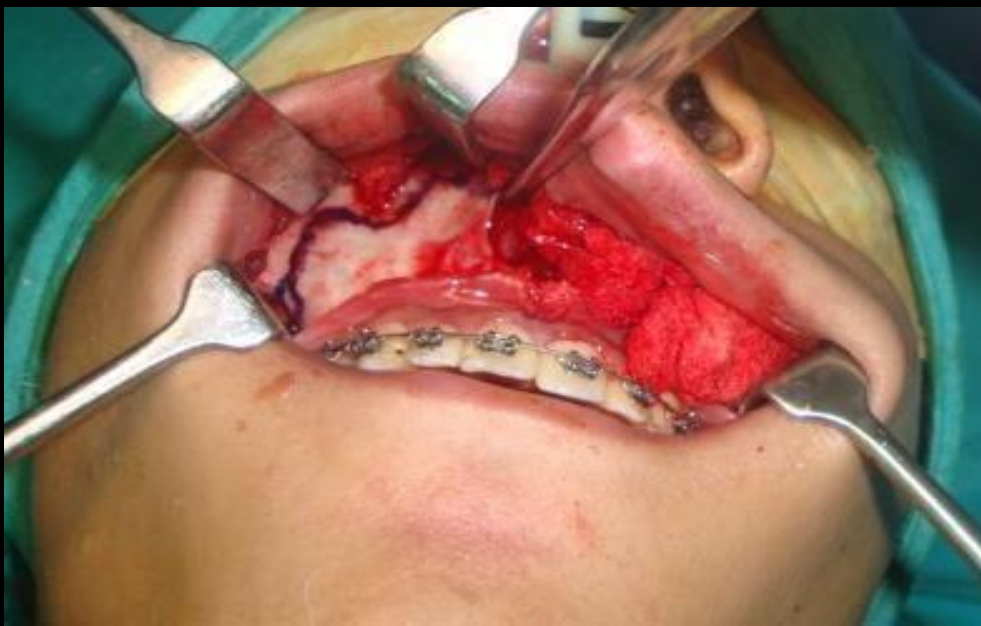

NEED FOR ANTERIOR BONE PLATE

- The anterior bone plate holds all together thereby cleft segments ensuring equal forward movement for all segments.
- It also provides an ideal anchorage for the distraction wires.



Performing a LeFort I Osteotomy

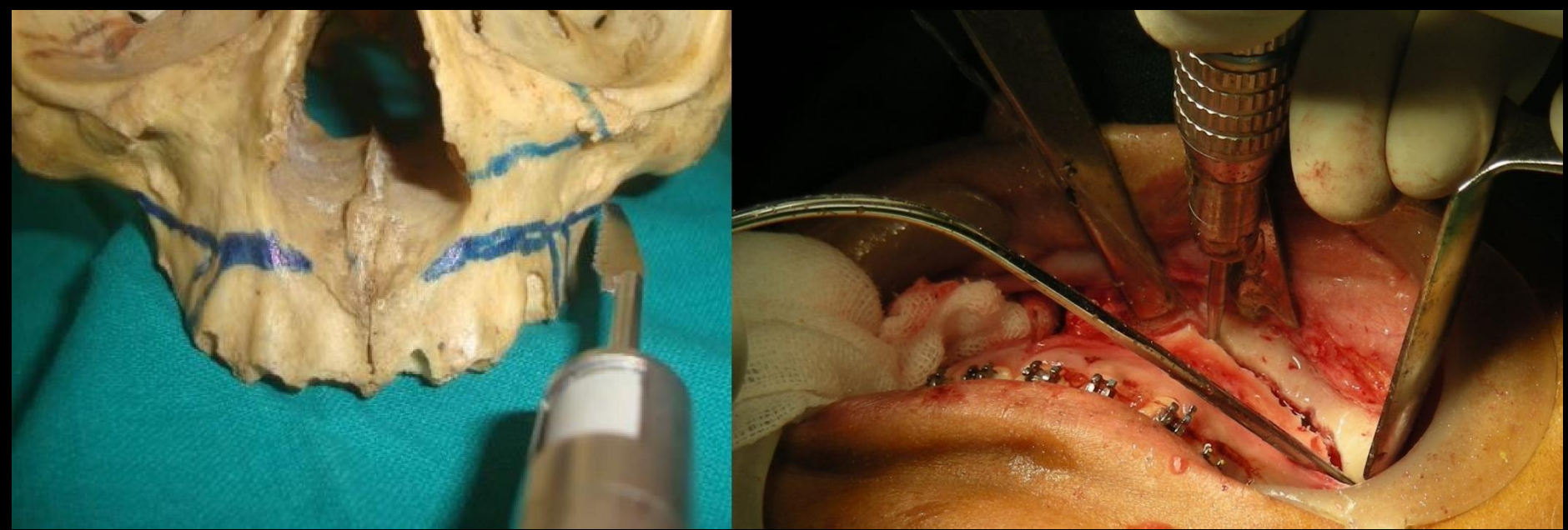


Osteotomy Cut

- The osteotomy cuts are placed 2-3mm higher than the conventional Lefort I ostetomy, to provide a cuff to place the plate and stability to the distracting segment.



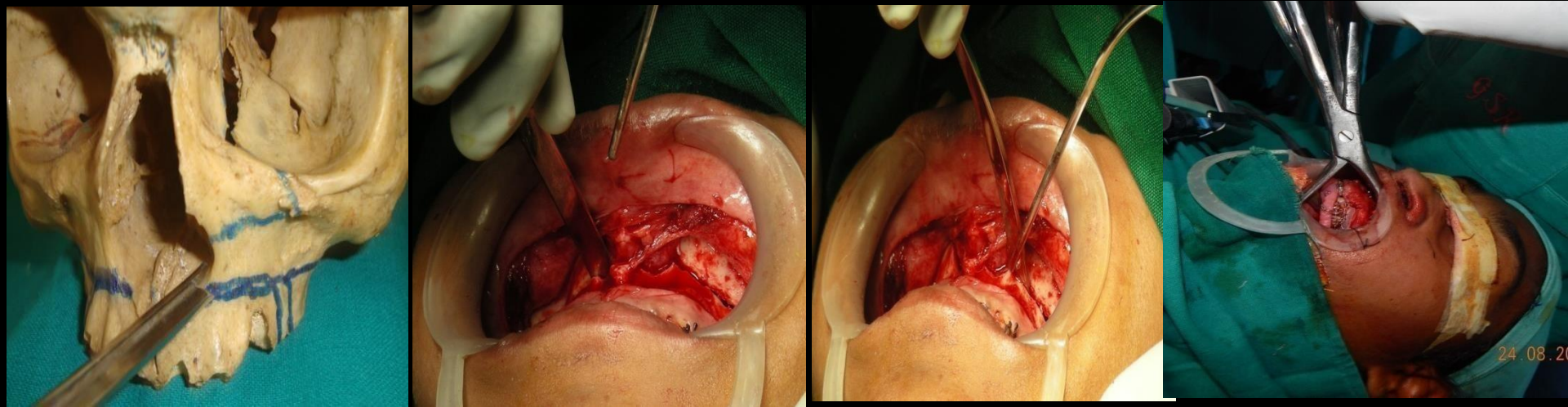
Performing a LeFort I Osteotomy



Anterior buccal osteotomy

- Done with reciprocating Saw with copious irrigation.

Performing a LeFort I Osteotomy

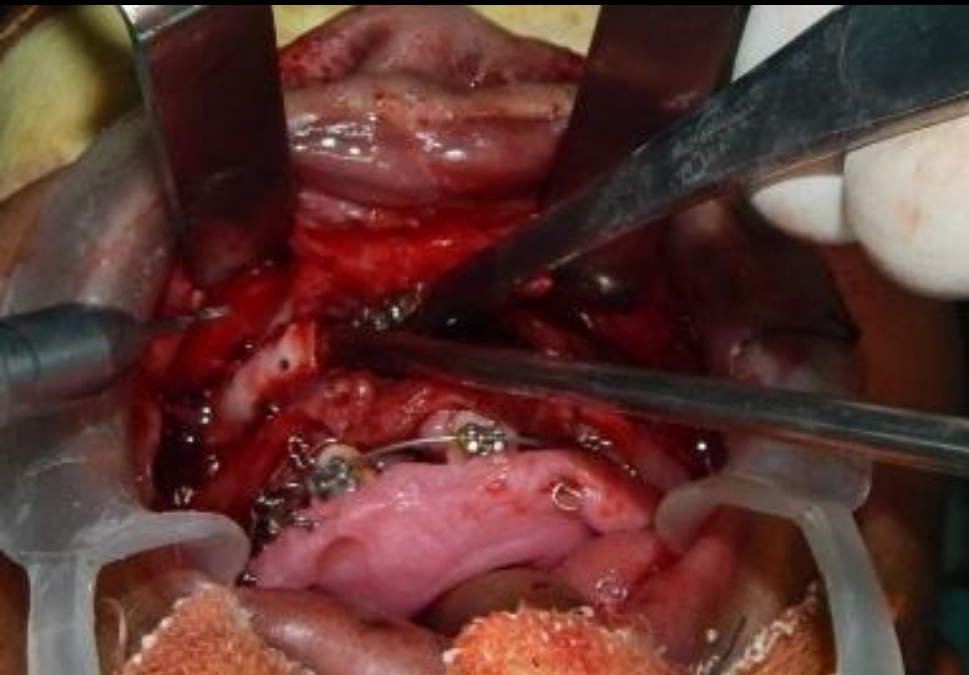

Medial and posterior wall osteotomy

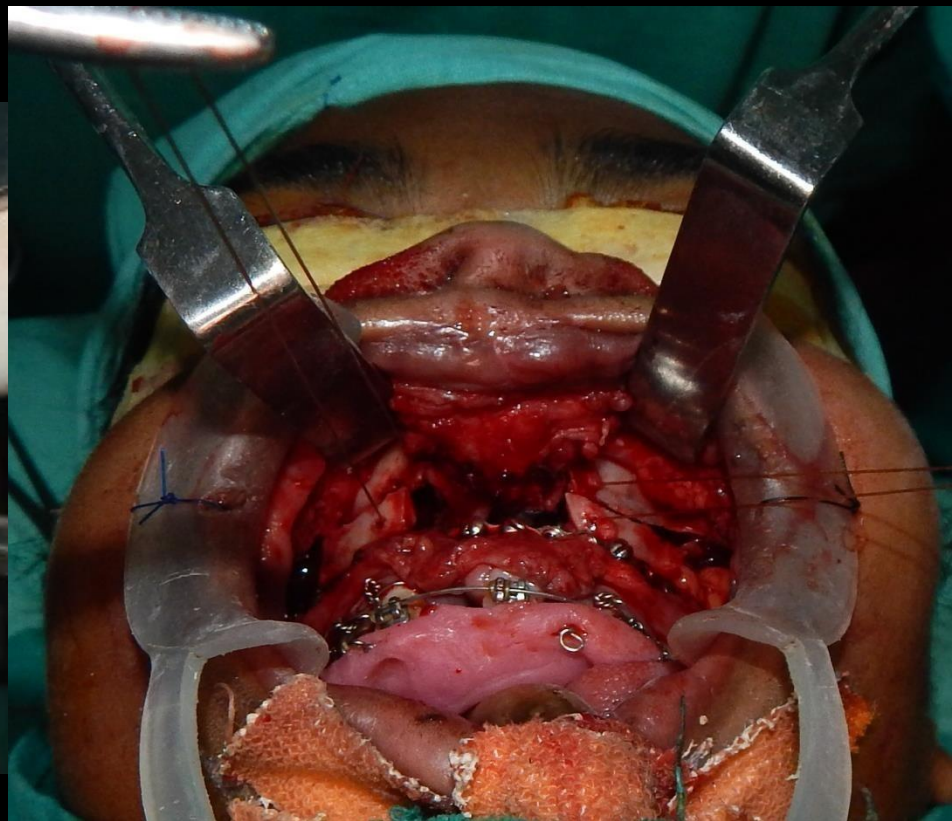
- A thin guarded osteotome is used to tap gently and carefully to fracture the medial (lateral nasal wall) and posterior wall of maxilla.

Lefort I maxillary osteotomy with pterygoid disjunction & down fracture of maxilla is done. (radical mobilization in case of orthognathic surgery & minimal mobilization in distraction)



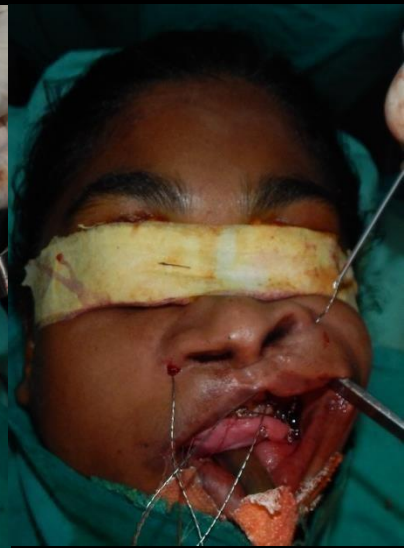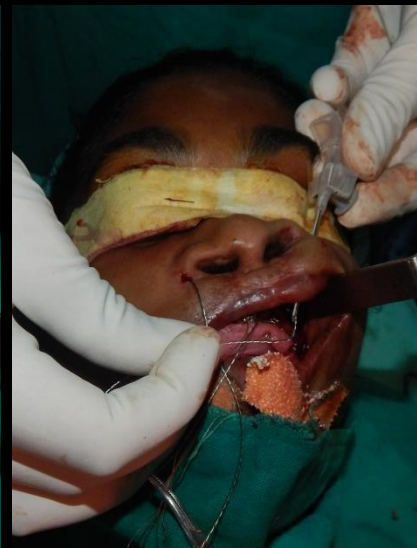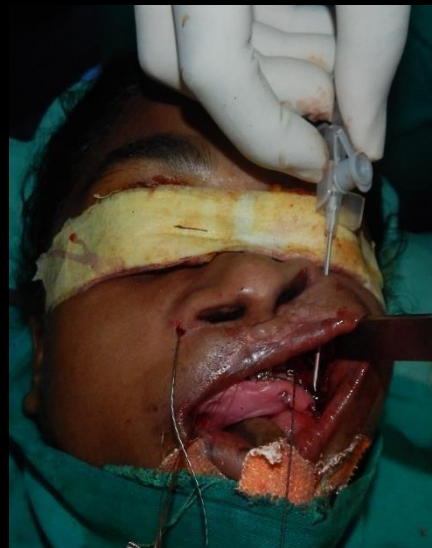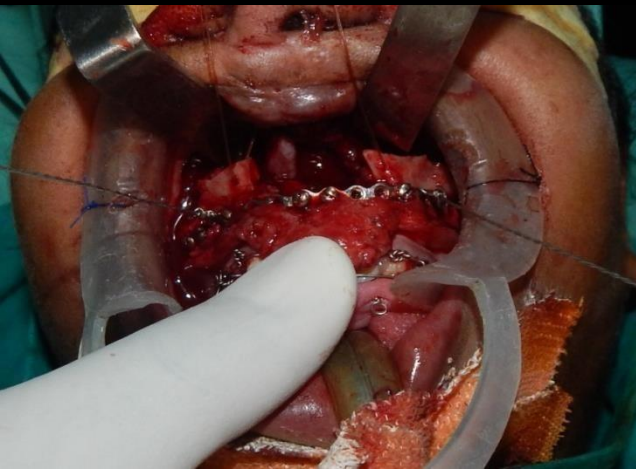


Holes are made on upper & lower segments
with #703 fissure bur



3- 0 Catgut Stay suture is used
for stabilization of segment





Attach double wire to
plates in empty
holes.

Pierce 18 gauge cannula at alar base.

Bring out the double wires through alar base

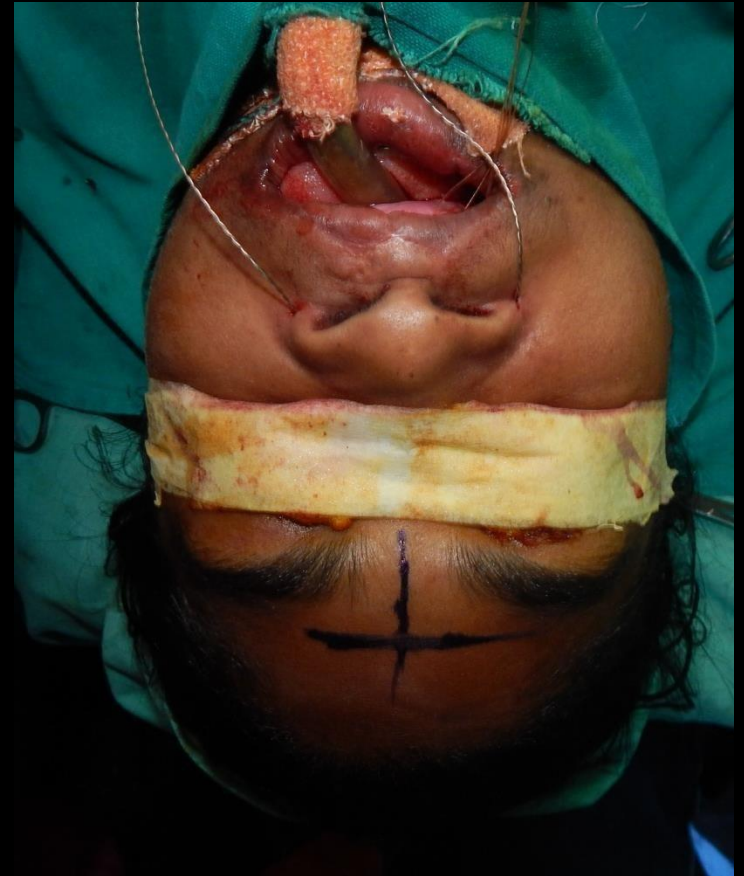

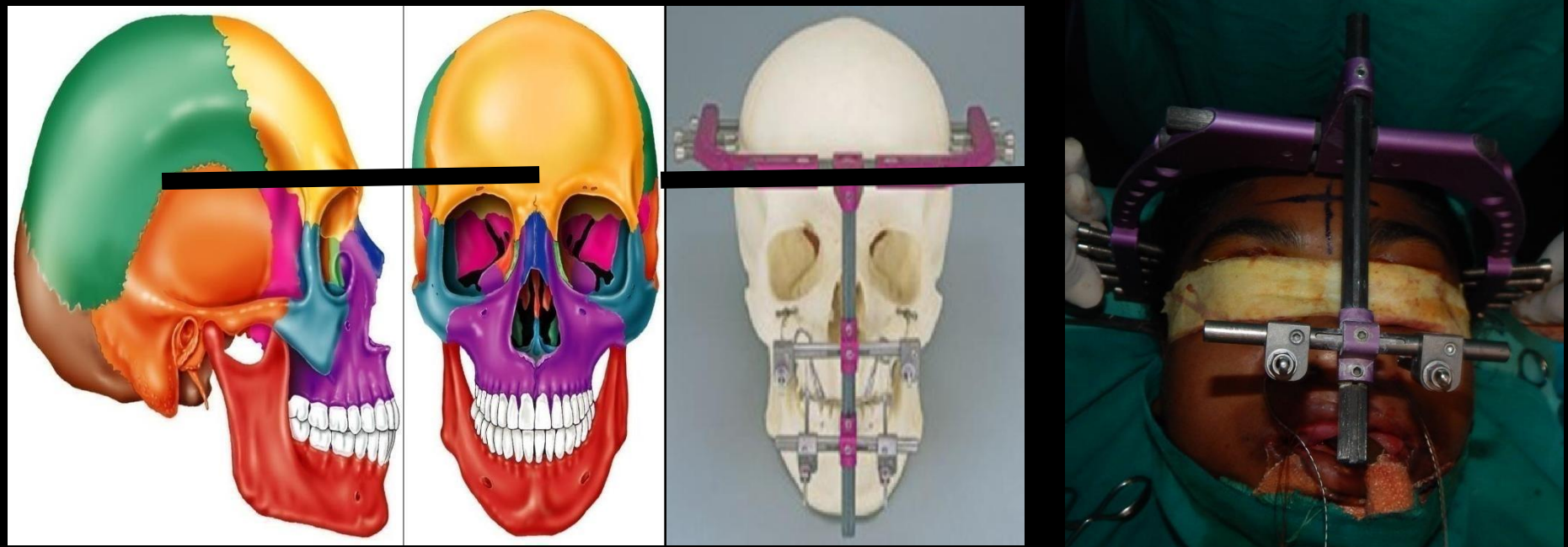
- Removal of head drape
- Painting with betadine in b/l temporal region.

- Marking on the face on forehead.

Vertical :- Midline

Horizontal:- 1 inch above & parallel to
Supra orbital ridge



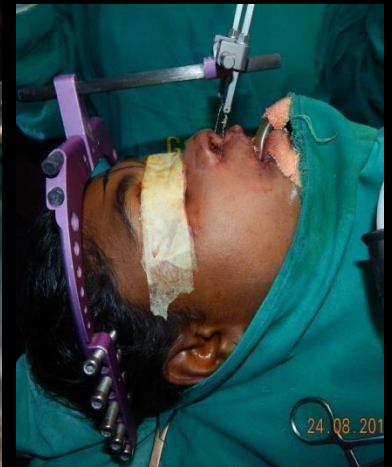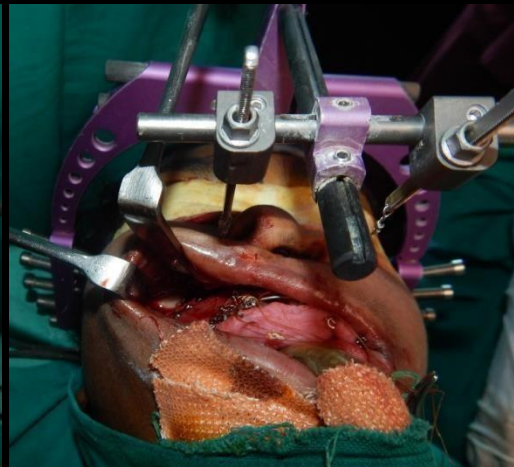
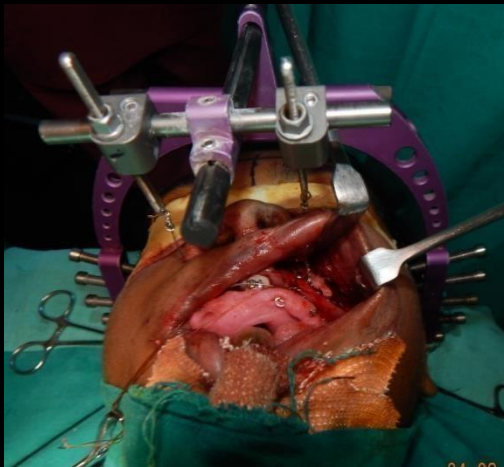

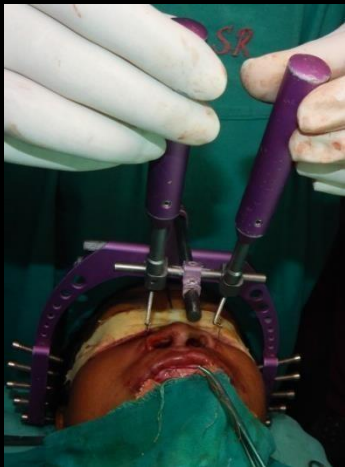
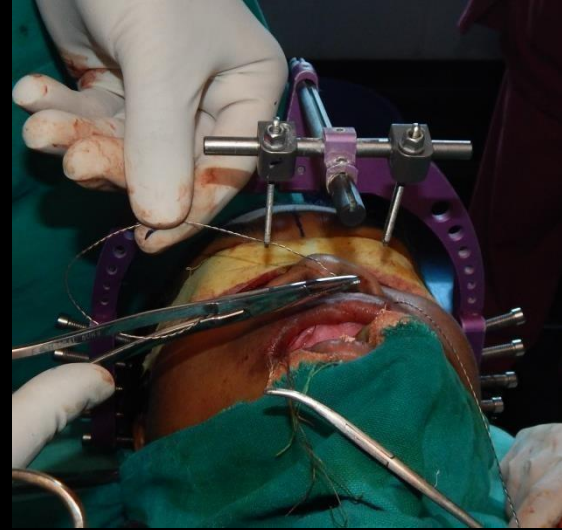- PLACEMENT OF DISTRACTOR

- Anteriorly ensure it placed about 1 inch superiorly to the superior orbital rims
- Laterally ensure it is placed superior to the lateral temporal fossa



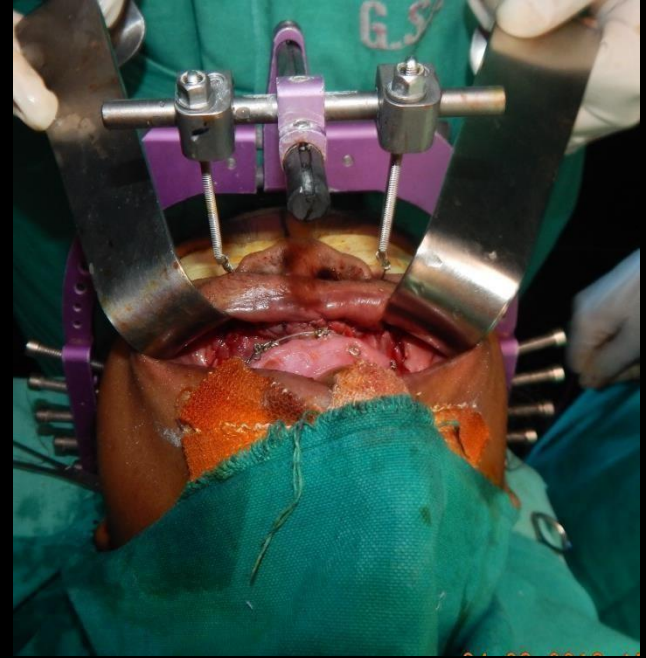
Fix Double wire to Frame



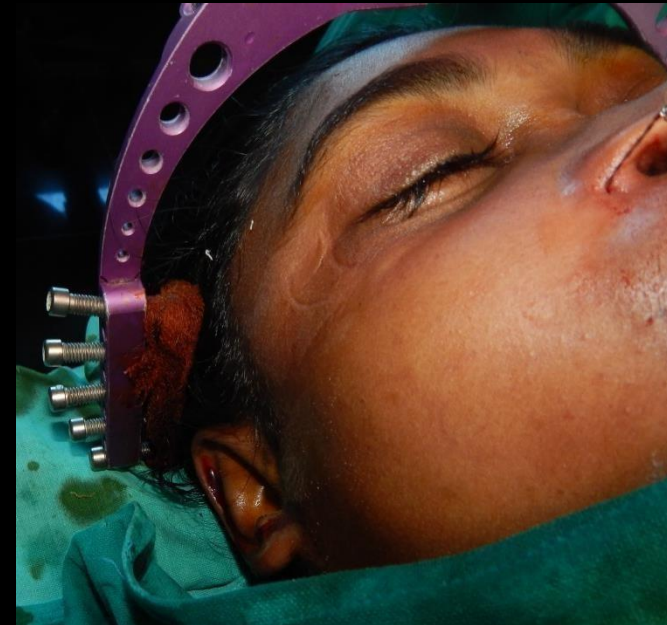Check for complete movement of maxilla with distraction keys & Tie the catgut Suture



V – Y Closure of surgical site with 3-0vicryl.



Placement of B/L Temporal Betadine Dressing.



Distraction Protocol

- Latency period: 5 days following osteotomy and application of the device
- Active distraction: 1 mm per day(Morning,evening)
- Rigid retention(Wire IMF): After complete distraction for 2 months
- Frame removal(under LA): After 1 month of IMF
- Elastic retention (2 oz elastics): 8 weeks -24Hrs (box type) 8 weeks – night use only
2 in posterior & 2 in anterior region
- Radiographs (Post op) : Lateral Cephalogram Immediate post op, 3 months, 6 months,1 year



Complications

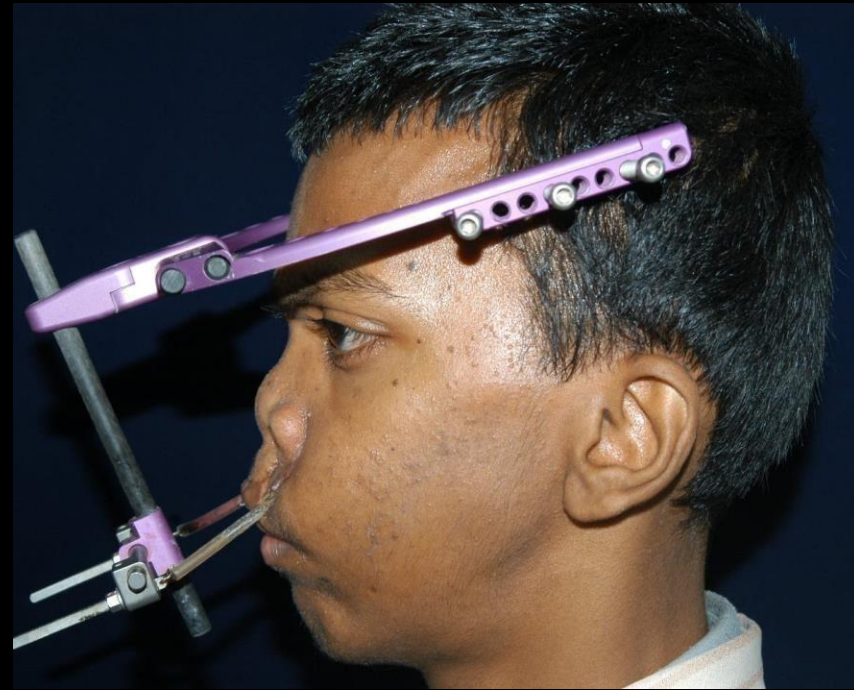
• Intra operative Complications

- Hemorrhage
- Bad Split/Fracture
- Nerve injury
- Damage to the tooth buds

Postoperative Complications

-Intradistractor

- Pin infections, Pin and device loosening
- Device failure
- Inappropriate distractor vector/Frame migration
- Premature consolidation
- Coronoid process interference
- Fibrous Pseudoarthrosis
- Trismus
- Stalling of maxilla



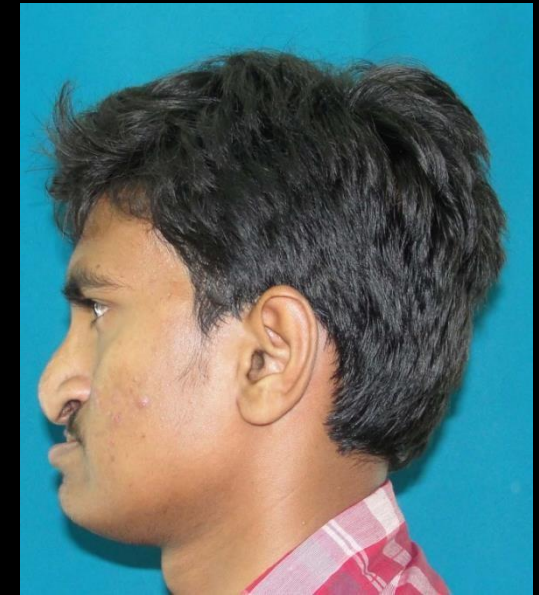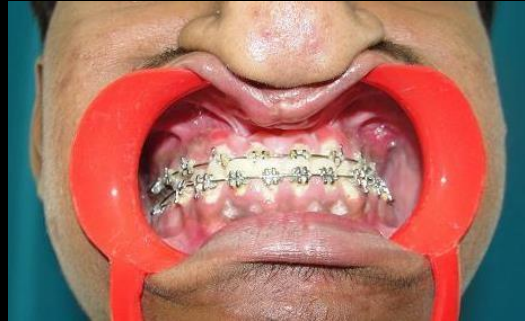Postdistractor

- Delayed Consolidation
- Premature Consolidation
- Malocclusion
- Growth Disturbances
- Malunion
- Nonunion

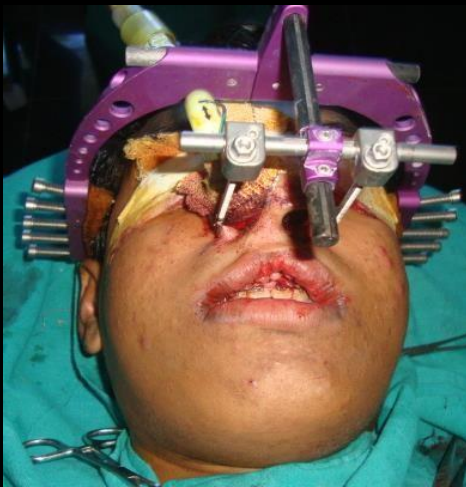

DISTRACTION -RED

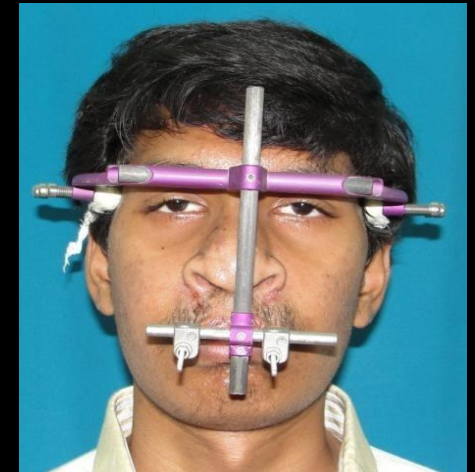Pre-op



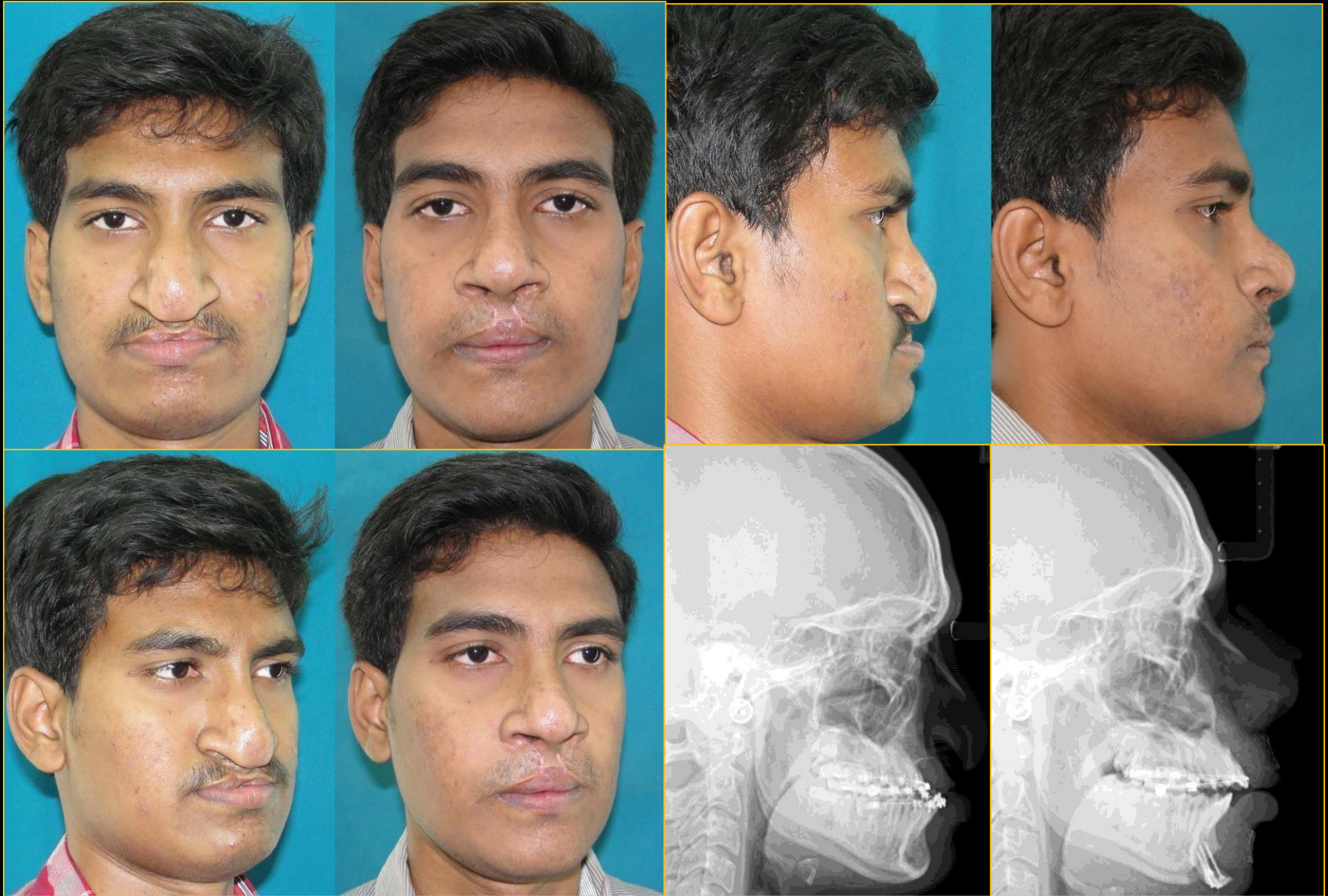Intra-op



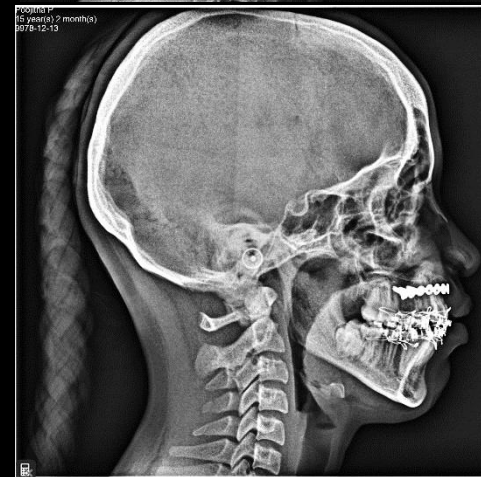
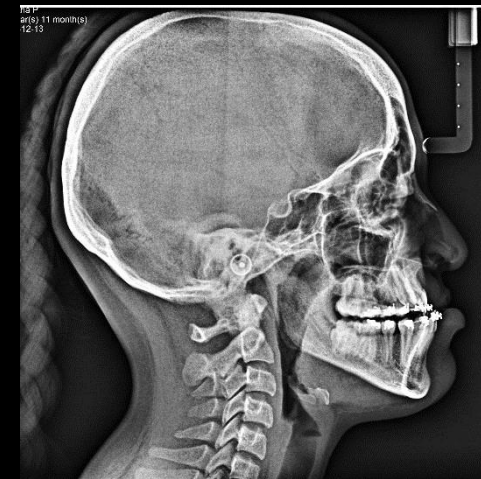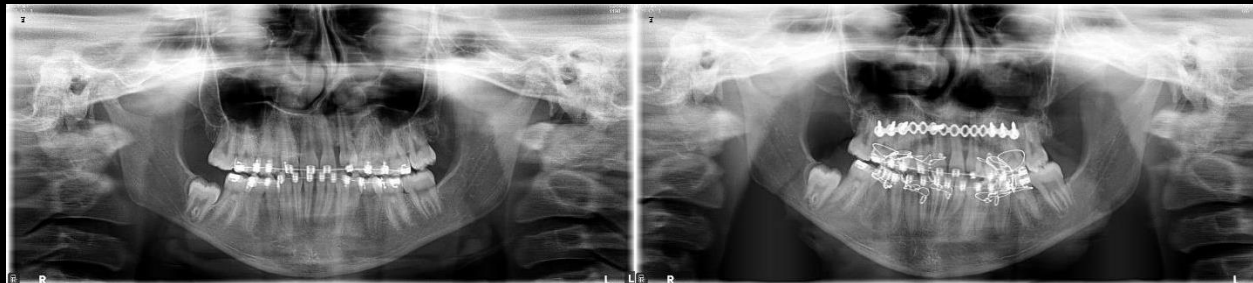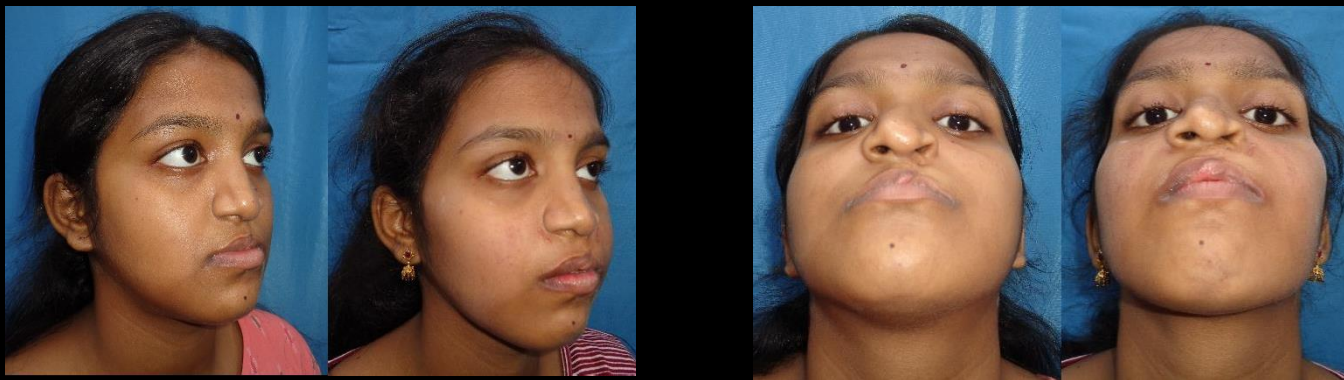With Frame



Long term outcomes..



DISTRACTION -RED



LEFORT II OSTEOTOMY

Indications

- To move the naso-maxillary complex anteriorly



LeFort II Osteotomy

- Does not provide a stable movement due to a 3 point movement
- Does not provide a predictable movement.
- Preference can be given to do a LeFort I advancement with Nasal reconstruction



Performing a LeFort II Osteotomy

Skin Incision

Bicoronal incision as far forward and anterior as possible

+

Labial sulcus incision

OR

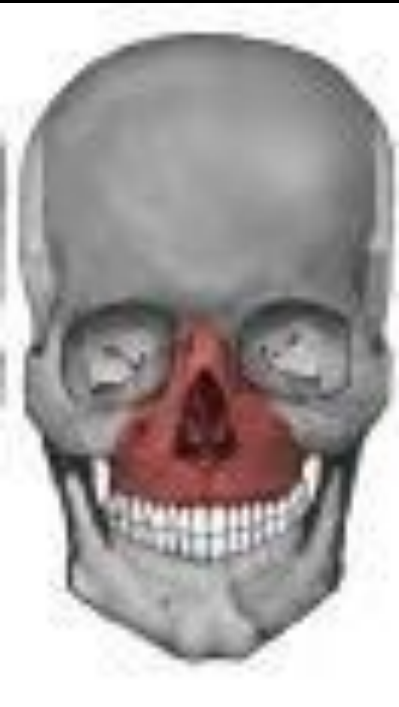Incision on the naso frontal area

+

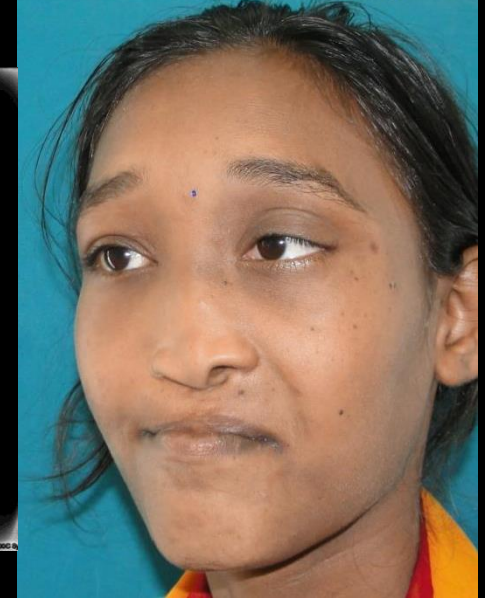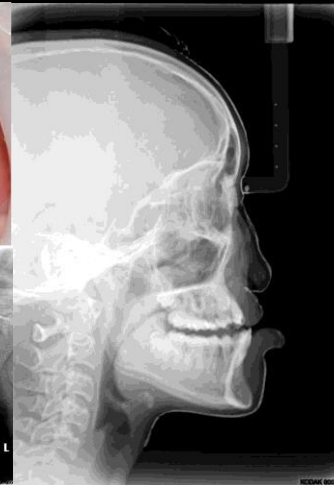
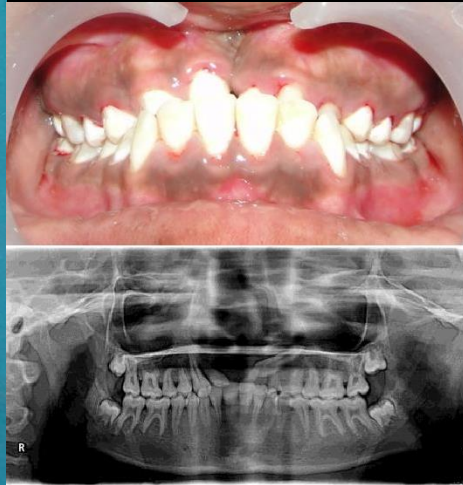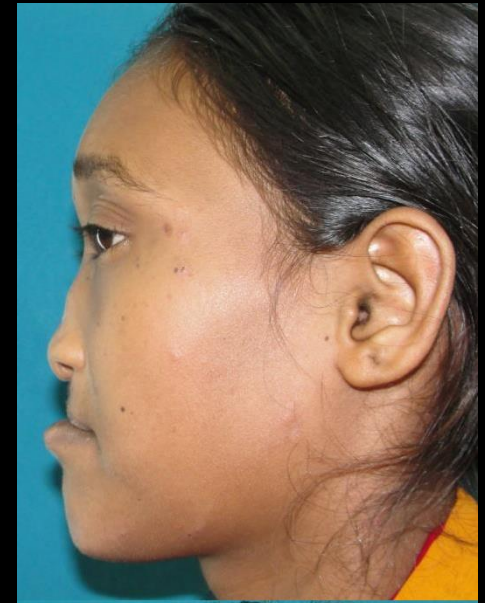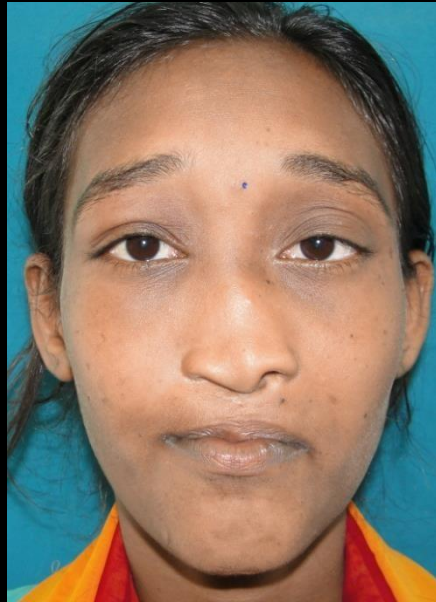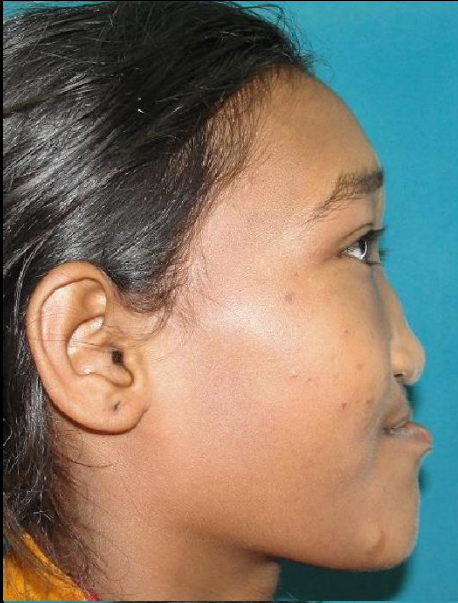Labial sulcus incision

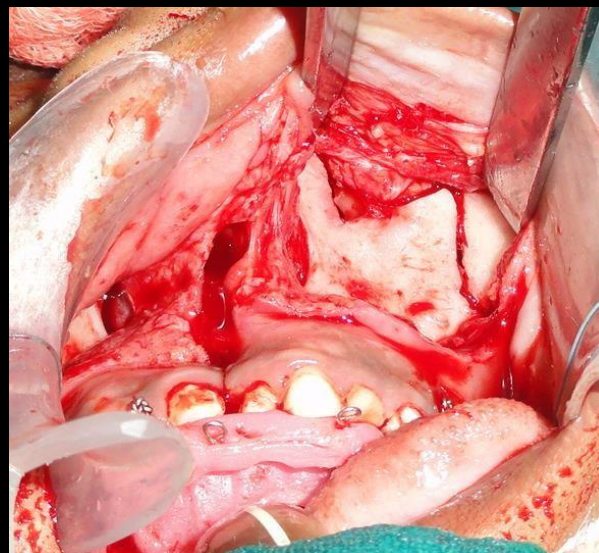
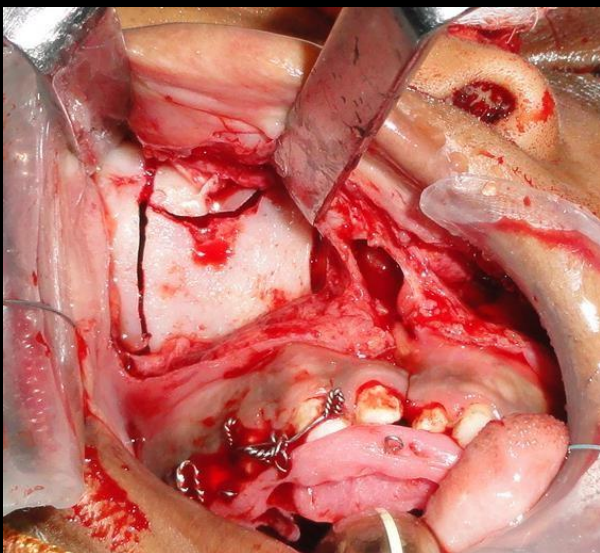
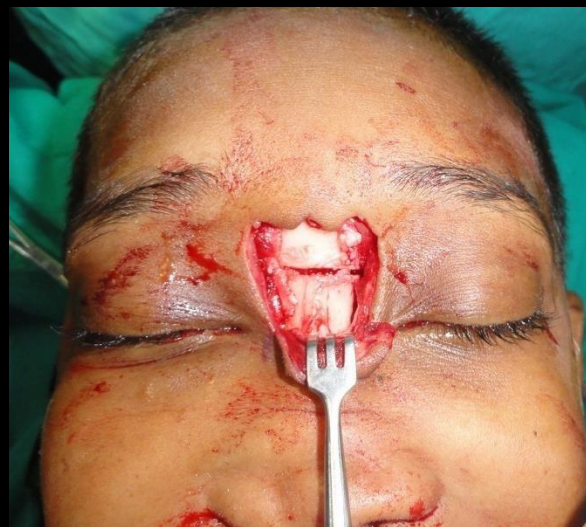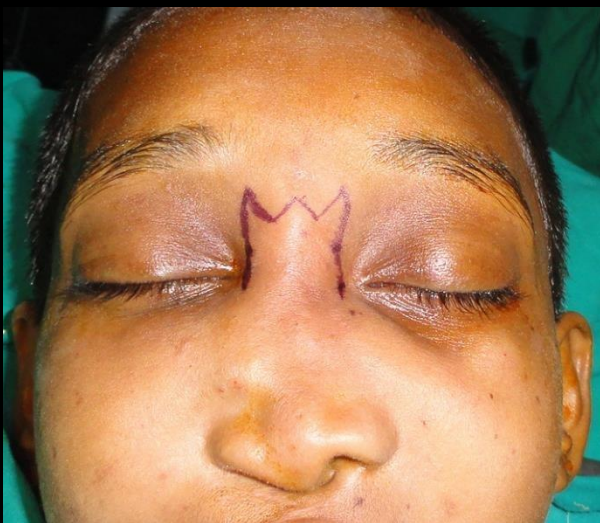LEFORT II OSTEOTOMY

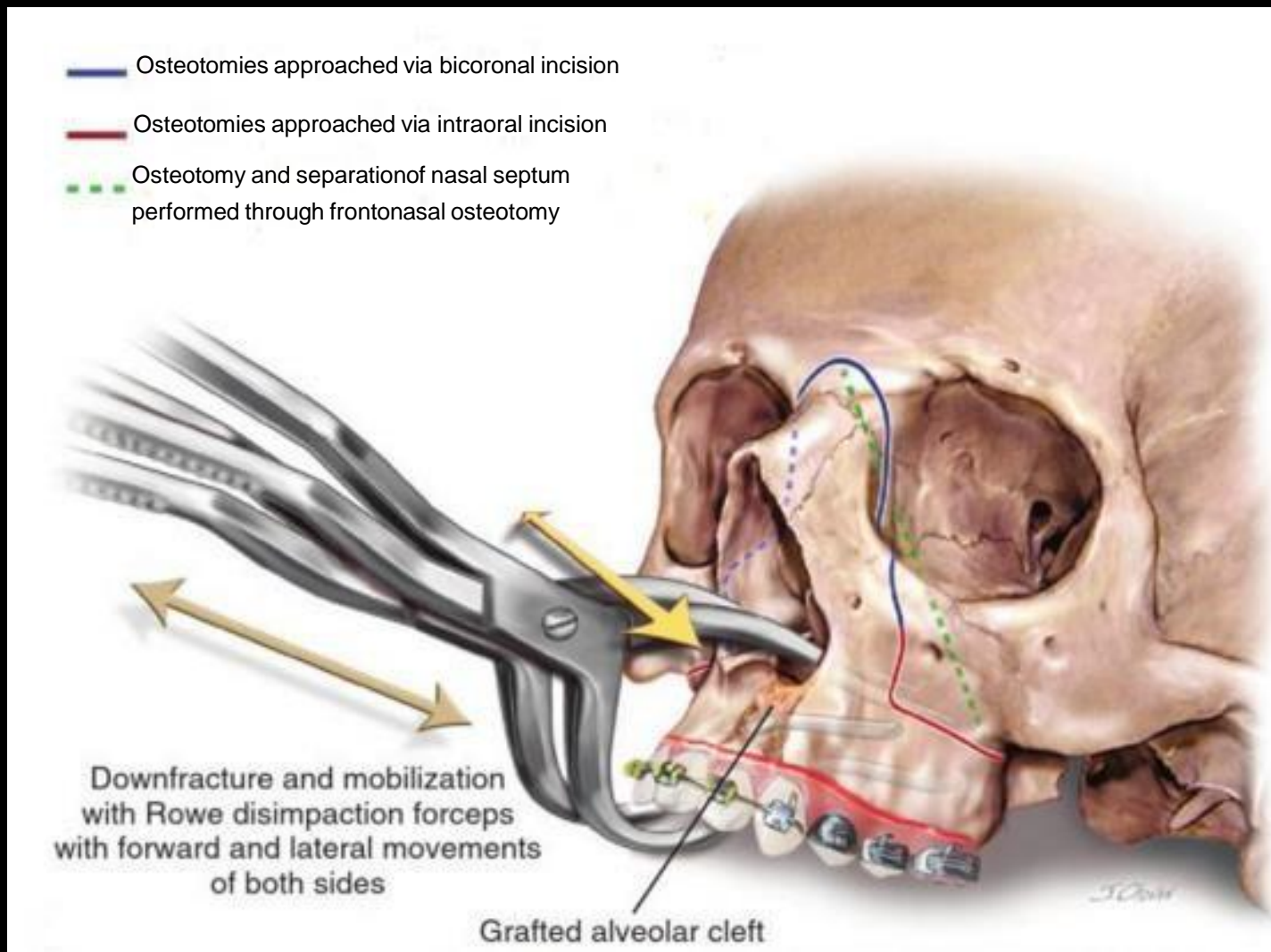
- ❑ A pyramidal maxillary osteotomy.
- ❑ The osteotomy line extends from
 - pterygoid region on one side,
 - underneath the zygomaticomaxillary buttress
 - up over the medial portion of the infraorbital rim,
 - behind the lacrimal bone
 - along the medial wall of the orbit
 - to the dorsum of the nose



PREOP

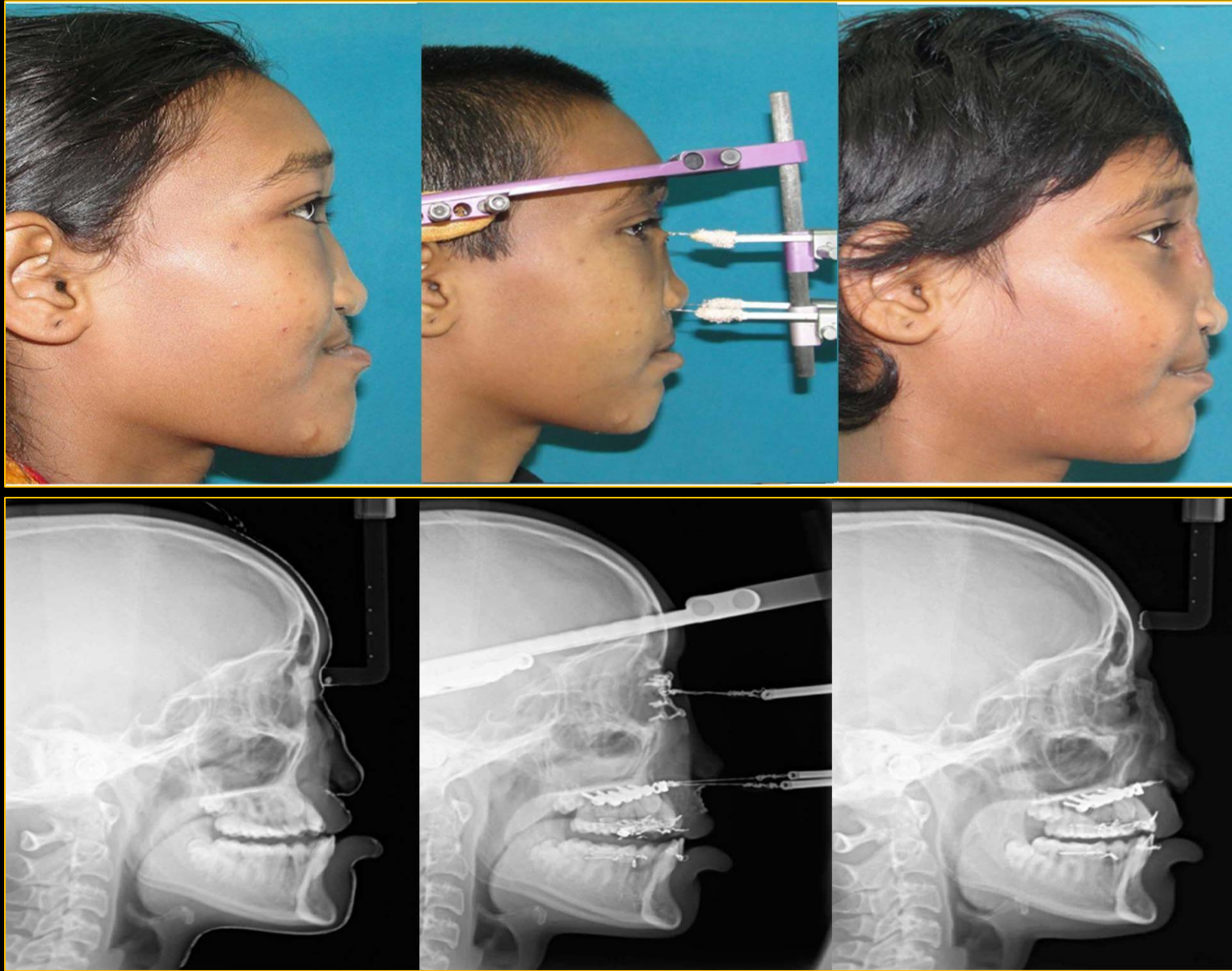




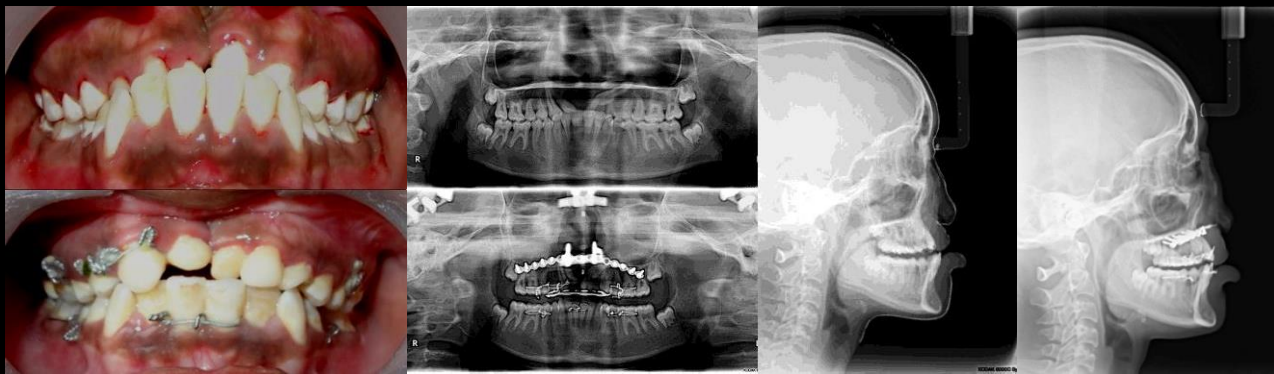
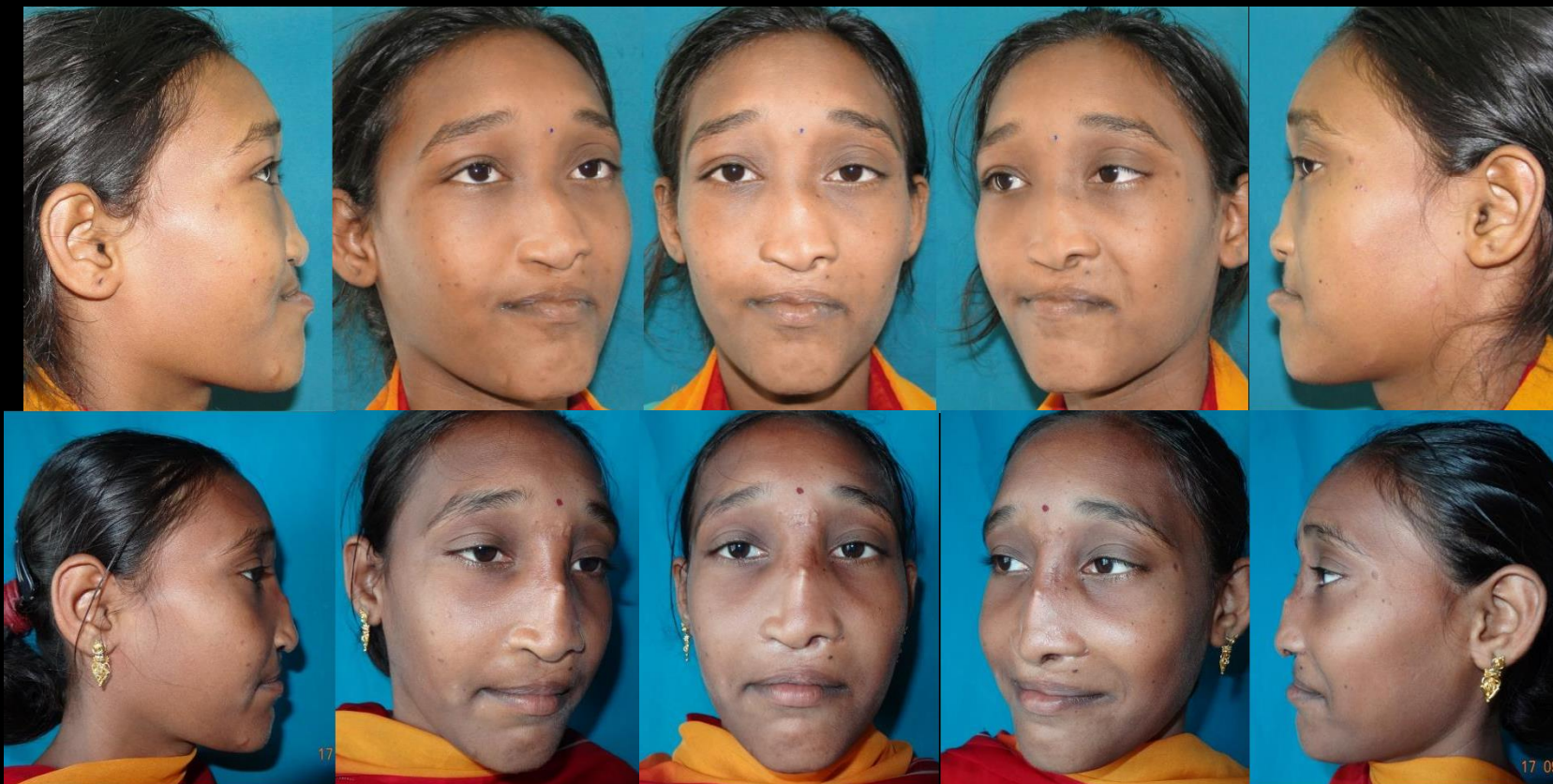

Courtesy :
 Kademani D, Tiwana P. Atlas of Oral and Maxillofacial Surgery , Elsevier Health Sciences - US;
 1 edition. 2015

LeFort II Distraction



PREOP VS POST OP



LEFORT III OSTEOTOMY

INDICATION

➤ Deficiency affecting

- Maxilla
- Malar
- Infraorbital area
- Nasofrontal area



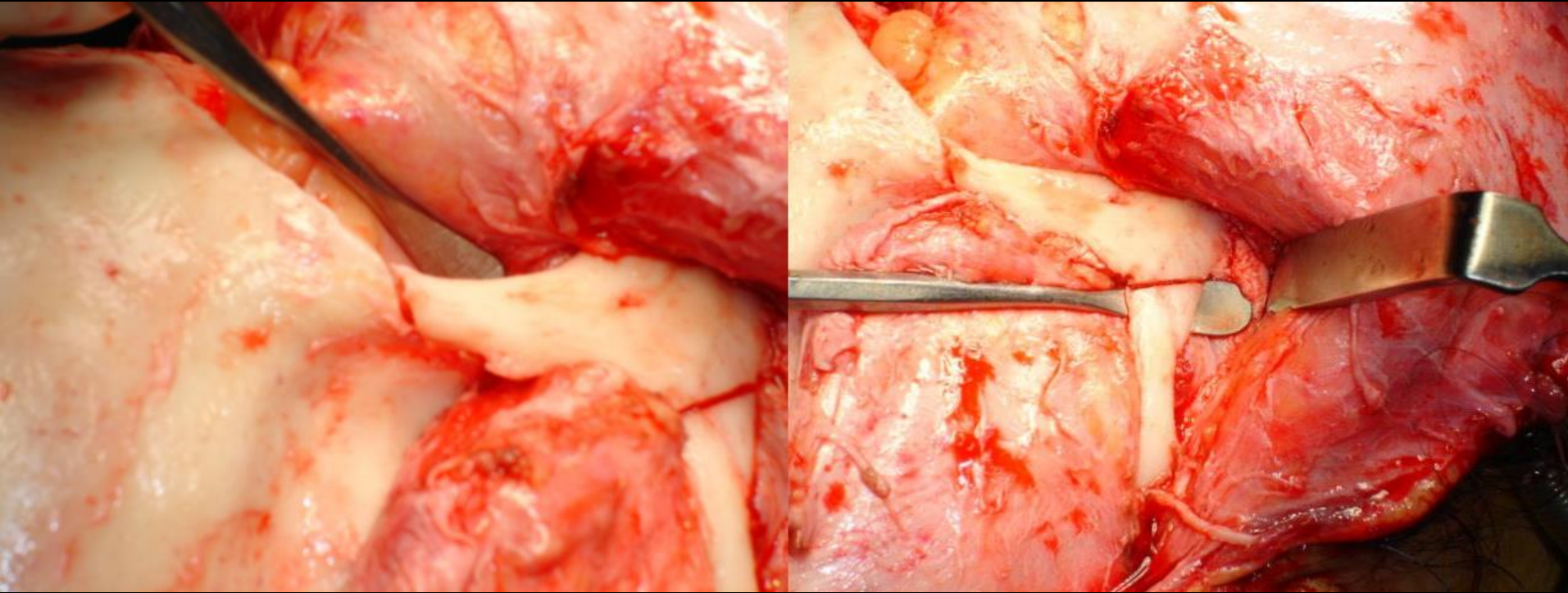
Total Midface Hypoplasia

➤ Von Binders syndrome (**Maxillo-nasal dysplasia**)

Performing a LeFort III Osteotomy

Frontozygomatic suture osteotomy and dysjunction of zygomatic arch is done

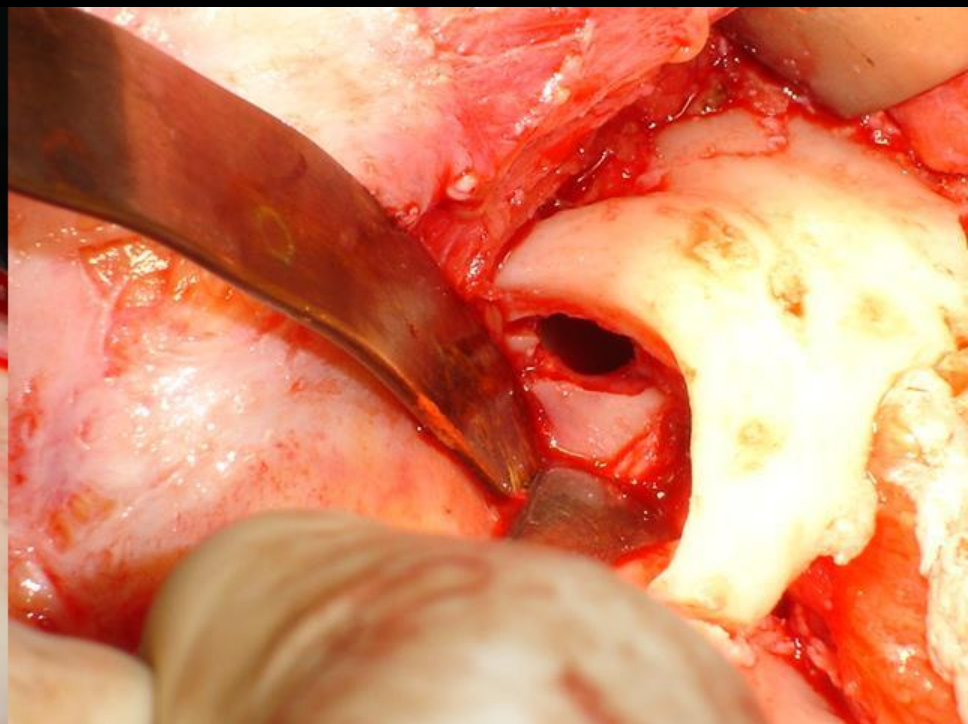
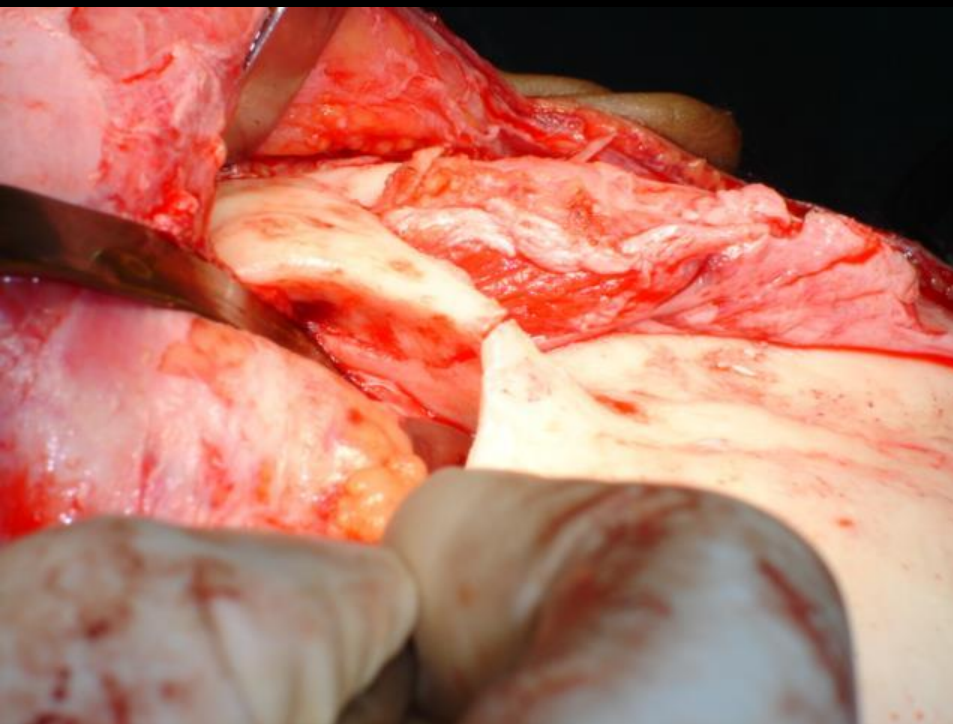
Orbital osteotomy along the lateral aspect of the internal orbit is done



Performing a LeFort III Osteotomy

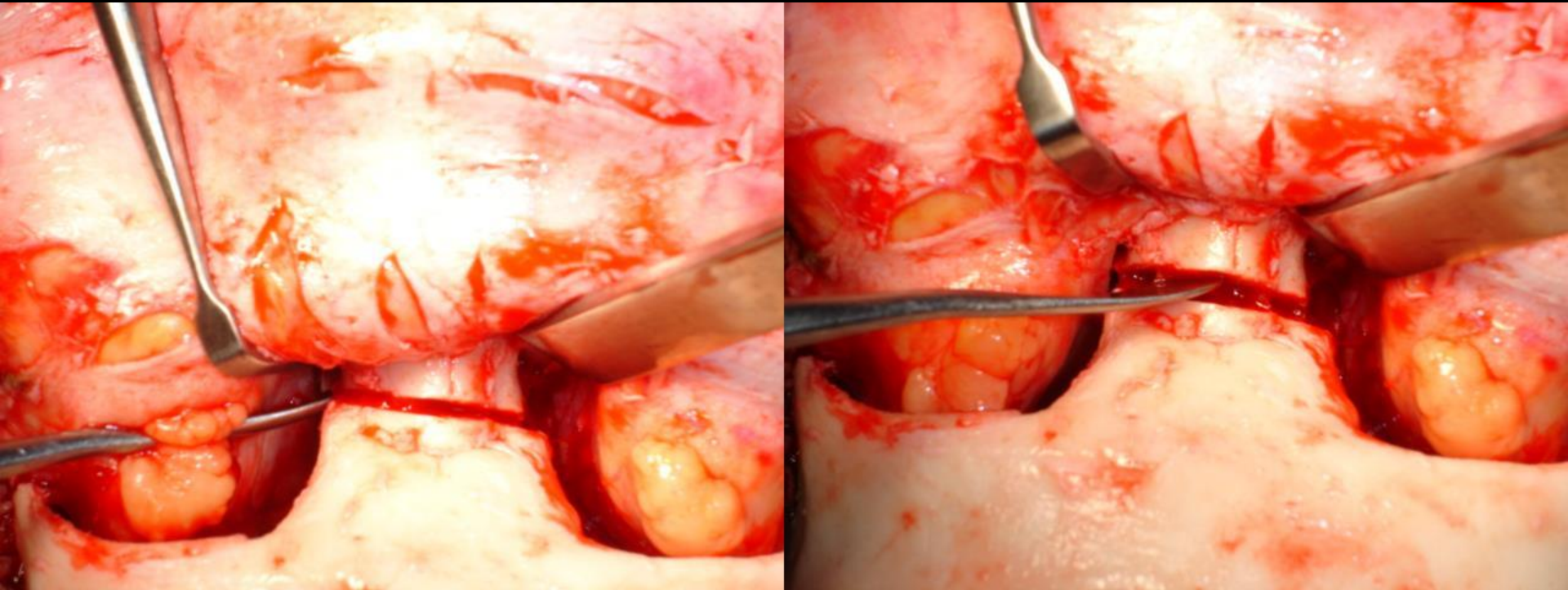
The osteotomy is continued along the sphenozygomatic suture line to the inferior orbital fissure.

The osteotomy then extends medially across the floor of the orbit up the medial wall of the orbit



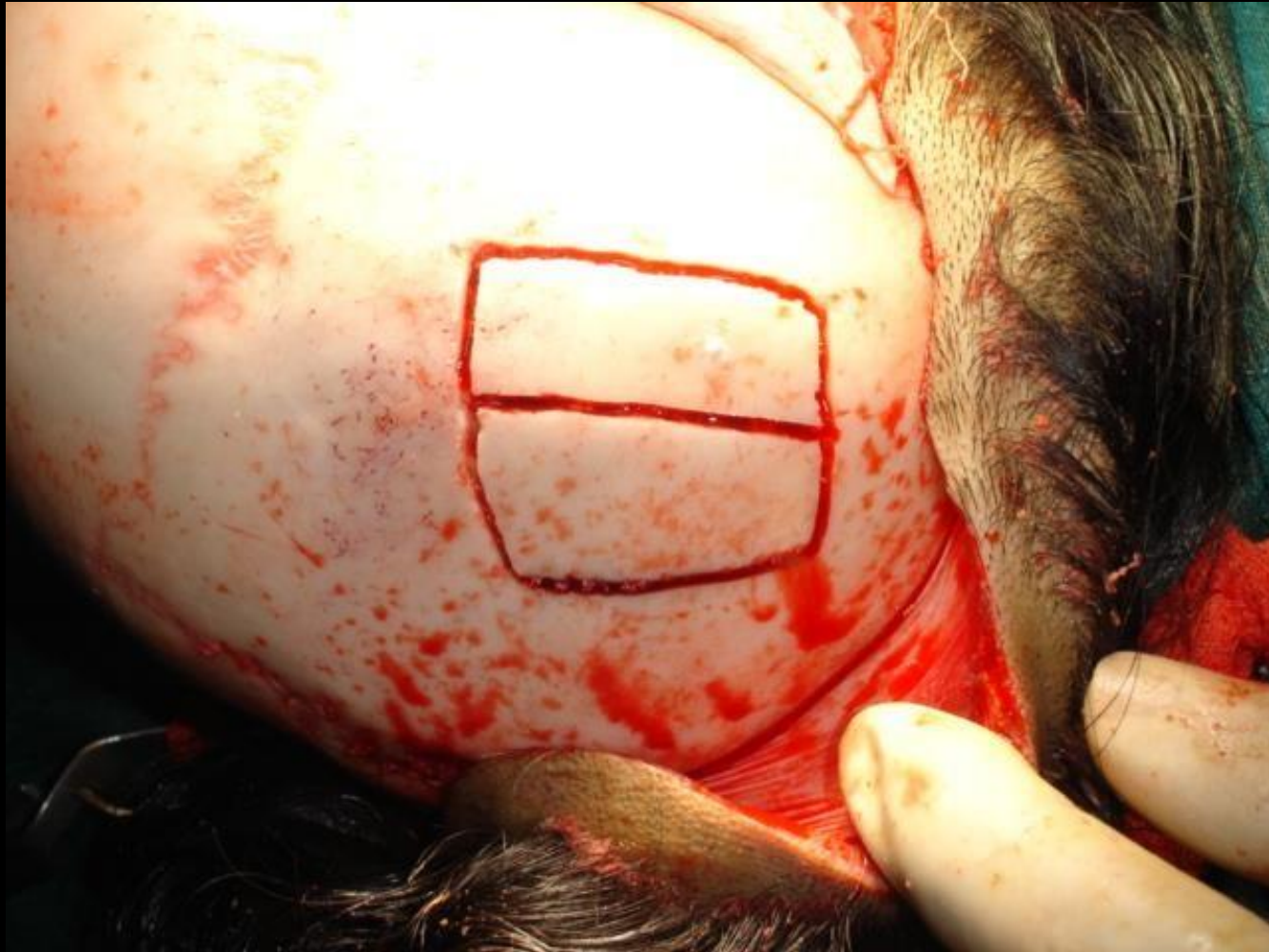Performing a LeFort III Osteotomy

The osteotomy ends on the dorsum of the nose



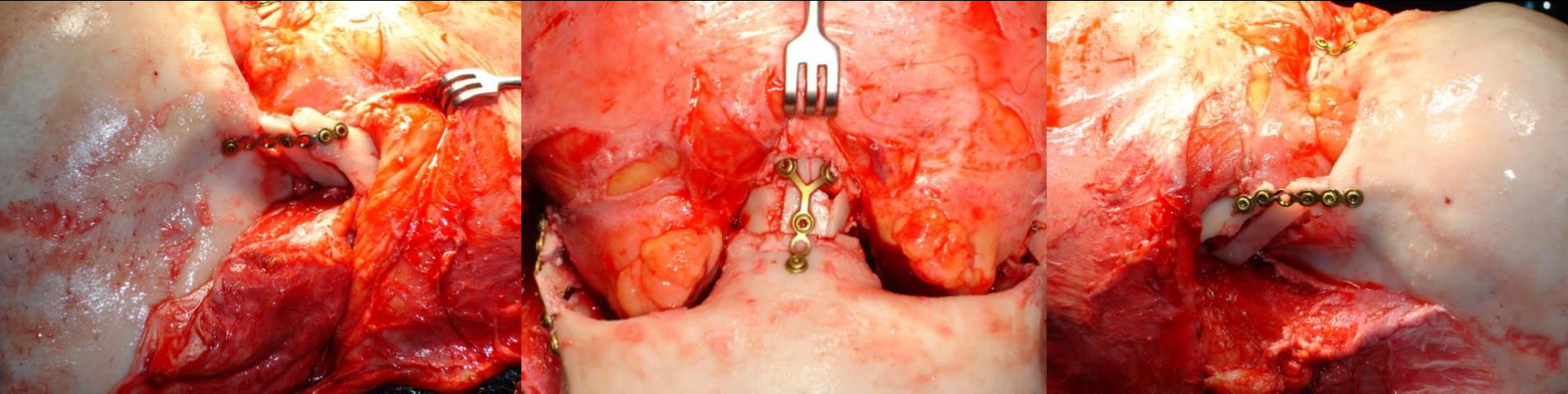
Performing a LeFort III Osteotomy

Calvarial bone graft is harvested



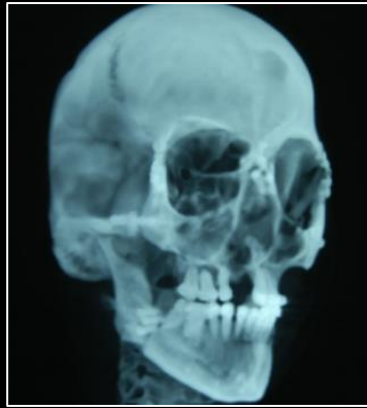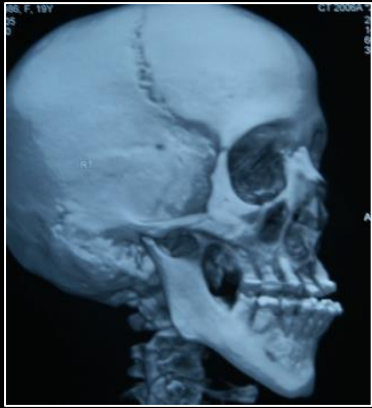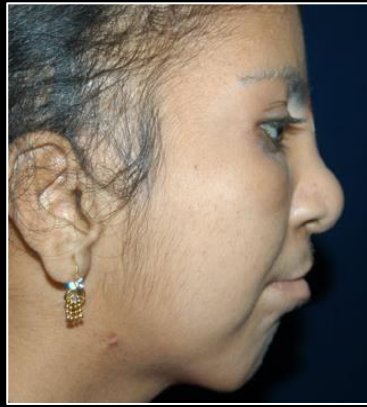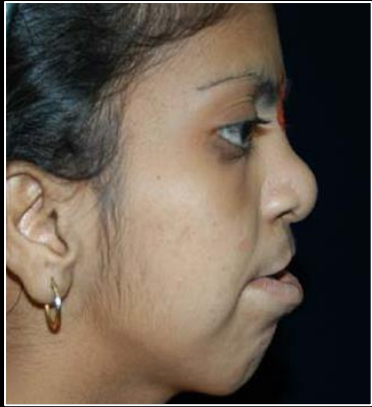Fixation after performing a LeFort III Osteotomy

Fixation is done with 1.5 mm low profile plates at the nasal and frontozygomatic areas with interposition of bone grafts



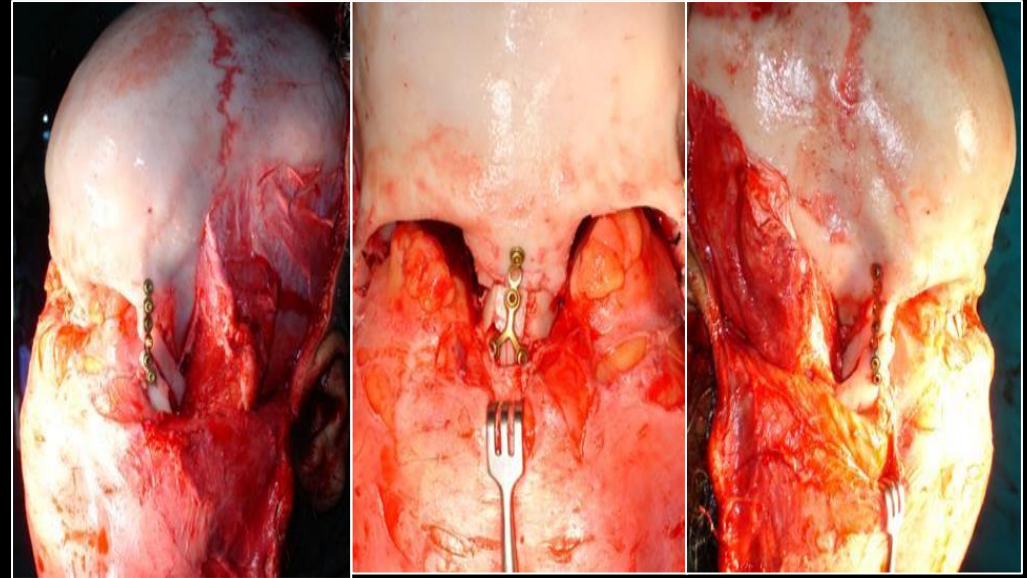
Lefort III Osteotomy + BSSO

Osteotomy at LeFort III level with calvarial bone graft for inter positioning and BSSO



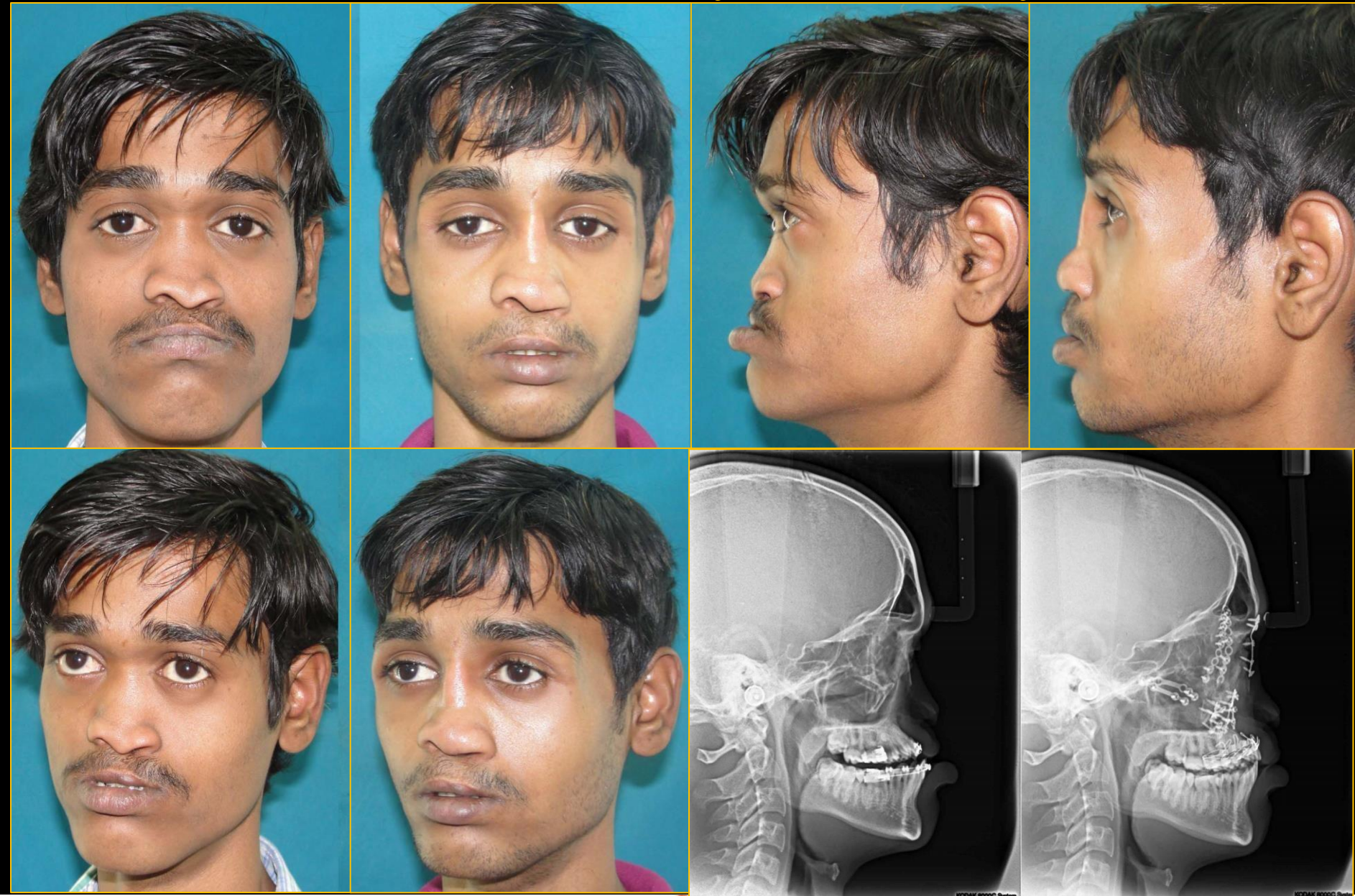Pre op

1year post op

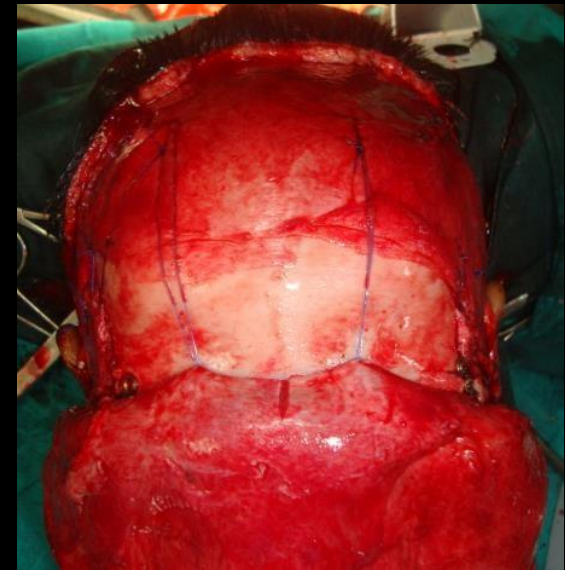
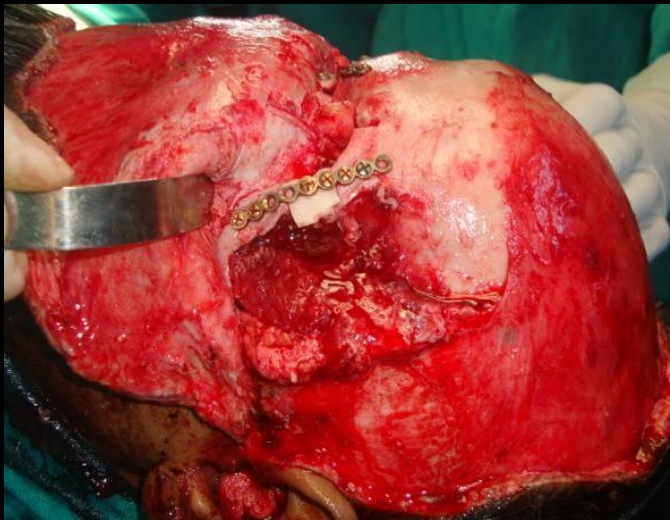
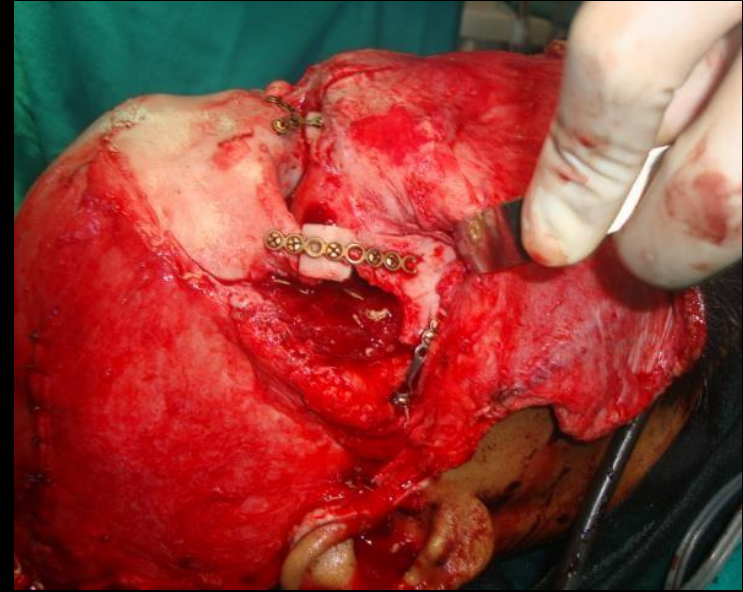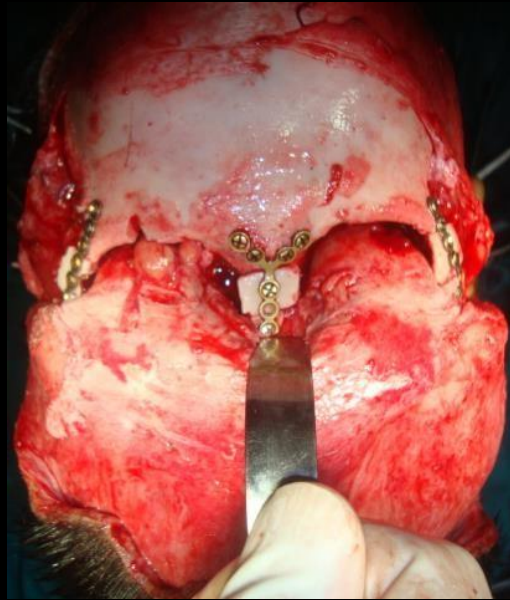

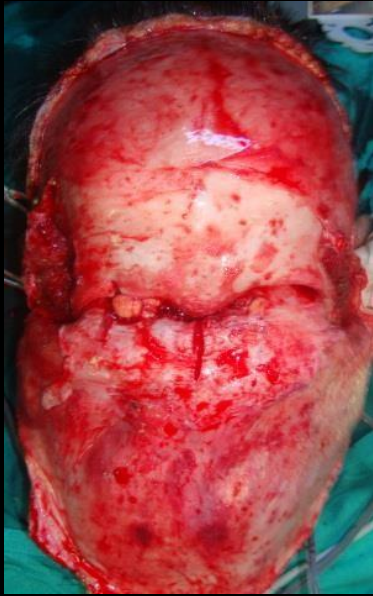
Osteotomy cuts at LeFort III level with calvarial bone graft for inter positioning

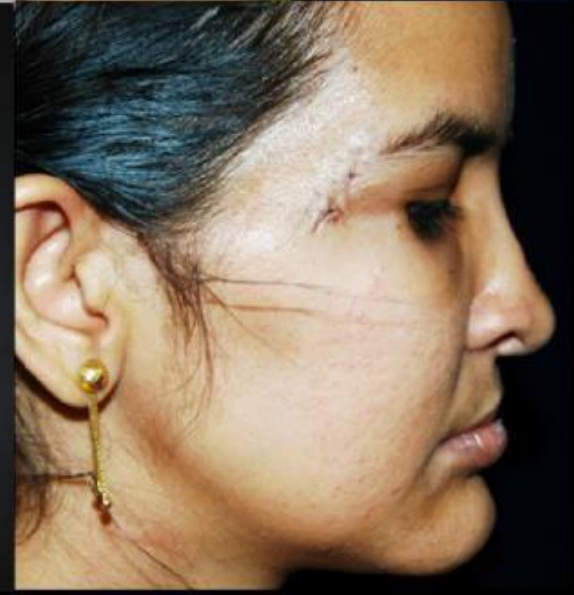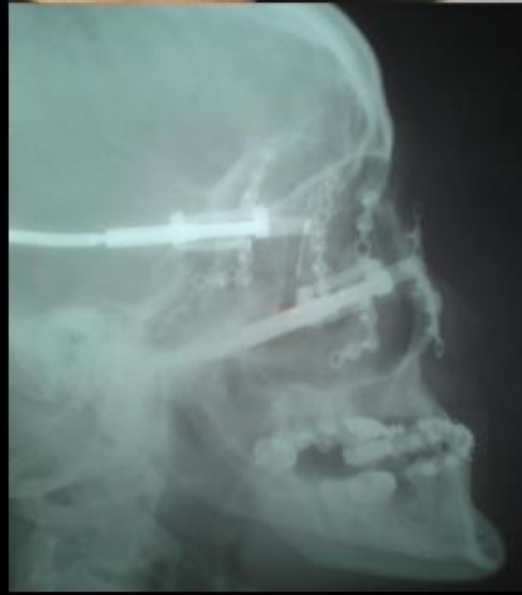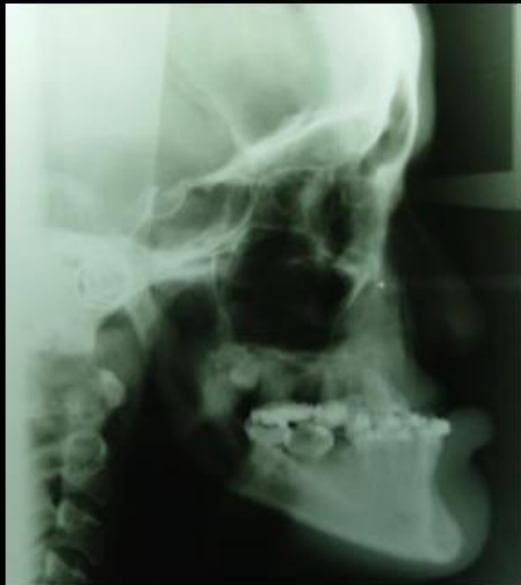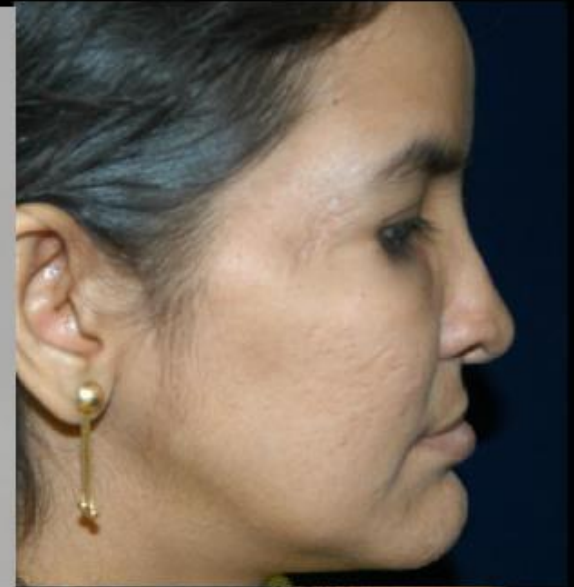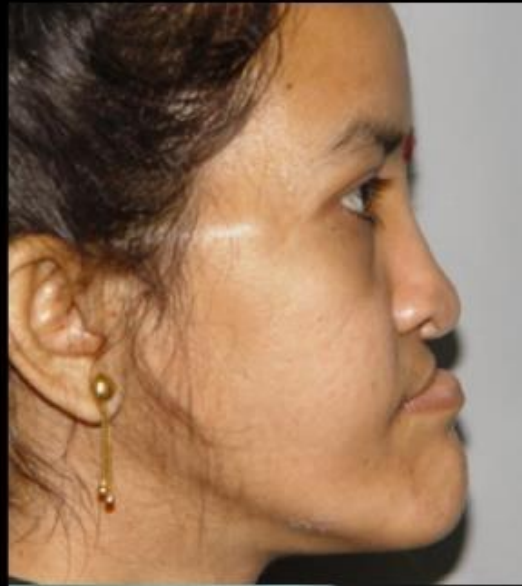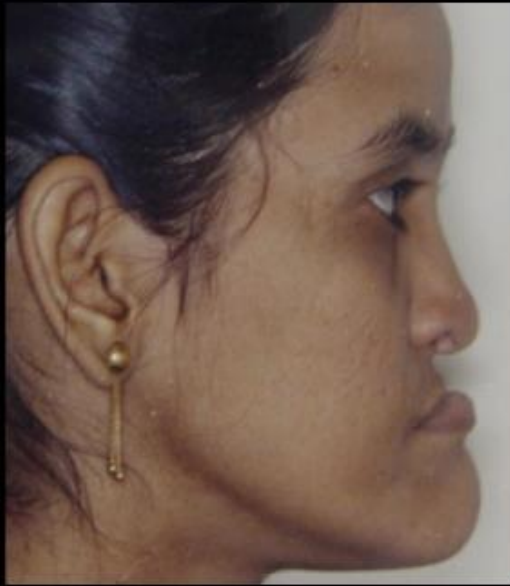LeFort I+III Osteotomy (Binders Syndrome)



LeFort I+III Osteotomy (Binders Syndrome)



LEFORT III DISTRACTION



Facial Bipartition and Monobloc Osteotomy

Why?

- To correct midface deformities caused by
 - craniosynostosis syndromes
 - frontonasal dysplasias
 - cranioorbital clefting

What?

Monobloc

- advancing orbit and midface as one unit
- **Fernando Ortiz-Monasterio**

Facial Bi-partition

- splitting the monobloc osteotomy in the midline to remove nasal and ethmoid bones and medializing the naso-orbital complex.
- **Van der Muelen**

Courtesy :

Kademani D, Tiwana P. Atlas of Oral and Maxillofacial Surgery , Elsevier Health Sciences - US; 1 edition. 2015



Facial Bipartition and Monobloc Osteotomy

How?

Facial Bipartition

Indications

- To increase antero-posterior dimension of the cranial complex

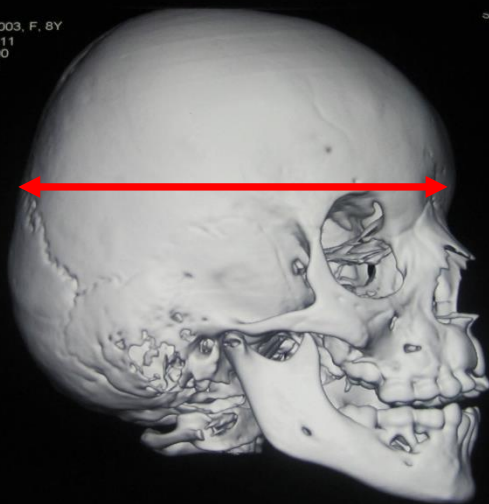
While also

- Correcting hypertelorism and
- Flattening the maxilla

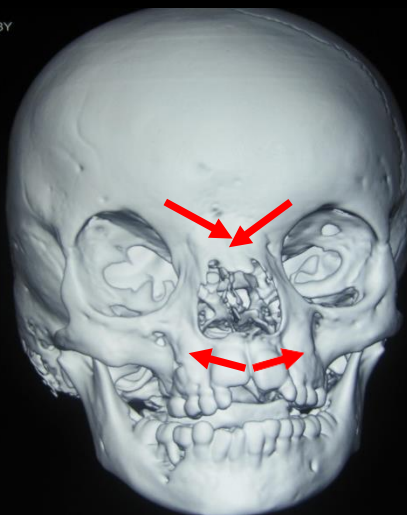




05-2003, F, 8Y
w-2011
40.00
1A 3

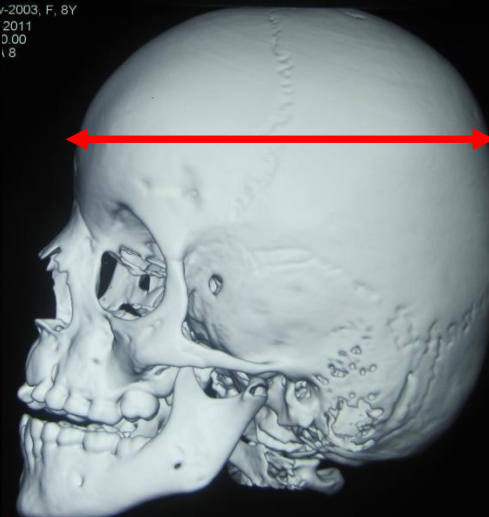


05-2003
CT 8Y



05-2003

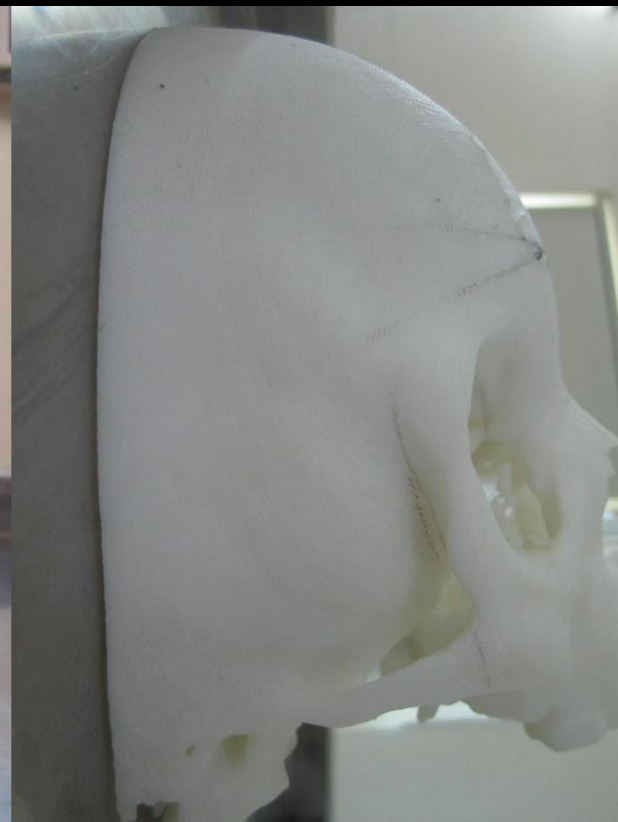
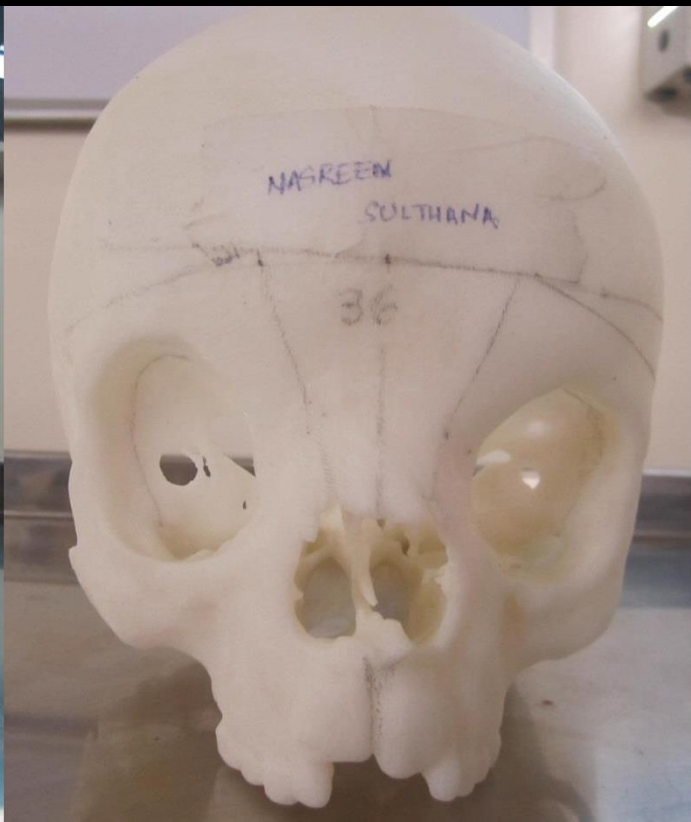05-2003, F, 8Y
2011
0.00
1B



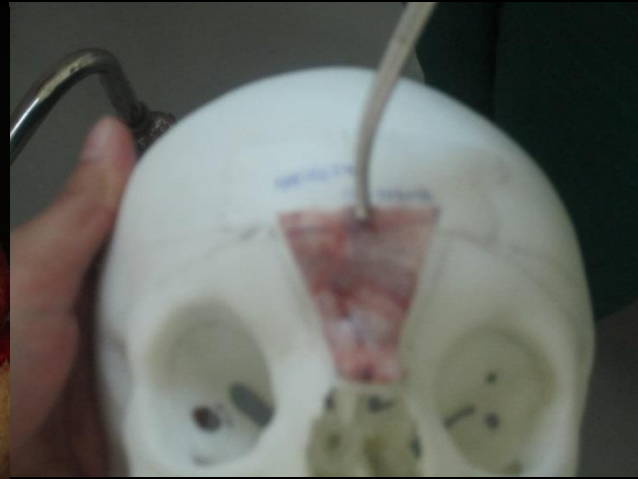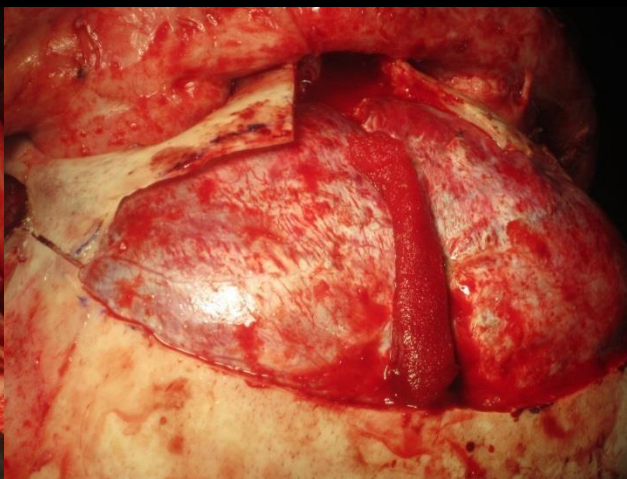
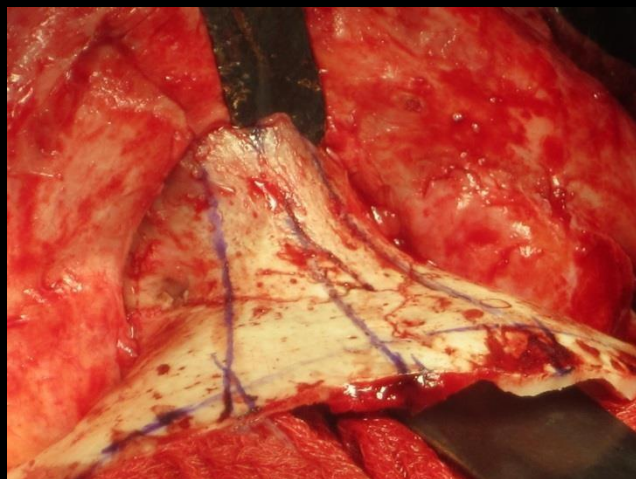
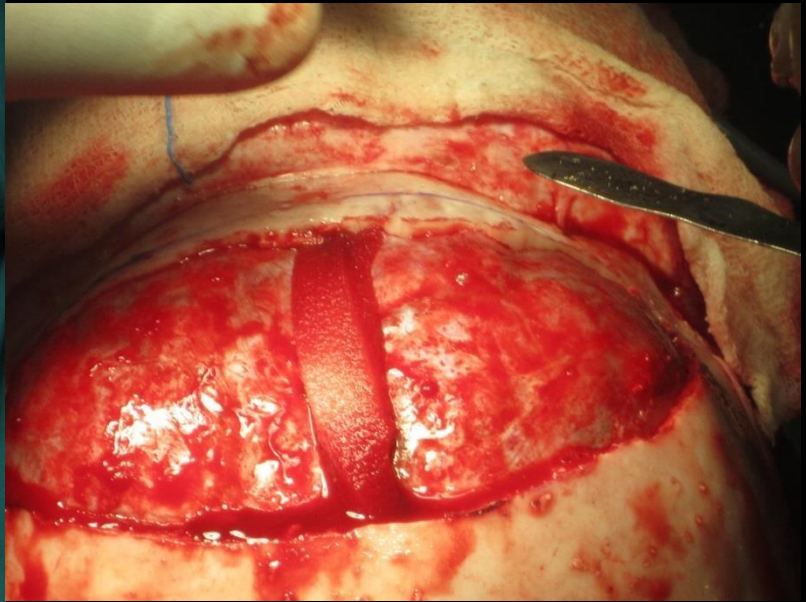
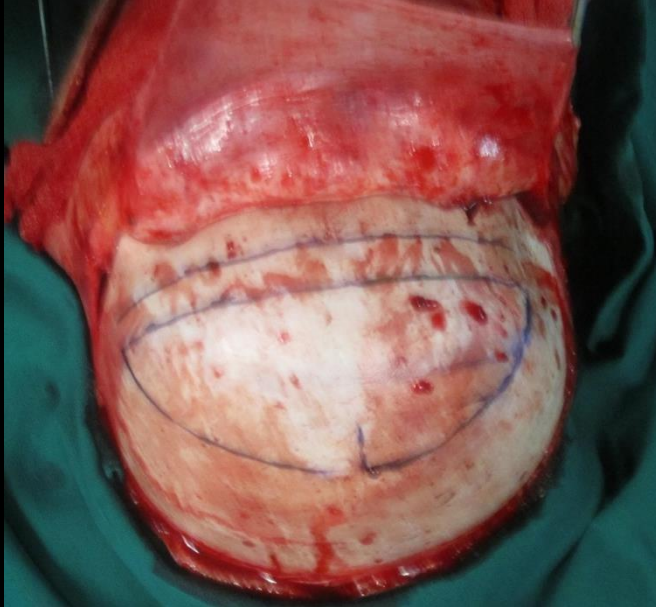
CT 21

FC

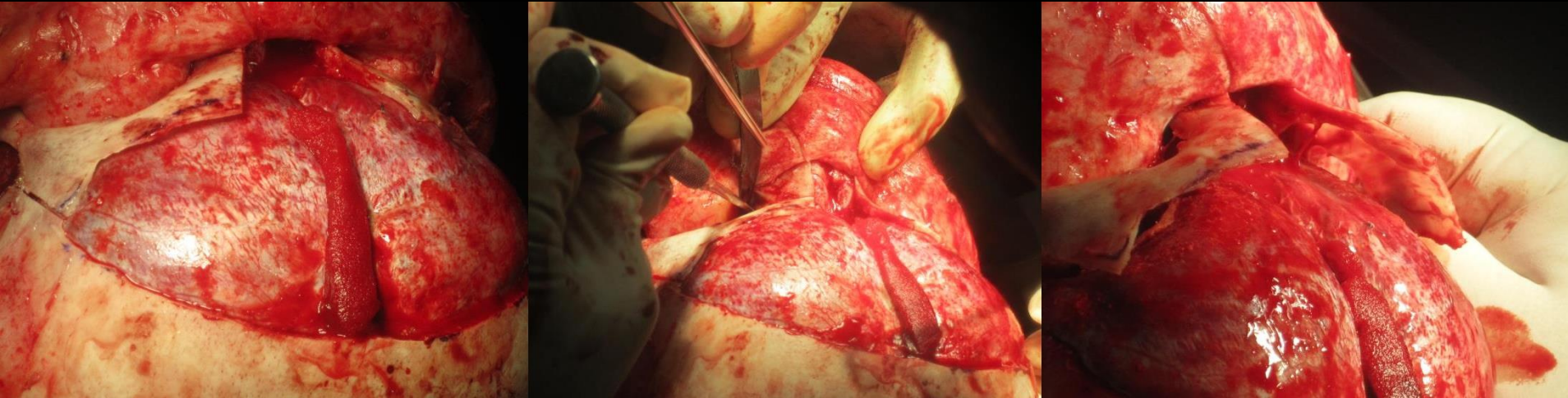




Frontal and medial craniotomy



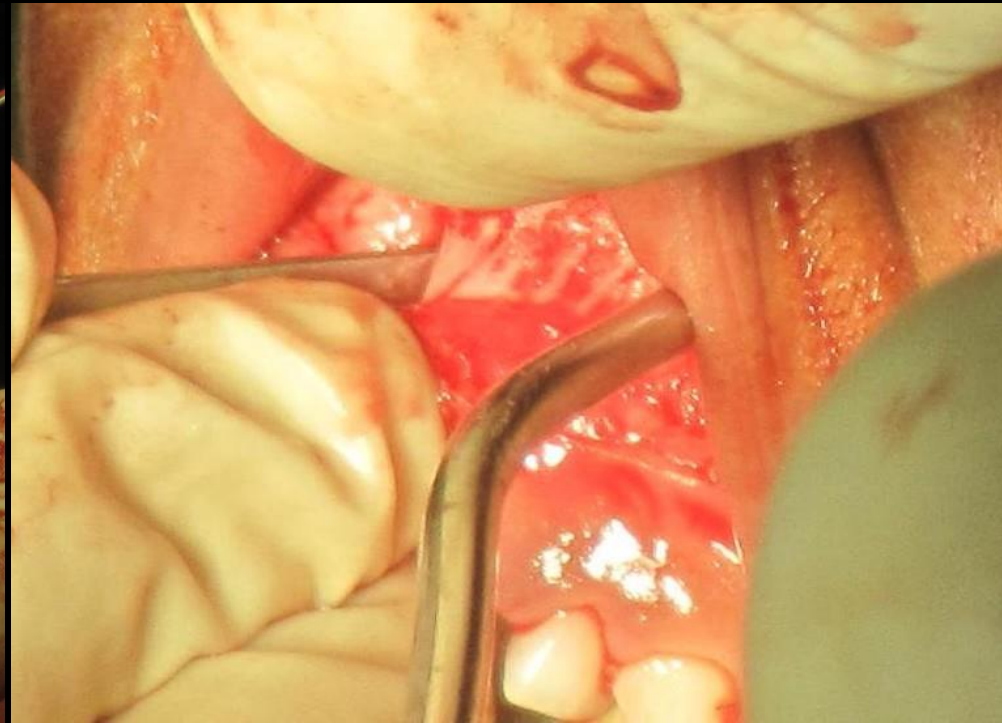
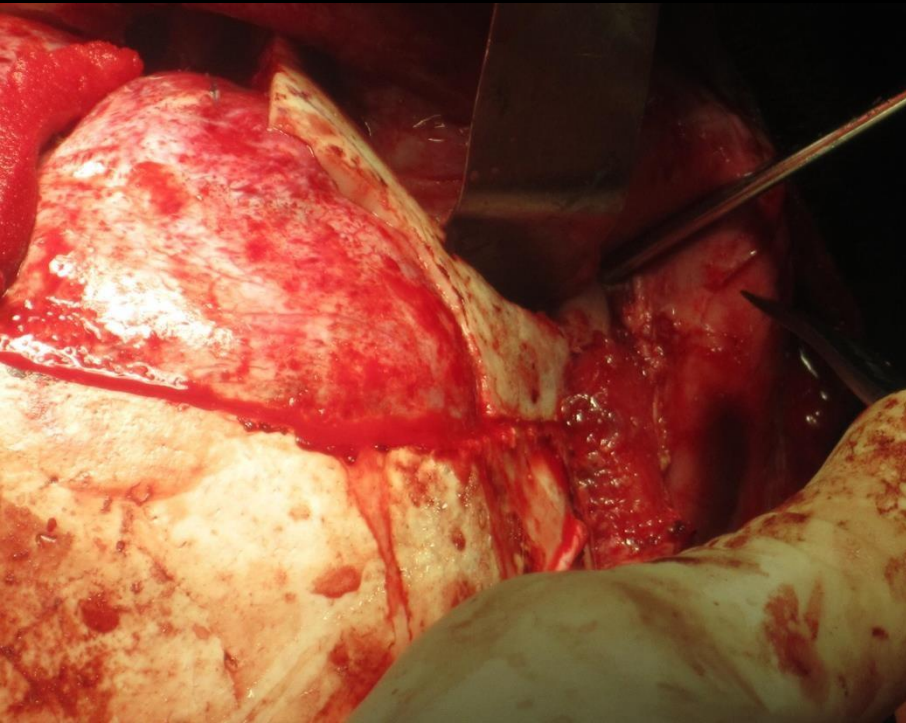
Lateral, Medial and Superior orbital osteotomies



- These osteotomies are done to separate the naso-orbital complex from the temporal and sphenoid bones and also the skull base
- Osteotomy is also done at the zygomatic bone.



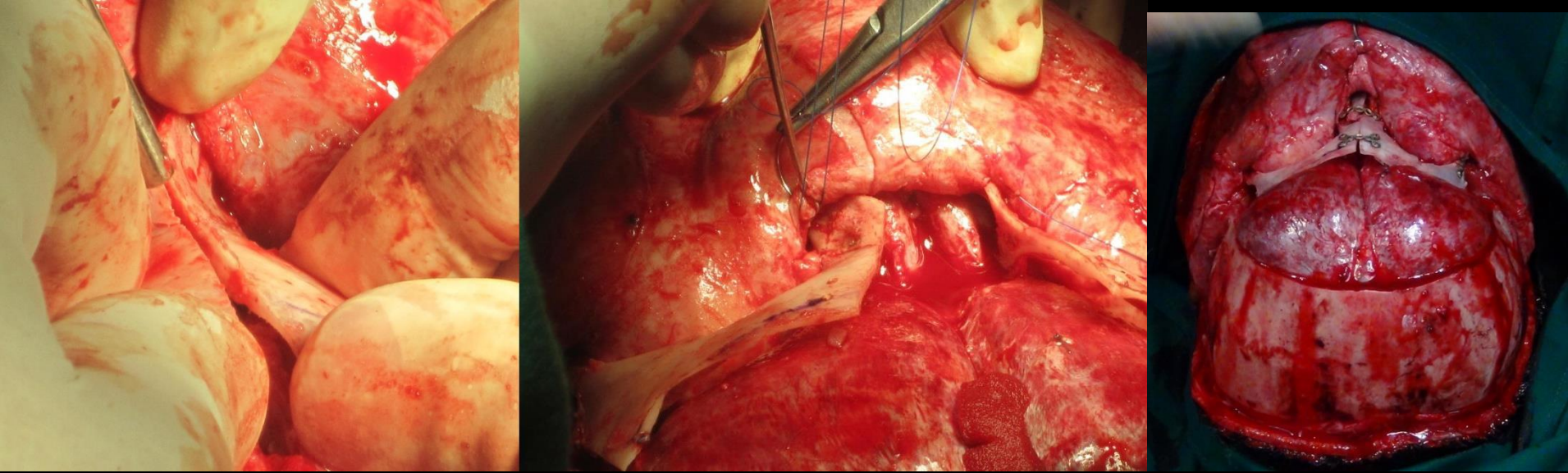
Pterygo-maxillary and mid palatine osteotomies



- Pterygo-maxillary osteotomy done to separate the zygomatico-maxillary complex from the pterygoid bone.
- **Mid-palatine osteotomy is done to flatten the maxilla.**

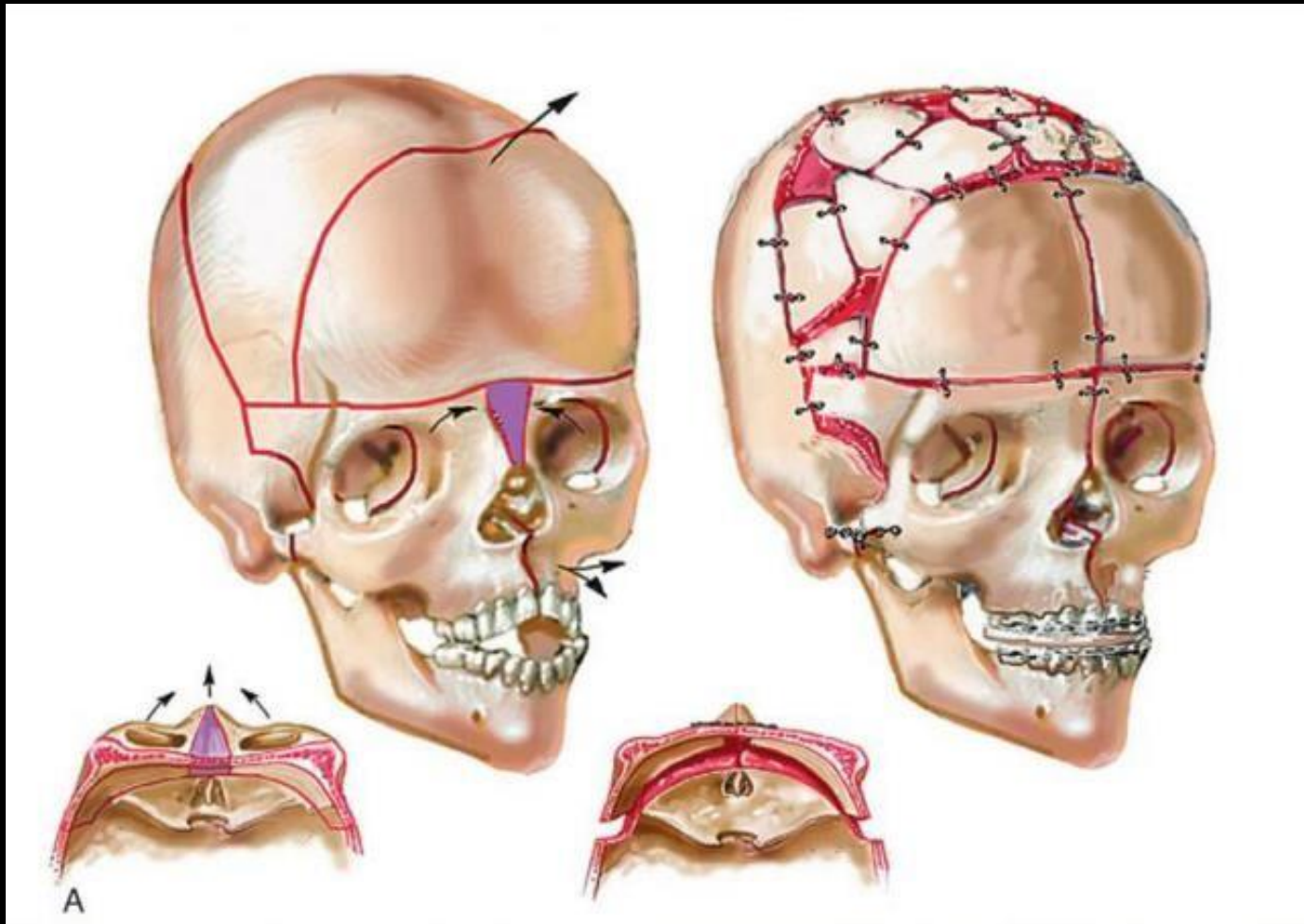


Approximation and fixation



- If the osteotomies are complete the segments will medialise with finger pressure
- Medial and lateral canthal ligaments are resuspended
- Fixation is done





Courtesy :
Kademani D, Tiwana P. Atlas of Oral and Maxillofacial Surgery , Elsevier Health Sciences - US;
1 edition. 2015



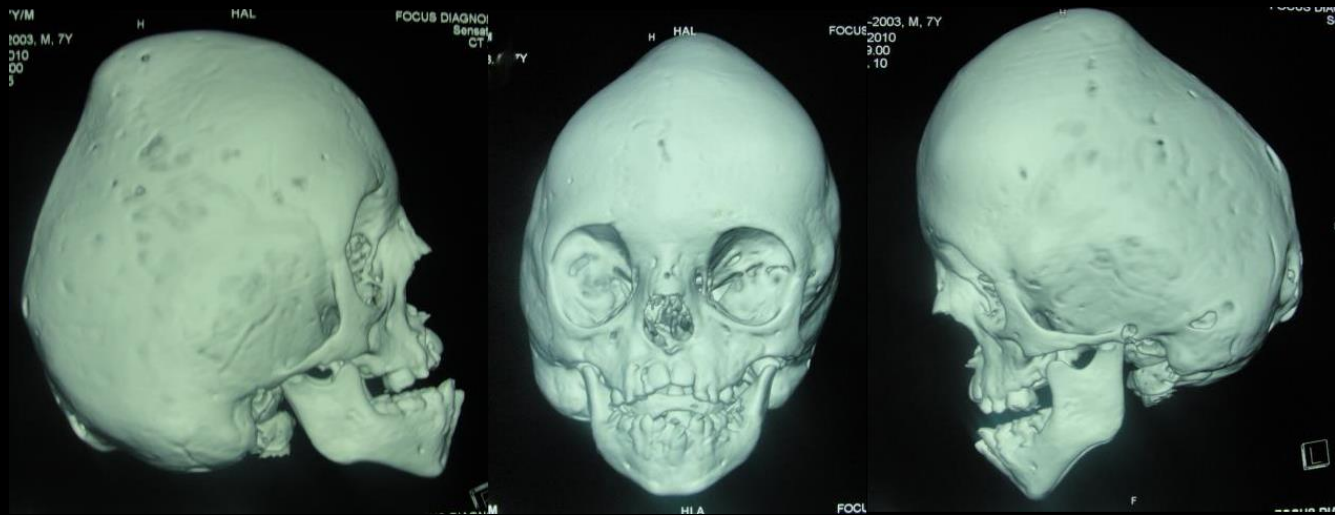
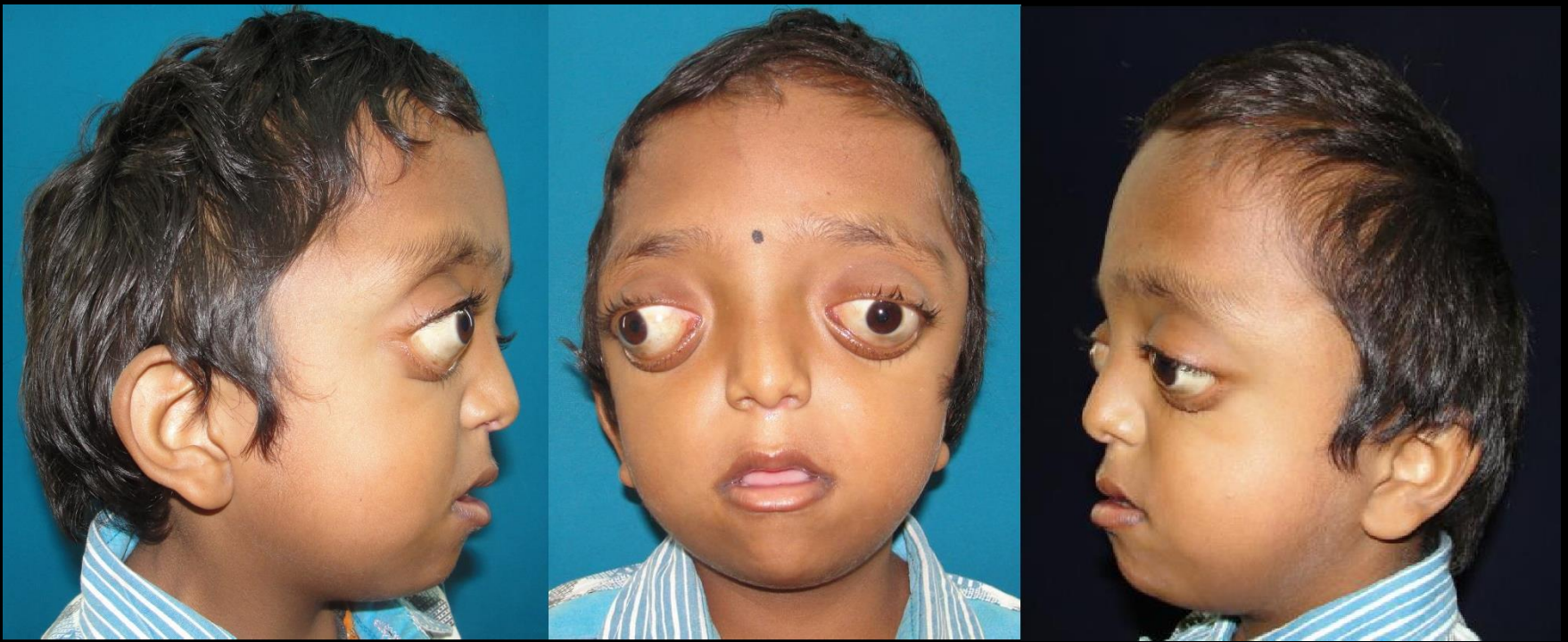www.craniofacialinstitute.org

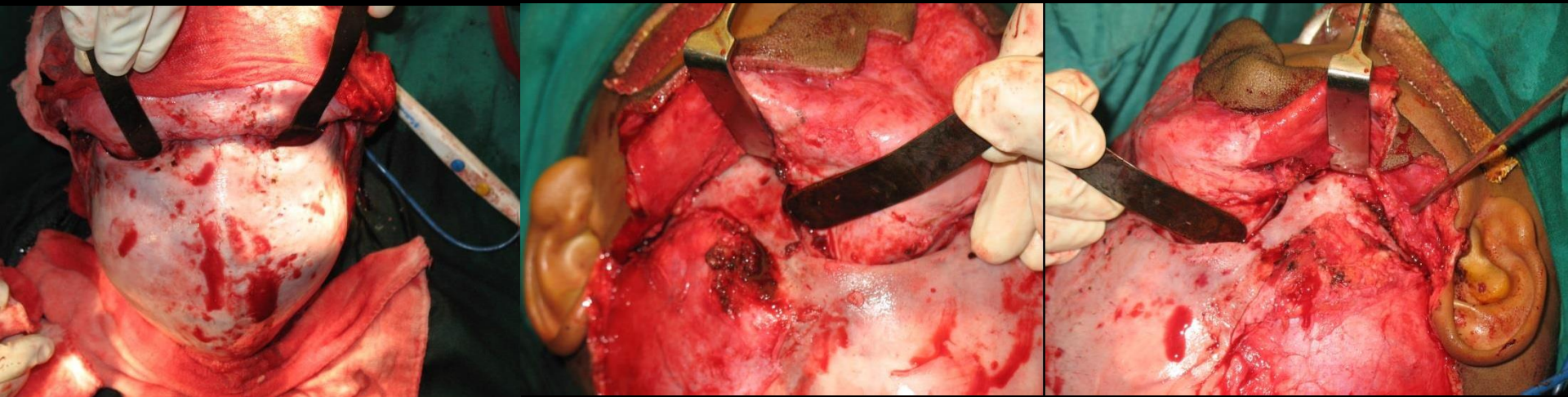
Monobloc

Indications

- To increase antero-posterior dimension of the cranio-maxillary complex

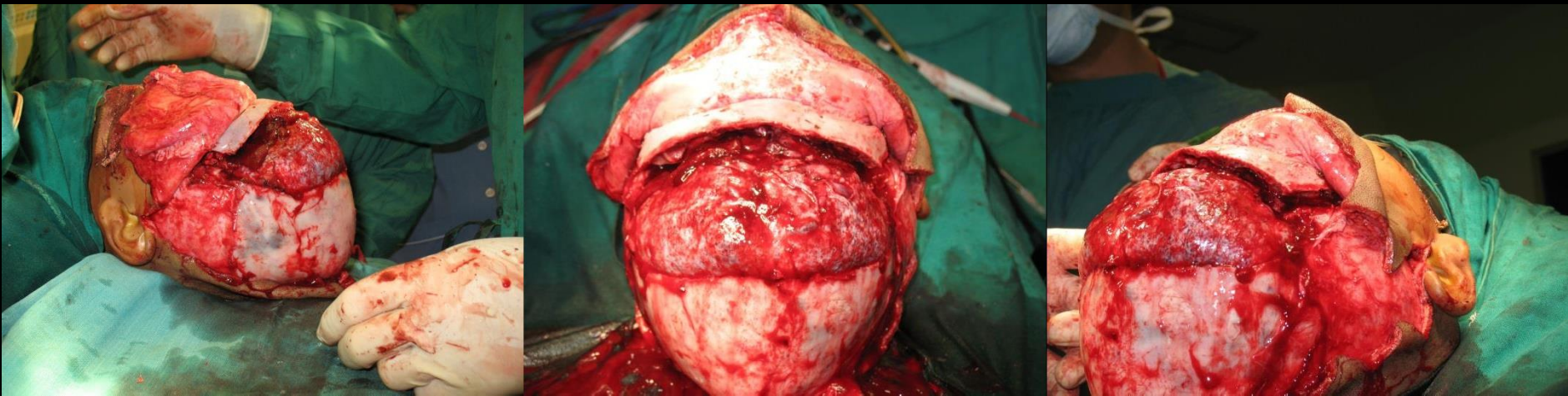






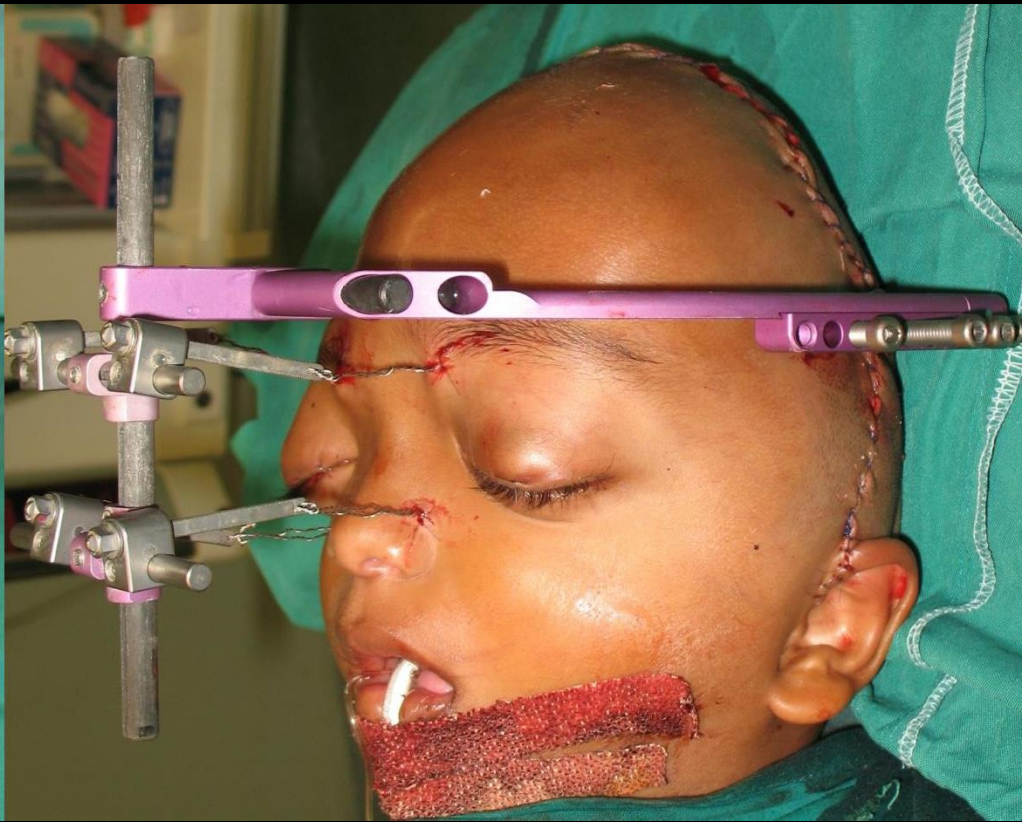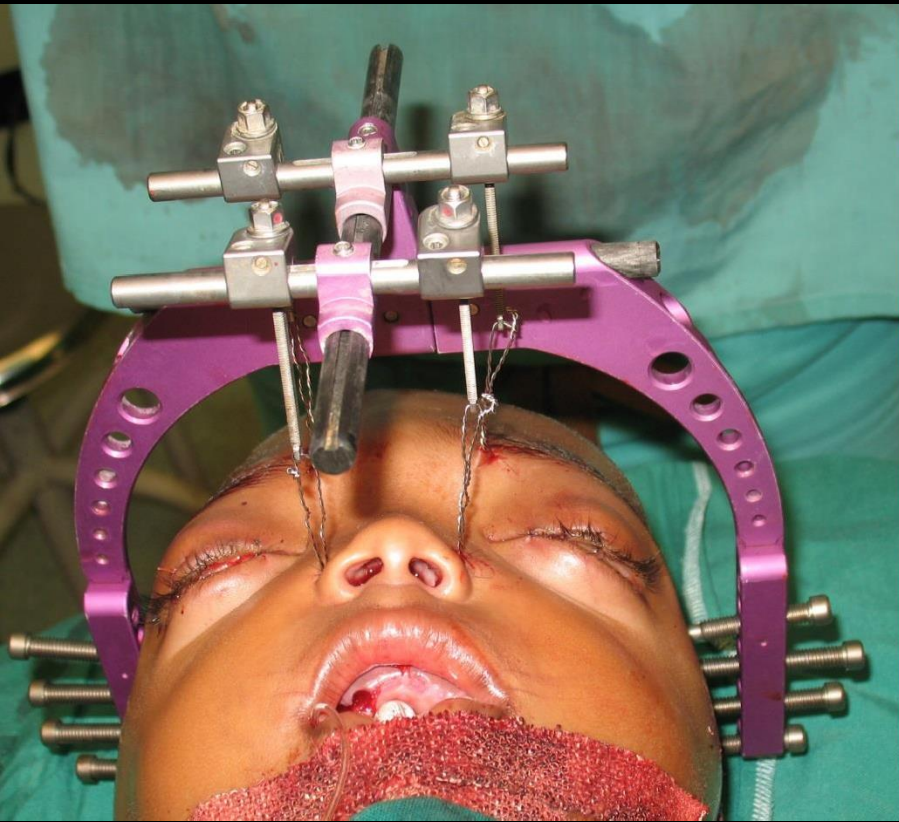- The exposure the same as that is done for facial bipartition





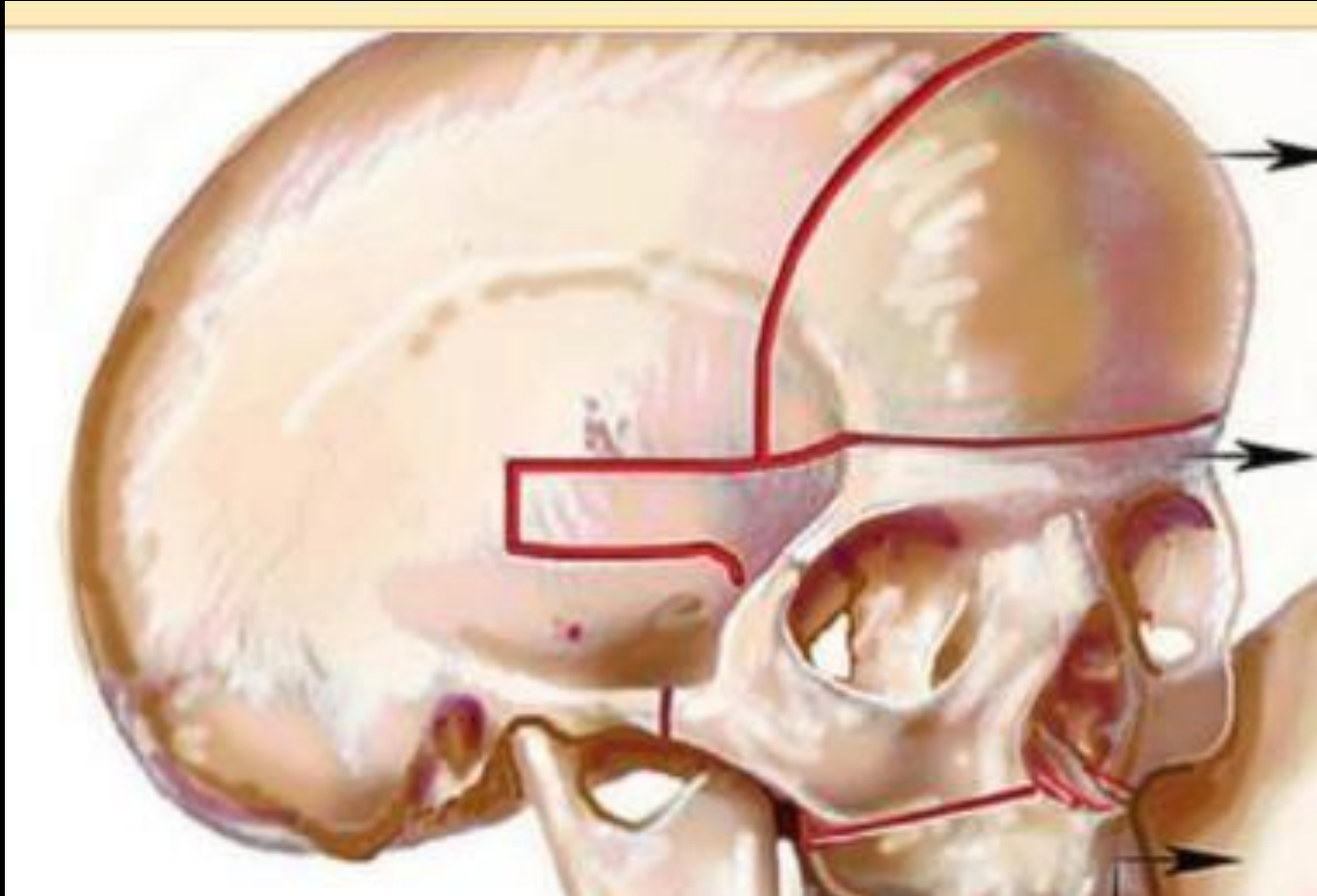- The lateral osteotomies are same as those done for facial bipartition.
- No medial cuts are given ensuring that the osteotomised complex is moved antero-posteriorly as a single block





- Distractor in place
- Distraction was preferred because of the amount of movement required, the dead space the movement would have resulted in and poor quality of bone already present.

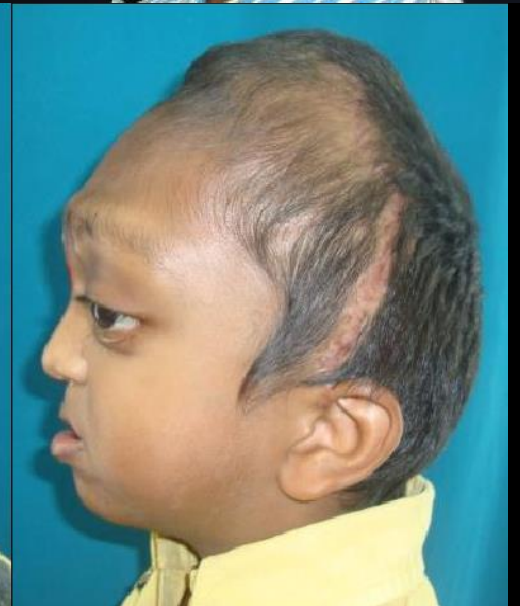
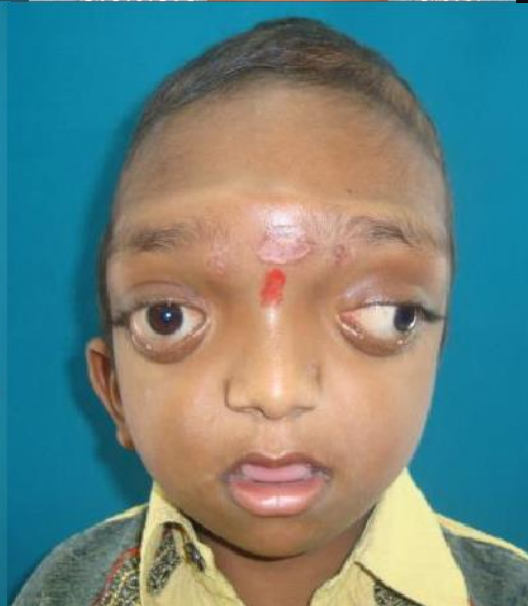
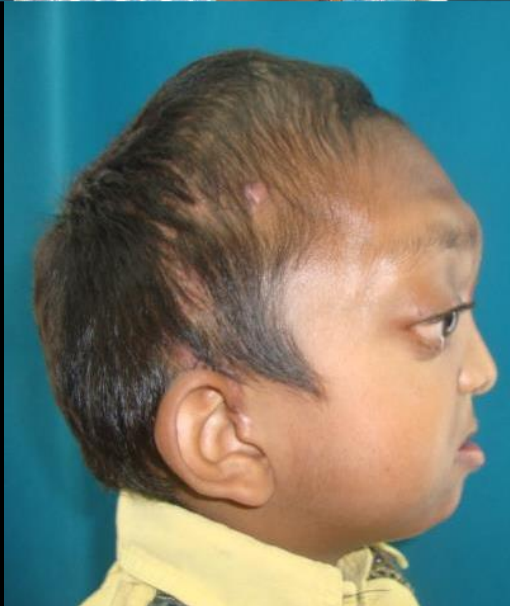
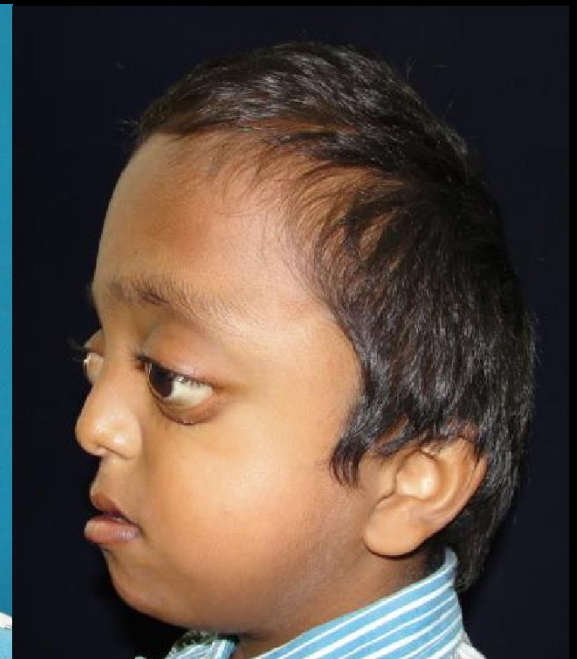
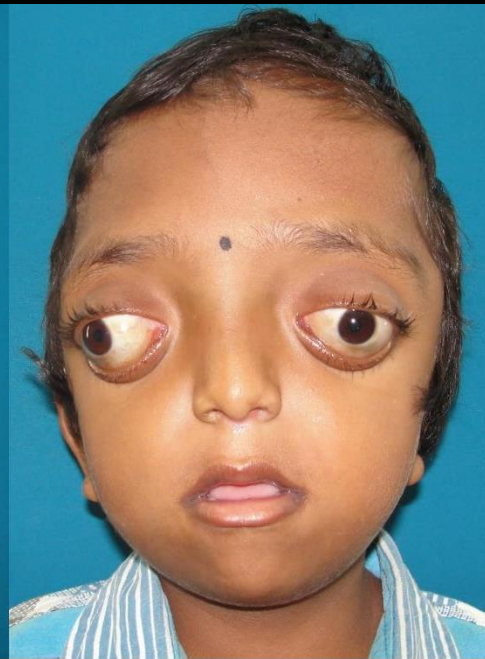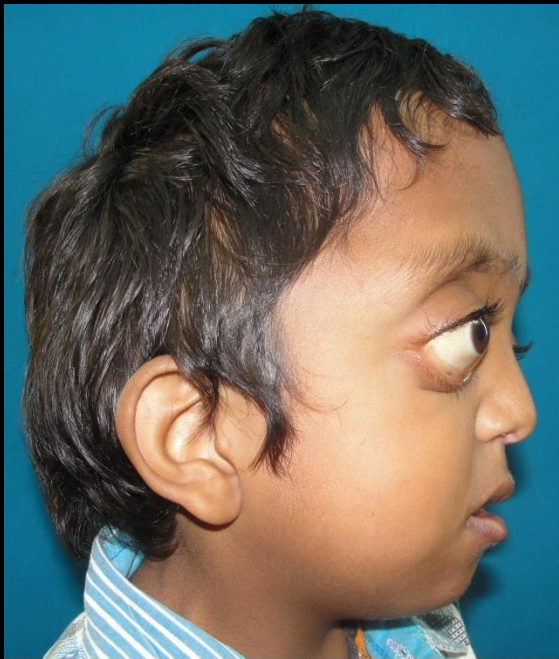Courtesy :
Kademani D, Tiwana P. Atlas of Oral and Maxillofacial Surgery , Elsevier Health Sciences - US;
1 edition. 2015



www.craniofacialinstitute.org



Review Article

Comparison of conventional Le-fort I advancement, anterior maxillary segmental distraction, and distraction osteogenesis of maxilla for surgical management of cleft maxillary hypoplasia: A systematic review

Taher Abbas Mistry, Abbas Mistry¹

ABSTRACT

This systematic review compares conventional Le-fort I advancement (CLO), anterior maxillary segmental distraction (AMD) and distraction osteogenesis of maxilla (DOM) for the treatment of cleft maxillary hypoplasia in terms of the amount of maxillary advancement achievable, relapse, residual velopharyngeal incompetence and soft tissue changes. All patients with maxillary hypoplasia secondary to cleft palate repair were taken into consideration irrespective of their gender, age and ethnic background. Literature research was done in databases PubMed, Ovid and Google scholar beta. From the original 429 articles identified, 17 articles were finally included, which passed the critical appraisal checklist and met the inclusion criteria. The mean advancement ranged from 6.59 mm to 16.5 mm for DOM, 6–14.28 mm for AMD and 5.17–7.2 mm for CLO. Relapse was 8.24%–45% for DOM, 4.6%–7% for AMD and 21.63%–63% for CLO. Velopharyngeal insufficiency increased significantly following Le-fort I advancement, while there was no significant change after anterior maxillary distraction and DOM. The ratio of soft tissue to hard tissue changes was greatest with AMD, followed by DOM and then CLO. Distraction osteogenesis of the maxilla and AMD are plausible treatment options for cleft maxillary advancement. Due to less stability and restricted amount of possible advancement, Le-fort I osteotomy should be reserved for minor skeletal discrepancies in cleft patients.

Key words: Anterior maxillary distraction, cleft orthognathic surgery, distraction osteogenesis, Le-fort I advancement

Departments of Maxillofacial Surgery, and ¹Plastic and Reconstructive Surgery, Saifee Hospital, Mumbai, Maharashtra, India

Address for correspondence:

Dr. Taher Abbas Mistry,
Saifee Hospital, Mumbai, Maharashtra, India.
E-mail: tahermistry05@gmail.com

Access this article online

Website:
www.jclpca.org

DOI:
10.4103/jclpca.jclpca_28_20

Quick Response Code:



INTRODUCTION

Cleft palate surgery results in inhibition of forward translation of the maxilla during growth, shortening of the basal length, and retrusion of the alveolar process. It is estimated that >45% of treated cleft palate patients have moderate-to-severe maxillary hypoplasia.^[1]

Conventional Le-fort I advancement for treating cleft maxillary hypoplasia has been reported by numerous authors with varying degrees of success. The relapse rate of conventional Le-fort I advancement in cleft patients is estimated to be around 25%–50% compared to 10% in noncleft individuals.^[2,3] The other reported complications include worsening of velopharyngeal insufficiency and inability to achieve the desired advancement due to tissue scarring resulting in compromised functional and esthetic results.

Distraction osteogenesis for maxillary advancement was introduced in 1993 and has been widely used for maxillary hypoplasia.^[4] Polley and Figueroa^[5] reported the use of rigid external device for maxillary advancement. The merits of distraction osteogenesis for the advancement of the maxilla is highlighted in cleft orthognathic due to its potential to minimize the limitations of conventional

This is an open access journal, and articles are distributed under the terms of the Creative Commons Attribution-NonCommercial-ShareAlike 4.0 License, which allows others to remix, tweak, and build upon the work non-commercially, as long as appropriate credit is given and the new creations are licensed under the identical terms.

For reprints contact: WJH-ILRP@medknow_reprints@wolterskluwer.com

Cite this article as: Mistry TA, Mistry A. Comparison of conventional Le-fort I advancement, anterior maxillary segmental distraction, and distraction osteogenesis of maxilla for surgical management of cleft maxillary hypoplasia: A systematic review. *J Cleft Lip Palate Craniofac Anomal* 2021;8:49-55.

Submission: 16.09.2020 **Revision:** 24.09.2020

Acceptance: 20.11.2020 **Web Publication:** 13.01.2021

CONCLUSION:

In managing cleft maxillary hypoplasia, it is extremely crucial to select the surgical procedure for advancement of the maxilla. We can evidently conclude that conventional Le-fort I advancement should be reserved for mild cases, i.e., ≤8 mm.

AMD should be preferred in moderate cases of <10 mm. A requisite for AMD using palatal distractor is that it should be firmly supported by the posterior teeth, and the vector should be favorable for distraction.

Distraction osteogenesis is to be used for discrepancies requiring >10 mm advancement or in cases where clockwise movement is desired.

Relapse is considerably higher in these cases; hence, over correction of the defect should be considered



Int. J. Oral Maxillofac. Surg. 2019; xxx: xxx-xxx
<https://doi.org/10.1016/j.ijom.2019.08.012>, available online at <https://www.sciencedirect.com>

International Journal of
**Oral &
 Maxillofacial
 Surgery**

Meta-Analysis Cleft Lip and Palate

Relapse rate after surgical treatment of maxillary hypoplasia in non-growing cleft patients: a systematic review and meta-analysis

L. Jiang^{1,*}, Y. Zheng^{1,*}, N. Li²,
 X. Chen¹, Z. Lu², H. Tong¹,
 N. Yin¹, T. Song¹

¹Department of Cleft Lip and Palate, Plastic Surgery Hospital, Chinese Academy of Medical Sciences and Peking Union Medical College, Beijing, China; ²National Office for Cancer Prevention and Control, Cancer Institute and Hospital, Chinese Academy of Medical Sciences, Beijing, China

L. Jiang, Y. Zheng, N. Li, X. Chen, Z. Lu, H. Tong, N. Yin, T. Song: Relapse rate after surgical treatment of maxillary hypoplasia in non-growing cleft patients: a systematic review and meta-analysis. *Int. J. Oral Maxillofac. Surg.* 2019; xxx: xxx-xxx. © 2019 The Authors. Published by Elsevier Ltd on behalf of International Association of Oral and Maxillofacial Surgeons. This is an open access article under the CC BY-NC-ND license (<http://creativecommons.org/licenses/by-nc-nd/4.0/>).

Abstract. Maxillary hypoplasia in cleft lip and palate is a complex deformity. Despite surgical improvements, postoperative relapse persists. This systematic review was performed to determine the mean horizontal relapse rates for the surgical techniques used to treat maxillary hypoplasia: Le Fort I osteotomy with rigid fixation, Le Fort I distraction osteogenesis, and anterior maxillary distraction osteogenesis. This study followed the PRISMA statement. The PubMed, Embase, Science Direct, and Web of Science databases were searched through to June 2018. Studies on non-growing cleft lip and palate patients who had undergone one of the three surgical procedures and who had postoperative horizontal maxillary changes assessed at >6 months post-surgery were included. Stata SE was used to estimate pooled means, heterogeneity, and publication bias. The search strategy identified 326 citations, from which 24 studies were selected. Relapse rates following Le Fort I osteotomy with rigid fixation, Le Fort I distraction osteogenesis, and anterior maxillary distraction osteogenesis were 20%, 12%, and 12%, respectively. Relapse rates with and without bone grafting were 19% and 66%, respectively. The relapse rate following distraction osteogenesis with internal distraction was lower than that with external distraction. Study limitations were heterogeneity, which was above moderate, the low number of high-quality studies, and unidirectional assessment of postoperative maxillary movement.

Key words: relapse rate; maxillary hypoplasia; orthognathic surgery; cleft patients meta-analysis.

Accepted for publication

CONCLUSION: The relapse rate following distraction osteogenesis with internal distraction was lower than that with external distraction.

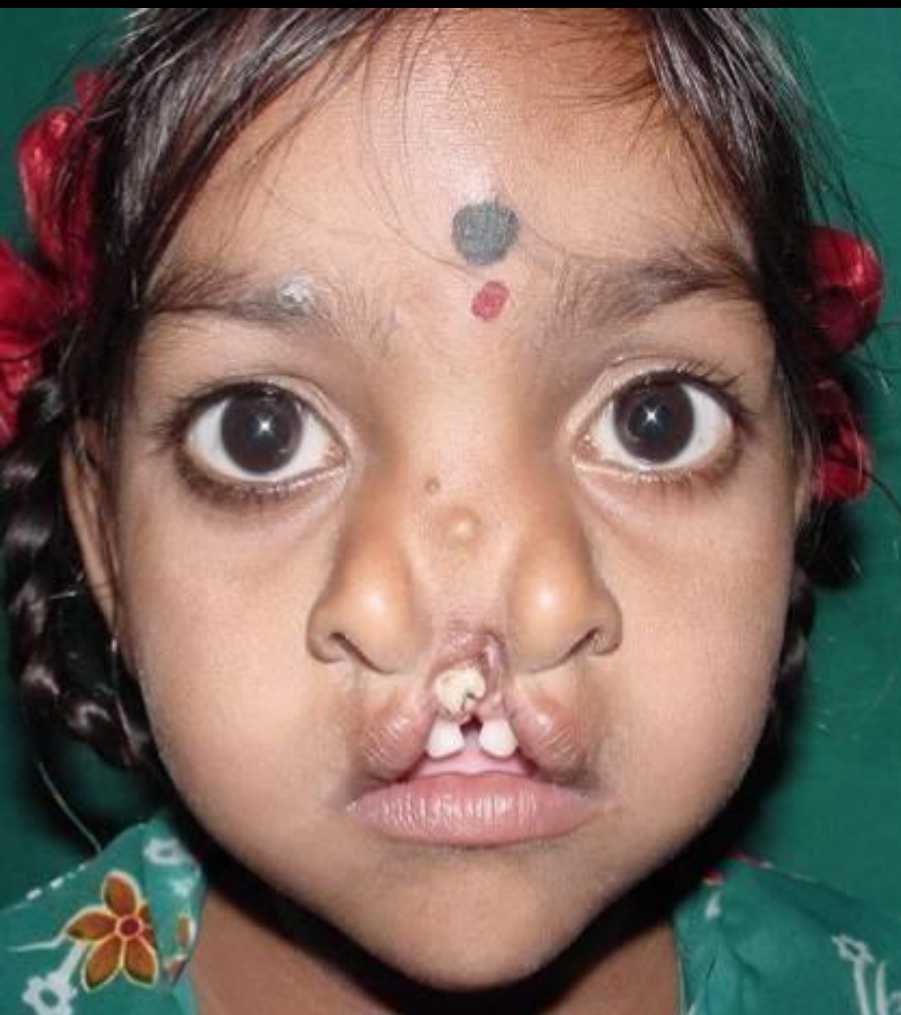

SUMMARY....

To decide on the treatment modality depends on :

1. Surgeon's Choice.
2. Indication of the deformity.
3. Availability of the resources.





Bring the Smile Back



www.craniofacialinstitute.org